



**The Students' Quiz Series.**

**DISEASES**

OF THE

**EYE, EAR, THROAT, AND NOSE.**

A MANUAL FOR STUDENTS AND PRACTITIONERS.

BY

**FRANK E. MILLER, M. D.,**

*Attending Physician, St. Joseph's Hospital; Throat Surgeon,  
Vanderbilt Clinic, New York,*

**JAMES P. McEVROY, M. D.,**

*Throat Surgeon, Bellevue Hospital, Out-Patient Department, New York,*

AND

**JOHN E. WEEKS, M. D.,**

*Surgeon, New York Eye and Ear Infirmary; Lecturer on Ophthalmology and  
Otology, Bellevue Hospital Medical College, New York.*

---

SERIES EDITED BY

**BERN B. GALLAUDET, M. D.,**

*Demonstrator of Anatomy, College of Physicians and Surgeons, New York; Visiting  
Surgeon Bellevue Hospital, New York.*



PHILADELPHIA:

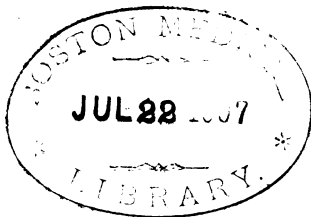
LEA BROTHERS & CO.

1150

---

Entered according to Act of Congress, in the year 1892, by  
LEA BROTHERS & CO.,  
In the Office of the Librarian of Congress, at Washington. All rights reserved.

---



---

WESTCOTT & THOMSON,  
*Stereotypers and Electrotypers, Philada.*

---

WILLIAM J. DORNAN,  
*Printer, Philada.*

## PREFACE.

---

To facilitate the acquisition of a well assorted knowledge of diseases of the Eye, Ear, Throat, and Nose we have endeavored to condense into this volume in the most complete and concise manner possible the essentials of these specialties. To the student such brief volumes have a double usefulness, not only presenting the facts, but saving his attention to lectures from interruption by note-taking. It is also hoped that the volume will serve to refresh the memory of the busy practitioner, as it is in reality a trustworthy digest of the best and latest works on these specialties. Through the kind permission of ~~Dr.~~ George M. Lefferts, Clinical Professor of the Diseases of the Throat and Nose in the College of Physicians and Surgeons, we are able to place before our readers some of his admirably arranged charts for the study of nose and throat diseases. The credit for most of this work is due to my friends and co-workers, Drs. J. P. McEvoy and J. E. Weeks. The basis of the division on Diseases of the Eye is a course of lectures delivered by Dr. Weeks at the Bellevue Hospital Medical College of New York.

The following are the principal authorities consulted in the preparation of this book :

ON DISEASES OF THE EYE: Becker, Hutchinson, Juler, Knapp, Landolt, Mackenzie, Nettleship, Czermak.

ON DISEASES OF THE EAR: Buck, Burnett, Gruber, Greene, Politzer, Richards, Roosa.

ON DISEASES OF THE THROAT AND NOSE: Lennox-Browne, Bosworth, Delavan, Fraenkel, Gottstein, Knight, Krause, Lef-ferts, Mackenzie, Sajous, Seiler.

F. E. MILLER.

121 WEST THIRTY-FOURTH ST., }  
New York City.

# CONTENTS.

---

## THE EYE.

	PAGE
DISEASES OF THE LIDS . . . . .	17
DISEASES OF THE LACHRYMAL APPARATUS . . . . .	26
DISEASES OF THE CONJUNCTIVA . . . . .	33
DISEASES OF THE CORNEA . . . . .	44
DISEASES OF THE SCLEROTIC . . . . .	55
DISEASES OF THE IRIS, CILIARY BODY, AND CHOROID . . . . .	57
DISEASES OF THE RETINA . . . . .	71
DISEASES OF THE OPTIC NERVE . . . . .	76
DISEASES OF THE VISUAL FIELD: Color-blindness; Hemianopsia and its Varieties . . . . .	79
SYMPATHETIC OPHTHALMIA . . . . .	83
GLAUCOMA . . . . .	85
DISEASES OF THE LENS . . . . .	87
DISEASES OF THE VITREOUS HUMOR . . . . .	96
OPTICAL PRINCIPLES . . . . .	96
THE EYE AS AN OPTICAL INSTRUMENT . . . . .	102
THE OPHTHALMOSCOPE . . . . .	110
THE MUSCULAR APPARATUS . . . . .	113
DISEASES OF THE ORBIT . . . . .	121
REMEDIES AND FORMULÆ . . . . .	123

---

## THE EAR.

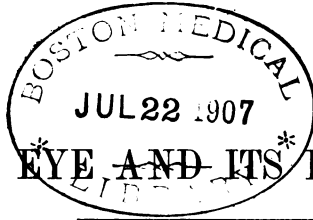
ANATOMY OF THE EAR . . . . .	127
EXAMINATION OF THE PATIENT . . . . .	132
DISEASES AND AFFECTIONS OF THE AURICLE . . . . .	137
DISEASES AND AFFECTIONS OF THE EXTERNAL AUDITORY CANAL . . . . .	138
DISEASES AND AFFECTIONS OF THE MIDDLE EAR OR TYMPANUM . . . . .	141
DISEASES AND AFFECTIONS OF THE INTERNAL EAR OR LABYRINTH . . . . .	156

## THE THROAT.

	PAGE
<b>THE PHARYNX:</b> Anatomy of the Pharynx, Palate, and Tonsils; Inflammations of the Pharynx; Syphilis of the Pharynx; Tuberculosis of the Pharynx; Neuroses of the Pharynx; Tumors of the Pharynx; Diseases of the Tonsil; Diseases of the Uvula; Adenoid Vegetations (Hypertrophy of the Pharyngeal Tonsil) . . . . .	159
<b>THE LARYNX:</b> Anatomy of the Larynx; Laryngoscopy; Inflammations of the Larynx; Tubercular Laryngitis; Syphilitic Laryngitis; Benign Tumors of the Larynx; Malignant Growths in the Larynx; Foreign Bodies in the Larynx . . . . .	173

## THE NOSE.

<b>ANATOMY OF THE NOSE:</b> Rhinoscopy . . . . .	195
<b>INFLAMMATIONS OF THE NOSE</b> . . . . .	202
<b>NASAL MANIFESTATIONS OF CERTAIN CONSTITUTIONAL DISEASES:</b>	
Syphilis of the Nose; Tuberculosis of the Nose; Scrofula; Lupus .	212
<b>BENIGN TUMORS OF THE NOSE—POLYPI</b> . . . . .	215
<b>MALIGNANT TUMORS OF THE NOSE</b> . . . . .	218
<b>FOREIGN BODIES IN THE NOSE</b> . . . . .	218
<b>EPISTAXIS</b> . . . . .	219
<b>DEVIATIONS OF THE SEPTUM</b> . . . . .	220
<b>NASAL EXOSTOSES</b> . . . . .	221
<b>HÆMATOMA OF THE SEPTUM</b> . . . . .	224
<b>ANOSMIA AND PAROSMIA</b> . . . . .	224



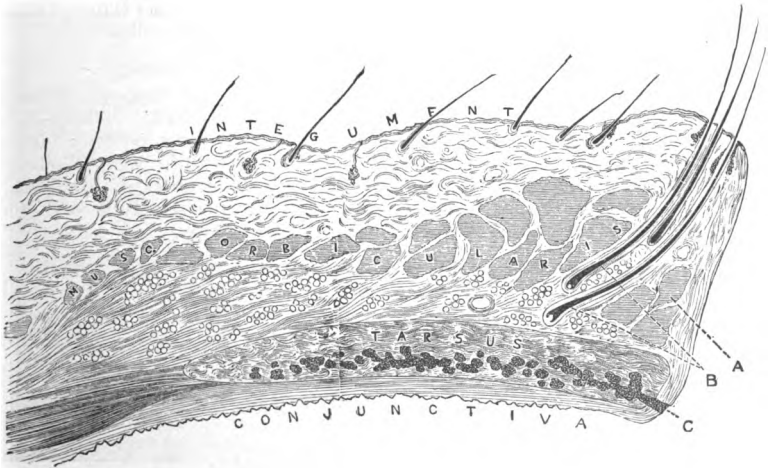
# THE EYE AND ITS DISEASES.

## THE LIDS.

### What is the structure of the lids?

FROM without inward we have first the skin, which is very thin and studded with very fine hairs. Immediately beneath is the subcutaneous areolar connective tissue, in which is imbedded the sphincter muscle of the lids, the orbicularis palpebrarum. Beneath this is the tarsus, a firm thick plate of connective tissue, measuring in the upper lid  $\frac{1}{2}$  inch in

FIG. 1.



Section through Upper Eyelid: *a*, the ciliary muscle of Riolanus; *b*, follicles of the eyelashes; *c*, opening of the Meibomian follicles.

width, in the lower one  $\frac{1}{4}$  inch in width, each being about 1 inch in length. They serve to maintain the shape of the lid, and are attached to the margin of the orbit by a thin strong aponeurosis called the palpe-



bral ligament, which is adherent to their curved borders. The levator palpebræ superioris muscle has its attachment by an expanded tendon to the upper border of the tarsus of the upper lid, which also gives attachment to the small muscle composed of non-striated muscle-fibres known as Müller's muscle. Immediately beneath the tarsi and firmly adherent to them is the thin mucous membrane known as the conjunctiva. Imbedded in the tarsi are the large racemose glands termed the Meibomian glands. These glands are about thirty in number in the upper, and twenty in number in the lower, lids. The Meibomian glands open by their ducts on the inner side of the margin of the lid. Springing from the outer side of the margin of the lid are the cilia, or eyelashes, usually presenting three or four rows, curved and about  $\frac{1}{2}$  an inch in length. The hair-follicles penetrate deeply into the lid; opening into each follicle is the duct of a small sebaceous gland. Posterior to the openings of the hair-follicles are the mouths of the small glands known as the glands of Moll. Lying between the hair-follicles and the ducts of the Meibomian glands are a few fasciculi of the orbic. palp. muscle, termed the muscle of Riolanus. The orbic. palp. muscle is divided into two portions, the orbital and palpebral. It takes its origin from the inner canthal or tarsal ligament, some of the fibres passing beneath and some over the lachrymal sac. The fibres of the muscle pass outward in a curved direction, and some have their insertion into the external canthal or tarsal ligament.

#### **From what source do the lids derive their blood-supply?**

The greater part of the blood-supply to the lids comes from the internal carotid by way of branches from its ophthalmic division. The lachrymal and naso-frontal branches of the ophthalmic pass outward into the substance of the lid at the external and internal canthi respectively, and go to form the superior and inferior marginal arteries of the lids. A portion of the supply to the integument and deeper structures comes from the external carotid by the way of the facial artery.

#### **From what source is the nerve-supply to the muscles of the lid derived?**

The orbic. palp. receives its motor nerve-branches from the facial. The levat. palp. super. receives its nerve-supply from the third cranial, the motor oculi.

### **DISEASES OF THE LIDS.**

#### **What is blepharitis?**

Any inflammation of the lid is termed blepharitis. The term, however, is usually applied to inflammatory affections of the margin of the lid, and is commonly known as **blepharitis marginalis**, having as synonyms the terms **blepharitis ciliaris** and **blepharo-adenitis**.

#### **What are the causes of blepharitis?**

Blepharitis is usually due to infection of the hair-follicles or the small

glands connected with the hair-follicles. It may also be produced by the constant presence of irritating substances on the margins of the lid, due to uncleanness and chronic conjunctivitis, the presence of parasites in the shape of pediculi, fungi, etc. Errors of refraction producing eye-strain may serve to bring about the condition.

### **What are the symptoms?**

In blepharitis marginalis there is usually more or less irritation of the eyes, a redness of the lids, and in the majority of cases the formation of crusts at the roots of the cilia. The secretion produced by the irritation of the hair-follicles and associated glands dries on the margins of the lids, producing yellow crusts which are difficult of removal.

### **What is the treatment for blepharitis?**

The all-important requisite in the *treatment* of blepharitis is cleanliness. This may be obtained by careful bathing with hot water and castile soap. After all crusts are removed applications of various kinds may be made to the inflamed surface. In the ordinary forms the application of an ointment of the red or yellow oxides of mercury in vaseline as a vehicle, in the strength of from 1 to 2 per cent., to the margins of the lid once or twice daily, will usually effect a cure. Applications of the nitrate of silver in solutions or of the acetate of lead in solution may be employed. In sycosis parasitica total epilation in addition will be necessary.

### **What is hordeolum or sty?**

This term is employed to designate the painful localized swelling which frequently occurs at the margin of the lid. It has its origin in an acinus of the Meibomian gland, and eventuates in the formation of a pustule. Successive crops are apt to appear.

### **What is the cause of hordeolum?**

Probably in almost every case hordeolum is due to a microphytic infection of an acinus of a Meibomian gland. Constitutional derangements and eye-strain undoubtedly contribute to its production.

### **What are the symptoms of hordeolum?**

The first *symptom* noticed by the patient is a localized pain at the margin of the lid, which is found to proceed from the locality of a swelling, usually of a deep-red color; lachrymation, photophobia, and inability to use the eyes are frequent accompaniments. The pain increases with an increase in the size of the swelling. This continues for three or four days, at the end of which time formation of pus has taken place and the sty has in all probability ruptured: the pain then ceases and recovery ensues.

### **What is the treatment of hordeolum?**

Hot applications, made by means of small pledgets of lint dipped in

hot water and changed every two or three minutes, or the application of small moist flaxseed poultices, will probably give the greatest relief in the early stage. As soon as there is evidence of the presence of pus the swelling should be freely incised and the contents thoroughly evacuated. Occasional bathing with a saturated solution of boric acid or with a weak solution of bichloride of mercury will suffice to effect a cure. Treatment directed to the general condition and the occasional application of ointment of the red or yellow oxide of mercury to the margin of the lids will aid greatly in preventing recurrences.

### **What is meant by the term chalazion?**

The term is applied to the cystiform enlargement of an acinus of a Meibomian gland. It is supposed by some to be an aborted hordeolum. It usually appears somewhat removed from the margin of the lid, rarely reaching a size exceeding one-third of an inch in diameter, and may be single or multiple. It contains a gelatinous material. The inflammatory action producing it may involve the adjacent connective-tissue elements of the lid. The growth is perfectly benign.

Chalazion may be said to be due to the same *causes* that produce hordeolum.

### **What is the treatment of chalazia?**

They should be incised, their contents scooped out with a sharp spoon, and the interior of the sac treated with a strong solution of the nitrate of silver, or they may be entirely excised. Recurrences are possible only on incomplete removal of the contents and sac. However, so long as the Meibomian glands exist chalazia may appear.

### **What are the so-called fibrous tumors of the lid?**

They are chalazia which have passed to a stage of development in which their contents is converted into or replaced by connective tissue.

The *causes* are the same as those producing chalazion, and the *treatment* is excision.

### **What are nævi?**

Nævi are slightly-elevated, frequently-pigmented patches, congenital in nature, which appear on the lids. They resemble in structure the nævi which appear in other parts of the body.

### **What is cavernoma of the lid?**

Cavernoma is a vascular structure composed of anastomosing spaces resembling dilated veins which occurs in the connective areolar tissue-structure of the lids, either originating in the lids or being an extension of the same growth from adjacent parts of the face. They are not infrequently congenital, and have a tendency to increase in size. In addition to cavernoma we have an allied growth due to the dilatation of capillaries and small arteries, known as angioma.

**What is the treatment of cavernoma ?**

Complete extirpation is by far the most satisfactory plan of *treatment*, and should be employed whenever it can be done with safety. Electrol-ysis is frequently employed with good results by making multiple punctures around the base of the tumor with the electrolytic needles, with the object of cutting off the blood-supply. Complete strangulation or complete excision prevents recurrence.

**What is xanthalmasia ?**

Xanthalmasia is characterized by the appearance of small yellowish-white patches in the skin of the lids, having their location most frequently on the upper lid near the inner canthus. They come in advanced life. Ophthalmoscopic examination shows them to be composed of numerous granular cells, some of which are pigmented, located in the skin. They have no pathological significance, and are only objectionable because of the cosmetic effect produced. They may be easily removed by excising the portion of the skin affected.

**What is epithelioma of the lid ?**

Epithelioma is a malignant growth usually affecting the margin of the lid and advancing slowly: if not interfered with, it goes on to the destruction of the lids and deeper structures, eventuating in the death of the patient. It is composed of epithelial cells which have become perverted in their growth and location.

**What are the symptoms of epithelioma ?**

The patient's attention is generally first called to the presence of a small elevation, usually accompanied by a little redness or other inflammatory symptoms, covered with a light scab, situated on the margin of the lid. It may also appear as a small papilloma or bluish-looking wart on the lid or face in the immediate vicinity, which takes on an ulcerative change. The scab covering the ulcerated surface is frequently removed, but the ulcer shows no tendency to heal. The epithelioma may continue in the condition described for months or years, but sooner or later the ulcer extends. When in active growth the patient experiences frequent lancinating pains, which, however, are seldom severe. As the deeper structures are involved pain increases.

**What is the treatment of epithelioma ?**

Various methods of *treatment* of epithelioma have been employed. The use of escharotics in the form of chloride-of-zinc paste or the actual cautery have been employed with more or less success. The application of acetic acid in the form of glacial acetic acid has met with some favor. It is conceded, however, by many authorities that excision as complete as possible, supplemented by the use of the cautery in cases where the knife or curette do not succeed in removing all of the tissue involved, is the most successful.

**What are papillomata?**

These growths are hypertrophied papillæ of the skin. They should be removed whenever found, as there is a possibility of their degenerating into epithelioma. *Lipoma* is a tumor of the lid that is met with but very infrequently. It is harmless in nature.

**What is molluscum contagiosum?**

This term is applied to an affection of the sebaceous glands whereby the gland and duct become greatly hypertrophied and form rounded elevations on the lids, appearing usually on the lower lid near the nose. There are usually a number of these elevations present at the same time, varying in size. They may reach the height of  $\frac{1}{2}$  inch, but usually are only a few millimetres in height. Their diameter, as a rule, corresponds to their height. In the centre of the top of each elevation a whitish point may be seen, which marks the opening to the duct of the gland involved, and from this duct a whitish cheesy material may be made to exude on pressure. These growths are undoubtedly mildly contagious. They are unaccompanied by pain unless acutely inflamed.

**What is the treatment of molluscum contagiosum?**

The elevation may be split from base to apex and the contents thoroughly scraped out, or, what is better still, the entire growth may be excised. Relapses are uncommon.

**What are the manifestations of syphilis found in the lids?**

Indurated chancre, gumma, and tertiary sores. Indurated chancre is of rare occurrence on the external surface of the lid, but is not so infrequent an occurrence on the conjunctival surface. It manifests itself in the form of a dark-red papilla with indurated base and a scaly or ulcerated surface, exactly as the indurated chancre appearing in other parts. The history of chancre of the lid as to cause is frequently obscure, and the appearances only, taken in connection with the effects of antisyphilitic treatment, must serve to make the diagnosis.

**What are the appearances and symptoms of gumma and tertiary sores?**

Gumma of the lid has no peculiar characteristics to distinguish it from gumma of other parts of the body. Its appearance is accompanied with little pain.

The history in the case and the conduct of the elevation under general antisyphilitic treatment will serve to make the *diagnosis*. Tertiary sores are not of common occurrence. They, however, occur, usually forming near the free margin of the lid and extending rapidly. Like tertiary sores in other parts of the body, they present an ulcerated surface with indurated bases, and pass quite rapidly to destruction of the tissue involved. A lid may disappear very rapidly under the influence of the tertiary sore. The diagnosis must depend largely on the history of the case and the effect produced by antisyphilitic treatment.

**What is meant by the term blepharospasm ?**

This term is applied to involuntary closures of the lids, which may be of a clonic nature, occurring frequently in rapid succession, or they may be of a tonic nature.

**What are the causes of blepharospasm ?**

It is due in all cases to irritation of filaments of the facial nerve. The causes of this excitation in clonic spasm are errors of refraction, diseases of the nervous system, as chorea, epilepsy, etc. ; in tonic spasm, to foreign bodies in the eye, ulcerative conditions of the cornea or conjunctiva, and injuries to the eye, producing photophobia.

**What is the treatment of blepharospasm ?**

Removal of the cause where this is practicable, and improvement of the general condition where the cause is obscure.

**What is ptosis ?**

Ptosis is the term applied to a drooping of the upper lid in such a manner that it cannot be raised sufficiently to open the palpebral fissure to the desired extent.

**What are the causes of ptosis ?**

The *causes* of ptosis are congenital malformation or non-development of the nucleus of the third nerve, diseases affecting the function of the third nerve, or traumatism. In congenital ptosis other parts of the third than those concerned in elevating the lid are usually involved. In acquired ptosis syphilis is frequently the cause.

**What is the treatment of ptosis.**

The *treatment* is medicinal and surgical. The history of the case must be carefully ascertained, and if syphilis or other disease-processes are instrumental in its production, appropriate medication must be employed to correct the condition if possible. Congenital ptosis must usually be corrected by operative procedure. The simplest form of operative procedure consists in the removal of an elliptical piece of skin, with the underlying muscle, from the upper lid, and stitching the edges of the wound together. The operation devised by Pagenstecher is applicable to nearly all forms of ptosis, and is frequently efficient. It consists in forming subcutaneous cicatricial bands from the margin of the lid to the anterior portion of the occipito-frontalis muscle. Pagenstecher passes a suture through the integument at about 2 cm. from the ciliary margin, at the centre of the lid, and continues it subcutaneously to the ciliary margin. He then forms a loop, passes the suture upward again, and brings it out on the skin of the lid near the point at which the suture entered. The ends of the suture are then tied, and tightened every day until the suture has cut through the tissues. A cicatricial band is thus formed, which, according to Pagenstecher, is usually sufficient. Two or more bands may be formed as desired.

### What are trichiasis, distichiasis, and entropion ?

They are various forms of one and the same affection, and consist in a displacement of the cilia toward, and usually against, the cornea.

### What is the cause of these affections ?

An abnormal development of the cilia may produce the condition known as trichiasis, but in almost every case these three affections owe their existence to the cicatrization of the conjunctiva produced by granulated lids.

### What is the treatment of these conditions ?

Trichiasis, if not extensive, may be corrected by the frequent removal of the cilia. Electrolysis may be employed here with beneficial effect. Distichiasis and entropion usually require operative procedure of a more pronounced nature. All operations employed for this purpose have for their object the correction of the direction of the cilia. The Streatfeild-Snellen operation is one of the most popular, and is performed as follows: The globe is protected by the introduction of a horn spoon or of a plate clamp into the conjunctival sac. An incision is then made through the skin and muscle of the lid to the tarsus, extending from the inner to the outer canthus, and placed about 2 lines from the margin of

FIG. 2.

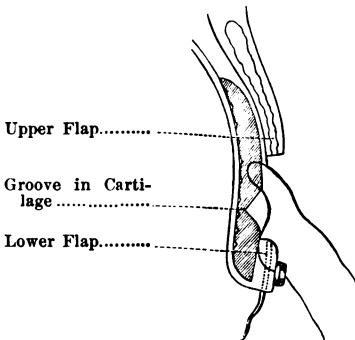
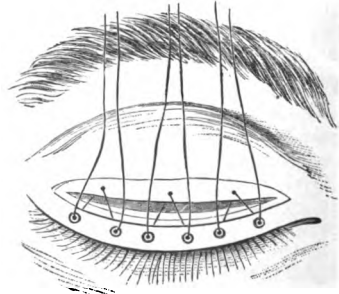


FIG. 3.



The Streatfeild-Snellen Operation for Entropion.

the lid. An elliptical piece of the skin from 1 to 2 lines in width, including the underlying tissues to the tarsus, is then removed with a sharp scalpel or scissors. A wedge-shaped piece of the tarsus, having its base outward and extending the length of the incision, is then removed. The wound is then closed by three sutures, which are passed in the following manner: At the margin of the lid the needle is passed through the skin

and underlying loose tissues, carried to the upper margin of the wedge-shaped depression in the tarsus, where it includes the superficial layers of the tarsus, and is brought out without piercing the integument of the upper margin of the wound. These sutures are then firmly tied. This manœuvre suffices to draw the lower margin of the skin of the lid upward and to attach it to the tarsus, producing eversion of the cilia. Numerous other operations are devised and employed by various operators.

#### **What is spasmodic or spastic entropion ?**

A form of entropion not infrequently met with in old people, always affecting the lower lid, is known as spasmodic or spastic entropion. It is usually corrected by removal of an elliptical piece of integument and underlying connective tissue and muscle, the long axis of which is placed at right angles to the margin of the lid. The opening is closed with three or four sutures.

#### **What is ectropion ?**

This term is used to designate a condition of the lid in which the margin of the lid is everted and the conjunctival surface is exposed.

#### **What are the causes of ectropion ?**

Injuries of various kinds, of which burns are the most frequent, that destroy the skin of the lids, and produce ectropion by the cicatricial contraction which follows. Ectropion may also result from the paralysis of the facial nerve. Certain hypertrophic conditions of the conjunctiva also produce ectropion.

#### **What is the treatment of ectropion ?**

In the mildly-marked cases due to the hypertrophy of the conjunctiva the condition may be corrected by painting the surface with a solution of nitrate of silver, 10 or 20 grains to the ounce, the application being repeated every twenty-four or forty-eight hours. In pronounced cases operative procedure must be resorted to. In ectropion of the lower lid, in which there is an evident elongation of the margin of the lid and atony of the adjacent skin, a wedge-shaped piece of tissue, having its base at the margin of the lid and its apex at the bottom of the conjunctival sac and the integument below, may be removed, and the opposing margins of the wound brought together with strong sutures. This operation, which is known as Adam's operation, is usually successful in this class of cases. In extensive ectropion skin-grafting must be resorted to. The lid is dissected free and fixed in position by attaching it to the margin of the fellow-lid, and the wound thus resulting is covered with flaps of skin, either taken from adjacent parts, to which they are attached by a pedicle, or from remote parts after the manner of Wolfe.

#### **What is epicanthus ?**

This is a condition of the skin at the base of the nose in which the



inner canthus is partly hidden from view. It gives the peculiar almond-eyed appearance characteristic of the Chinese.

### **What is the treatment of epicanthus?**

Epicanthus usually appears in young children, and by the development of the bridge of the nose will disappear. When present in older individuals an elliptical piece of skin may be removed from the bridge of the nose, its long axis extending from above downward, and the margins of the wound brought together with fine sutures.

### **What is ecchymosis of the lids?**

This is a condition of the lids brought about by contusion, which produces the escape of blood and of serum from the vessels of the lid, causing a bluish discoloration and swelling commonly known as "black eye."

### **What is the treatment?**

The most efficient *treatment* in the early stage is by cold applications, cold acting as a hæmostatic preventing further escape of fluids into the tissues. After twenty-four or thirty-six hours have elapsed the exudation will have ceased, and hot applications to promote absorption should be employed.

### **What treatment is employed when wounds or burns of the lid occur?**

Lacerated wounds of the lids should be corrected as quickly as possible after occurrence by stitching and other appropriate surgical methods. Burns and scalds are treated as burns and scalds in other parts of the body.

### **What is meant by the term ankyloblepharon?**

This term is applied to a condition where the margins of the lids become adherent to each other. Its correction requires division of the bands of adhesion simply.

### **What is meant by the term symblepharon?**

This term is used to designate the condition of adhesion between the lids and the eyeball. It is usually the result of a burn of the conjunctiva from lime, acid, or any other escharotic. Its correction requires operative procedure, which is usually unsatisfactory.

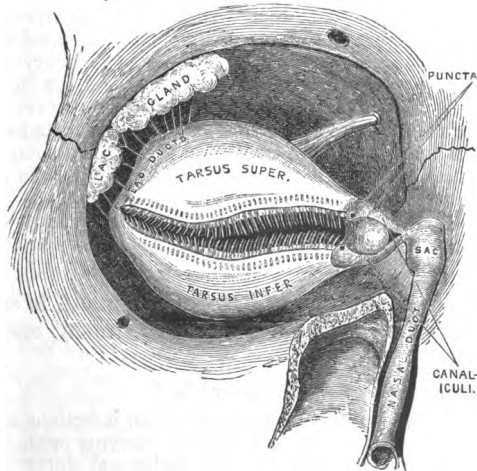
## **THE LACHRYMAL APPARATUS.**

### **Of what does the lachrymal apparatus consist?**

It consists of a secretory and conducting portion. The secretory portion is the lachrymal gland, which is composed of acini and resembles the salivary glands in construction. The lachrymal gland is made up of two portions—a large superior portion and a smaller inferior portion.

The superior portion of the lachrymal gland measures about  $\frac{1}{2}$  inch by  $\frac{1}{2}$  inch, and is  $\frac{1}{4}$  inch in thickness. It is located at the outer superior angle of the orbit, immediately beneath its roof, in a depression known as the lachrymal fossa. It is held in position by numerous delicate bands of connective tissue, and communicates with the conjunctival sac by from six to ten ducts. The smaller, inferior portion of the lachrymal gland consists of a number of isolated lobules situated immediately beneath the conjunctiva of the upper lid, near the external canthus. They communicate by individual ducts with the conjunctival sac at its outer superior portion. The secretion of these glands, which is a watery fluid containing about 1 per cent. of solids and strongly impregnated with chloride of sodium, is thrown out under a stimulus to the sympathetic. It passes into the conjunctival sac, and serves to moisten the anterior portion of the globe, being distributed by the movements of the lid.

FIG. 4.



Dissection of the Lachrymal Apparatus.

**In what way do the tears escape from the conjunctival sac ?**

The tears (or lachrymal secretion) pass from the conjunctival sac into the nose by the way of the lachrymal puncta, the lachrymal canals, the lachrymal sac, and the nasal duct. The lachrymal puncta are two small elevations which occur at portions of the lids situated about 2 lines from the inner canthus. They are pierced by openings measuring about 5 mm. in diameter. Commencing immediately beneath the lachrymal puncta

are the two lachrymal canals, one beneath the upper and one beneath the lower lid. They first pass upward and downward respectively for a very short distance, then describe a curve about the inner canthus, unite, and pass into the lachrymal sac. Immediately beneath the puncta they measure about 1 mm. in diameter, but in the course of the canal they reach a diameter of 6 mm., and remain of this size until they enter the sac. The walls of the lachrymal canals are relatively thick. They are lined with stratified epithelium, and contain numerous fibres of muscle-tissue.

#### **What are the form, situation, and structure of the lachrymal sac ?**

The lachrymal sac is situated in a groove formed by the lachrymal bone and the nasal process of the superior maxillary. It measures about  $\frac{1}{2}$  inch in its vertical diameter and about  $\frac{1}{4}$  inch in its horizontal and transverse diameters. It is located immediately to the inner side of the inner canthus, and is pierced by the lachrymal canals at a distance of about  $\frac{1}{2}$  inch from its apex. Its lower extremity is a direct continuation of the upper part of the nasal duct. Its walls are relatively thin, composed of connective tissue, and its inner surface is lined with ciliated epithelium. The nasal duct, a continuation of the lachrymal sac at its lower extremity, consists of a similar structure, and lies in a canal the bony walls of which are formed by the lachrymal, superior maxillary, and inferior turbinated bones. It measures about  $\frac{3}{4}$  inch in length and is  $\frac{1}{2}$  to  $\frac{1}{4}$  inch in diameter. The surface of the mucous membrane lining this canal is paved with ciliated epithelium, and has a free opening into the inferior meatus of the nasal fossa. The tears pass through the puncta, through the lachrymal canals, the lachrymal sac, and nasal duct, and are discharged into the inferior meatus, where they are dispersed by evaporation.

#### **What are the diseases that the lachrymal gland is subject to ?**

Inflammation, known as dacryoadenitis, hypertrophy, cystic and cancerous degeneration.

#### **What are the causes of dacryoadenitis ?**

The *causes* of dacryodenitis are probably of an infectious nature. The entrance of dust into the conjunctival sac, carrying with it infectious material, which makes its way into the lachrymal ducts, exposure to cold, and traumatism, may be considered as factors.

#### **What are the symptoms and treatment of dacryoadenitis ?**

Dacryoadenitis manifests itself by a swelling at the outer angle of the lids, with more or less redness of the outer portion of the conjunctiva. It is accompanied with slight pain, referable to the temple. Its onset is sudden, and it usually reaches its height at the end of two or three days. It eventuates usually in suppuration, rapidly subsides on evacuation of the pus, and runs its course in from a week to ten days. The superior

portion of the lachrymal gland is seldom affected. It is, on the whole, a rare disease, and may be recognized, in addition to the symptoms above described, by the presence of a hard swelling at the margin of the orbit, appreciable on palpation. If the patient is directed to turn the eye forcibly inward, a body usually as large as a small bean is made to push forward from the external portion of the upper cul-de-sac of the conjunctiva.

#### **What is the treatment ?**

This consists in hot fomentations at the beginning to encourage formation of pus. When pus is present the tumor may be lanced from the conjunctival surface, or, better still, the fomentations may be continued for a few hours and the pus be permitted to evacuate itself.

#### **Is hypertrophy of the lachrymal gland of frequent occurrence ?**

Hypertrophy of the lachrymal gland is very infrequent, and is probably always due to sarcomatous degeneration.

#### **What are its causes and treatment ?**

The *causes* are unknown.

The *treatment* consists in extirpation of the gland.

#### **What are the causes of cystic degeneration, and its treatment ?**

Cystic degeneration occurs very infrequently. It may be caused by traumatism, but is sometimes due to the presence of echinococci. Cystic degeneration of the gland is not infrequently associated with sarcomatous degeneration. When echinococci are the cause, simple puncture with evacuation of the cyst and destruction of its wall suffices to effect a cure. In other cases, particularly if sarcoma is suspected, the gland should be extirpated.

#### **What are the symptoms and treatment for cancerous degeneration of the lachrymal gland ?**

The lachrymal gland may be the seat of sarcoma or of carcinoma. The *symptoms* in these two forms of malignant growth are very similar. The gland becomes enlarged, and is felt under the upper outer angle of the orbit as a firm mass which protrudes into the orbit, and, when it has attained a sufficient size, compresses the tissues in its immediate vicinity. The globe is not infrequently pushed downward and inward by the increase in size of the growth.

The *treatment* consists in total extirpation at the earliest possible moment.

#### **What is fistula of the lachrymal gland ?**

A condition usually due to traumatism, by which the tears find exit on the surface of the brow or cheek.

The *treatment* of this condition consists in an endeavor to stop up the artificial opening on the skin and direct the secretion to the conjunctival

sac. The passage of a seton from the gland to the conjunctival surface and the use of the cautery to close the external opening may effect the object desired.

### **What is epiphora ?**

This term is applied to the escape of tears from the conjunctival sac on to the cheek, without inflammatory occlusion of the conducting apparatus: it is more properly applied to the escape of tears in excessive lachrymation, which is termed *stillicidium lachrymarum*.

### **What pathological conditions is the conducting apparatus subject to ?**

The escape of tears from the conjunctival sac into the nasal cavity may be prevented by misplacement of the puncta lachrymalis. Traumatism or inflammatory processes may occlude the canals and the nasal duct.

### **What are the causes of displacement of the punctum ? and how may this condition be remedied ?**

An atonic condition of the lids, such as sometimes occurs in old people, may permit the lachrymal puncta to fall away from the eyeball and make it impossible for the tears to escape. Facial paralysis affecting the orbicularis palpebrarum muscle may also bring about this result.

The *treatment* consists in so treating the lids that the lachrymal puncta will be reapplied. Failing in this, the canals may be split up and an opening made which will permit the tears more easily to enter the lachrymal sac.

### **What diseases of the lachrymal canals come under consideration ?**

The canals may be stopped by inflammatory processes, usually catarrhal in nature; by extension from the lachrymal sac or from the conjunctiva; they may be the seat of calcareous deposits, or they may be occupied by fungous growths, of which *leptothrix buccalis* is of most frequent occurrence.

The *treatment* in these cases consists in opening the canals to the sac.

### **What diseases do we meet with affecting the lachrymal sac ?**

Inflammation of the lining membrane of the lachrymal sac, usually purulent in nature, is by far the most common disease the lachrymal apparatus is subject to.

The *causes* which bring about this condition are included under the term catarrhal, except in those relatively rare cases where necrosis of the lachrymal bone is the originating cause. The entrance and the retention in the lachrymal sac of pus-forming germs and of germs which have a pathological influence on the mucous membrane of the lachrymal sac produce an inflammation which becomes purulent. These deleterious

influences are communicated usually through the medium of the nasal duct to the lachrymal sac, and originate in a catarrhal affection of the nasal mucous membrane. Stricture of the nasal duct may ensue, causing retention of tears in the lachrymal sac, and preventing the escape of secretions the presence of which tends to perpetuate the inflammatory conditions of the mucous membrane. As the disease progresses an hypertrophied condition of the sac is brought about, and polypi not infrequently form.

### **What are the symptoms and treatment of this condition ?**

In the early stage of stricture of the nasal duct and of catarrhal inflammation of the mucous membrane of the sac but little may be noticed by the patient other than an escape of tears from the eyelids on to the cheek. This may go on for a number of months or even years. At the onset of acute inflammatory symptoms the patient usually experiences pain in the region of the sac, and a swelling of the tissues ensues. Palpation discloses the presence of a round, hard tumor at the inner canthus, which on pressure will evacuate mucus or pus into the conjunctival sac or into the nasal cavity. Frequently the pain, swelling, and redness become excessive, the patient suffering very severely. The pus which has accumulated in the lachrymal sac may be unable to escape, and may form an opening on the skin spontaneously.

The *treatment* of this condition, which should be commenced as soon as trouble with the lachrymal sac is noticed, is varied according to the stage of the disease. In its incipiency the correction of a catarrh of the nasal passages may suffice to remove the stricture of the nasal duct and to promote a cure. When pus has begun to be formed the safer method of treatment is to open up the lachrymal canal, pass a probe through the sac and nasal duct into the nose, and thoroughly cleanse the whole passage by the use of appropriate injections.

### **What is the operation for slitting the lachrymal canals and passing a probe through the nasal duct into the nose ?**

The lachrymal knife, which is devised for the purpose of opening the canal, consists of a small scalpel which is supplied with a probe point. Various patterns of these knives have been devised by various operators, some of which are known under the names of Bowman, Wecker, Stilling, Agnew, Noyes. For the complete operation the knives devised by Stilling and by Agnew are probably the best. Possessing a blade as described above, with slight modifications in regard to form, they are supplied with long flexible shanks. The operation is performed by passing the probe point into the canal at the lachrymal punctum (the lower canal is usually the one operated on), then by turning the axis of the knife in the direction of the long axis of the canal the point of the knife is carried into the sac and firmly pressed upon the mucous membrane against the lachrymal bone. While this is being done the lid is put on the stretch toward the temple, and, while held firmly in this position, the edge of

the blade being directed upward, the handle of the knife is swept upward in front of the brow and close to it, and the lachrymal canal is freely opened to the sac. The axis of the blade is then placed in the position corresponding with the axis of the nasal duct, and is pushed down into the nasal duct. The stricture of the duct, if one exists, is divided freely in three or four directions. The knife is then removed and a probe passed into the nose, the same manœuvre and direction being followed as followed by the knife. After probing, the canals, sac, and duct are thoroughly cleansed by means of a syringe and an anti-septic solution : a 4 per cent. solution of boric acid is employed by many. A solution of bichloride of mercury, 1 : 5000, and a  $\frac{1}{2}$  per cent. solution of the nitrate of silver, are also popular. The probes employed are of different styles, according to the ideas of the different operators. Those most commonly in use are the probes of Bowman, which are composed, usually, of silver wire tapered at the ends, and of six sizes, the largest size measuring about 1 mm. in diameter and 12 cm. in length. Those of Theobald are much larger. These are twelve in number, and range from 1 to 4 mm. in diameter. Small probes are fancied by some operators, but it appears to be the growing opinion that as large a probe as can be easily accommodated by the canal should be employed.

#### **How should the after-treatment be conducted ?**

It is a recognized fact that after opening the canals and nasal duct there is a strong tendency to closure during the process of healing. It is therefore necessary to pass a probe at intervals of from two to eight days during the healing process, and to wash the canals with an anti-septic lotion.

#### **What is abscess of the lachrymal sac ?**

This condition is simply an aggravated stage of the ordinary suppurative inflammation of the mucous membrane of the lachrymal sac, during the process of which the nasal duct and lachrymal canals become closed and the exit of pus prevented.

#### **What is the treatment of abscess of the lachrymal sac ?**

The pus should be evacuated either through the lachrymal canals or the nasal duct if possible. When this cannot be done a free incision into the sac through the skin becomes necessary. At the earliest possible moment thereafter the natural canals should be re-established.

#### **What is fistula of the lachrymal sac ?**

Fistula consists in an opening from the lachrymal sac on to the surface of the skin, through which tears and secretion escape.

The *treatment* consists in establishing the natural passages, removing what granulation tissue may have formed along the fistulous track, after which healing, with closure of the fistula, rapidly occurs.

## THE CONJUNCTIVA.

### What is the conjunctiva ?

The conjunctiva is a thin, delicate mucous membrane which begins at the free margin of the lids, covers their under surface, and is reflected on to the globe of the eye and continued over the cornea. It is divided into three portions, the palpebral, fornix, and ocular portions. The principal part of the palpebral portion covers and is closely adherent to the tarsi. It then, in loose folds known as the fornices conjunctivæ, becomes reflected upon the sclerotic of the globe, to which it is connected by loose areolar connective tissue. Sacs are thus formed, the upper one of which is 1 inch in depth, the lower one  $\frac{1}{2}$  inch in depth. The corneal portion of the conjunctiva is very thin, and is represented by the epithelium. The epithelium of the conjunctiva is of the stratified variety; over the tarsi, the sclerotic, and cornea the conjunctiva is smooth, but it is thrown into folds, and in some places into papillæ, in the fornix. A few tubular glands are found in the fornix folds, and the ducts of the lachrymal glands open into the fornix in the outer third of the upper conjunctival sac. The conjunctiva is richly supplied with lymphatics, which anastomose freely immediately beneath the epithelial layer. At the inner canthus a fold of conjunctiva is formed which corresponds with the membrana nictitans or third eyelid of inferior animals. We also find at the inner canthus a reddish elevation which is known as the caruncle. This is covered by mucous membrane, and sometimes presents a few very fine hairs projecting from its surface.

### What forms of inflammatory disease is the conjunctiva subject to ?

They may be classified as follows : First, simple conjunctivitis; second, traumatic; third, muco-purulent conjunctivitis; fourth, purulent or gonorrhœal conjunctivitis; fifth, granulated lids or trachoma; sixth, phlyctenular conjunctivitis; seventh, diphtheritic conjunctivitis.

### What is simple conjunctivitis ?

Simple conjunctivitis is the mildest form of inflammation that the conjunctiva is subject to.

The *symptoms* presented are redness, lachrymation, slight irritation, and more or less photophobia.

### What are its causes and treatment ?

It is usually due to exposure to cold and raw wind, the presence of minute foreign bodies, eye-strain, excessive bathing in salt water, etc.

The *treatment* is very simple, consisting in removing any cause that may be instrumental in its production and bathing of the eyes with mild astringents or antiseptic solutions. Ordinary salt and water or a 2 per cent. solution of boric acid will suffice to effect a cure. Simple conjunctivitis of a chronic nature is often associated with catarrh of the nasal mucous membrane, and may be cured by correcting the catarrh of this membrane.



**What is traumatic conjunctivitis ?**

Any inflammation excited by the entrance of foreign bodies, irritating fluids, or direct injury to the conjunctiva may be termed traumatic conjunctivitis. Since it does not depend on the presence of any infectious principle, recovery usually rapidly occurs on the removal of the obnoxious substance. Cleanliness secured by bathing in salt and water or a boric-acid solution will hasten the restoration to the normal condition.

**What is muco-purulent conjunctivitis ?**

This is a term given to a diseased conjunctiva in which there is redness and swelling of this membrane, accompanied by the production of a secretion which contains numerous pus-corpuscles mixed with mucus. There are more or less lachrymation and puffiness of the lids. This disease has as synonyms the terms catarrhal conjunctivitis and acute epidemic conjunctivitis. It is very contagious in nature, reaches its acute stage in forty-eight to seventy-two hours, has no tendency to affect the cornea, and runs a natural course in from ten days to six weeks; in exceptional cases the disease may continue for six months. Relapses are of frequent occurrence. This disease becomes endemic in communities and in residential schools, showing its greatest activity usually in the spring and fall months. Its epidemic nature is recognized throughout the civilized world.

**What are the causes of muco-purulent or epidemic conjunctivitis ?**

The form most frequently seen is a specific disease and has a specific cause. This is found in the presence of a small bacillus, which has been carefully studied and described by Weeks. The pathogenic micro-organism is a small straight bacillus measuring  $\frac{1}{4}$  micro-millimetre in width by from 1 to 2 mm. in length. It grows on agar at a temperature ranging between 85° and 110° F., and its inoculation into the normal conjunctival sac from a pure cultivation invariably produces the disease. The disease is communicated undoubtedly through secretion from the eyes of patients suffering from the malady. Traumatic conjunctivitis and mild forms of gonorrhoeal conjunctivitis sometimes produce a muco-purulent secretion, and are classed under this head.

**What are the symptoms of this disease ?**

The patient first experiences a burning sensation in the lids and the sensation of the presence of a foreign body. This irritation is rapidly followed by lachrymation and the production of a mucoid secretion. In twenty-four hours the secretion becomes muco-purulent. The conjunctiva is swollen and the lids slightly puffed. As the disease progresses the annoyance to the patient becomes marked, and photophobia is experienced. The disease reaches its height in from two to four days, at the end of which time the secretion assumes a more purulent character. The annoyance to the patient gradually ceases, secretion becoming less marked, and recovery without other treatment than cleanliness often

occurs at the end of the second week. Adults suffer more than children. False membranes are sometimes noticeable on the conjunctival surface, phlyctenulæ may appear as a complication after the disease has lasted for three or four days, and trachoma, due to a secondary infection, may continue after a subsidence of this form of conjunctivitis.

#### **What is the treatment of muco-purulent conjunctivitis?**

During the first few days much relief can be given to the patient by the application of cold compresses and by frequent cleansing with a saturated solution of boric acid. After the third day mild astringents may be applied with benefit. The cleansing should be continued until all secretions have disappeared. The astringents employed are solutions of the nitrate of silver,  $\frac{1}{2}$  to 1 per cent., and of the sulphate of zinc or acetate of lead, 1 grain to the ounce. If phlyctenulæ or trachoma develop, the treatment should conform to that for the disease mentioned. The presence of pseudo-membrane does not call for a change in the plan of treatment. It usually disappears in from three to ten days. It is present only in the severer cases. Muco-purulent conjunctivitis never degenerates into true purulent conjunctivitis.

#### **What is purulent conjunctivitis?**

This is one of the most severe forms of inflammation of the conjunctiva. The term is used to designate the gonorrhœal form of conjunctivitis, which bears this name in the adult and is known as ophthalmia neonatorum in the infant. The period of incubation is about thirty-six to forty-eight hours; the disease runs a long and tedious course, frequently affecting the cornea, causing its destruction and the consequent loss of vision.

#### **What are the symptoms of purulent conjunctivitis?**

Occurring in the new-born, it first becomes noticeable to the parent in from two to three days after birth. The lids are slightly swollen and somewhat red, are glued together, particularly in the morning, and produce a rather thick, purulent secretion, which escapes from between them when they are separated. The child appears to experience but little pain at the outset. As the disease advances the conjunctiva and lids become much swollen, the purulent discharge becomes more plentiful and thinner, and the child loses its appetite and is restless and apparently in considerable pain. In many cases a haziness of the cornea appears, followed by ulceration and perforation, which frequently result in total destruction of the cornea and escape of the lens. The secretion gradually diminishes in quantity, the lids become of normal thickness, the conjunctiva returns to a normal condition, the globe shrinks, and recovery occurs with loss of vision. In those cases that recover without injury to the cornea the discharge gradually ceases and the normal state is regained.

#### **What are the symptoms of purulent ophthalmia, or gonorrhœa of the conjunctiva, as occurring in the adult?**

After the inception of the contagious principle slight irritation, refer-

able to the conjunctiva, and redness of this membrane are noticed by the patient. Lachrymation and a mucoid secretion follow in about twenty-four hours. At the end of forty-eight hours swelling of the lids, hypertrophy of the conjunctiva, and a purulent secretion are present. The height of the inflammatory trouble is reached about the end of the third day, at which time the amount of secretion is very great and the swelling of the lids pronounced. The secretion escapes from between the lids and runs down on the cheek in thin yellowish masses, and gives the individual an appearance characteristic of the disease and never to be forgotten when once seen. Destruction of the cornea in the manner described as occurring in ophthalmia neonatorum takes place here, but is usually more rapid. Pain is in proportion to the severity of the affection. Total destruction of the cornea, with complete loss of vision, occurs in probably one-third of all cases where treatment is not undertaken in the early stage of the disease, and is not carefully and judiciously carried out.

Pseudo-membrane is not an infrequent accompaniment of purulent conjunctivitis, and is usually found in the severer forms. All ages are subject to this affection, which is usually most severe in advanced life.

### **What is the cause of purulent conjunctivitis?**

Up to 1879 no specific *cause* for this condition was recognized, although it was known to be dependent in the adult on infection from gonorrhœal pus. In 1879, Neisser published his studies of the pathogenic micro-organism in gonorrhœa, and gave it the name of gonococcus. It is a double coccus, and can be readily found in all gonorrhœal pus. Purulent conjunctivitis in the adult and in the infant in probably every case occurring before the child has reached the age of three days is probably due to the entrance of the gonococcus into the conjunctival sacs. Other causes, indefinite in nature, have been mentioned as being instrumental in the production of purulent conjunctivitis, but they are scarcely worthy of consideration.

### **What is the treatment of purulent conjunctivitis?**

The *treatment* in ophthalmia of the new-born is *prophylactic* and *curative*. The prophylaxis consists in the thorough cleansing of the eyes of the infant at birth. Credé of Bonn introduced into the lying-in wards of his hospital the practice of instilling into the eyes of new-born infants one or two drops of a 2 per cent. solution of the nitrate of silver. This practice reduced the percentage of ophthalmia neonatorum occurring in the hospital with which he was connected from 13 per cent. to less than 2 per cent. Other accoucheurs are content to thoroughly cleanse the eyes with a solution of boric acid, salt, and water, or of the bichloride of mercury in the strength of 1:4000-5000. These measures suffice to reduce ophthalmia neonatorum to a relatively small percentage. Since the infection is obtained during the progress of the child through the

genital tract, the removal of the infectious material can be brought about with great certainty by the employment of these methods.

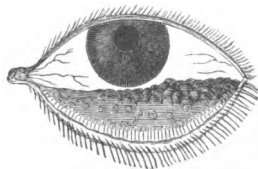
In the adult prophylaxis is of little avail except for the prevention of the communication of the disease from one eye to the other. Various devices have been employed for hermetically sealing the fellow-eye during the time of the treatment of the affected eye. It has been found, however, that in spite of hermetically sealing the eye infection has resulted, and those who treat many cases of gonorrhœal ophthalmia in the adult are accustomed to limit their prophylactic measures to occasional cleansing of the sound eye with antiseptic lotions, and employing great care to prevent the carrying over of secretion from the affected eye.

Treatment directed to the cure of purulent ophthalmia is similar in all cases. During the acute stage cold applications should be made continually, and the eye should be cleansed with some mild antiseptic lotion frequently enough to keep it fairly free from secretion. A solution of boric acid, 3 per cent., is admirably suited for this purpose. Frequent cleansing and cold applications should be continued throughout the acute stage. The application of astringents in the form of a 1-2 per cent. solution of the nitrate of silver, made thoroughly to the conjunctival surface once or twice daily, is advocated by many, and certainly gives excellent results in a certain proportion of cases. It is the custom of many oculists, however, to defer the employment of nitrate of silver until the subacute stage is established. In the making of cold applications care should be taken not to produce undue pressure on the lids and globe, as it is very easy to interfere with the nutrition of the cornea and cause it to slough. Careful nursing and the carrying out of these simple measures will do as much as can be accomplished by any form of treatment. Recently the use of vaseline, combined with boric acid, and employed to fill the conjunctival sacs in the intervals of cleansing, has been advocated, and has been found to answer admirably in a certain proportion of cases. Should ulceration of the cornea occur, atropine may be instilled, just as in ulcer of the cornea unaccompanied with purulent conjunctivitis.

### What is granular conjunctivitis ?

Granular conjunctivitis, which is also known as trachoma, is a condition in which the conjunctiva is studded with small elevations, discrete in the early stages, coalescing and forming large hard masses as the disease progresses. The lids become rough, and friction against the cornea produces ulceration, vascularity, opacification, and, in not a few cases, partial destruction of the cornea with loss of vision. It is contagious, affects all ages and classes, but is most commonly met with in children and in the uncleanly. It runs a very chronic course and shows little tendency to spontaneous recovery.

FIG. 5.



Granular Lower Lid (after Eble).

**What are the symptoms of granular conjunctivitis?**

They vary very much according to the case. In certain forms the patient experiences no inconvenience, and is scarcely aware of the presence of granulations in the conjunctiva until they have fully formed and eversion of the lid discloses a conjunctiva studded with sago-like bodies distributed throughout its entire surface. In the acute forms of trachoma the disease begins more as an acute conjunctivitis; redness and hypertrophy of the conjunctiva and moderate swelling of the lids are observed. Secretion of the muco-purulent type is plentiful. In the early stage the swelling of the conjunctiva may entirely hide the granulations, but as the disease progresses the swelling diminishes and the sago-like deposits become visible. The process is accompanied by much annoyance to the patient, consisting of a sensation as of a foreign body in the eye, pain due to friction against the cornea, and the swelling of the lid. In this form of trachoma the cornea is very apt to become involved and superficial ulceration ensues, with more or less vascularity of the surface of the cornea—a condition known as pannus. Photophobia or dread of light is present, and the patient's life is rendered miserable.

**What are the causes of granular conjunctivitis?**

Trachoma usually appears among the lower classes, in whom the sanitary conditions are very poor and cleanliness is not observed. The researches of Sattler and of Michel make it extremely probable that trachoma is of microphytic origin. But their researches have not been verified to a sufficient extent to make the proof positive. The instillation of medicated solutions sometimes produces trachoma. This is particularly true of the long-continued use of solutions of atropine that have stood for some time and have become stale. The treatment of this particular form of trachoma is as in the forms from other causes. It usually responds to treatment, and recovery takes place in a relatively short time.

**What is the treatment of granular conjunctivitis?**

The *treatment* may be considered under two heads, medical and surgical. The medical treatment of trachoma consists in cleanliness secured by bathing the eye with salt and water or a solution of boric acid, and of applications to the conjunctival surface of a crystal of sulphate of copper, of alum, or of the pure or mitigated stick of nitrate of silver. Solutions of nitrate of silver, acetate of lead, and sulphate of zinc are also employed. When ulceration of the cornea exists, atropine and other medicinal substances used in ulcer of the cornea from other causes may be employed. Applications of copper, alum, or silver are made in the following manner: The lid is everted and the smooth crystal is passed quickly and gently over the diseased surface, care being taken to reach every part. After the application is made it is well to brush water over the surface.

In cases where the vascular pannus is marked an infusion of the

jequirity bean has been employed to produce a violent inflammatory condition of the conjunctiva for the purpose of curing the granulations and of clearing up the pannus. The infusion is made in the following manner: 3 grammes of the bean are pulverized and permitted to macerate in 500 cc. of water for twelve or twenty-four hours. To this is added 500 cc. of hot water, and the infusion is filtered. The application is made by everting the lids and brushing the solution freely over the conjunctival surface. This is repeated every twenty-four hours for two or three days, until an inflammation of sufficient height has been produced. The pulverized bean is dusted on the conjunctival surface for the purpose of exciting the inflammatory reaction by some oculists, with the same result as when the infusion is used.

The surgical treatment of trachoma consists in removing the contents of the granules by expression or by excising the fornix folds. For the removal of the contents of the granules forceps have been devised with which the folds of conjunctiva are squeezed, and by a stripping motion the contents of the follicles are forced out. The forceps used by Noyes and those devised by Knapp are among the most popular for this purpose. The treatment of trachoma by expression is applicable to the first stage of trachoma, that stage where the granules are still discrete. After the squeezing process the conjunctiva should be brushed with a solution of the bichloride of mercury, 1 : 500 or 1 : 1000. The after-treatment consists in keeping the eyes clean by frequent bathings with some mild antiseptic lotion, and by the employment of mild astringents, as may seem necessary. For the treatment of the second stage of trachoma scarification should be combined with squeezing, and the use of the bichloride solution should be carefully carried out. Destruction of individual follicles by means of the galvano-cautery point is employed by some.

### **What is phlyctenular conjunctivitis?**

This is a form of conjunctivitis characterized by the development of small conical vesicles on the conjunctiva of the globe, usually occurring near the margin of the cornea. They first appear as red points, soon become vesicular, and eventually contain pus: they break down and form small superficial ulcers. Considerable irritation of the conjunctivæ in the vicinity of the vesicles is always present. If the phlyctenulæ affect the conjunctiva only, there is usually little photophobia and the patient experiences but little annoyance. However, as soon as they invade the cornea pain and photophobia become prominent symptoms.

### **What are the causes of phlyctenular conjunctivitis?**

This disease is unquestionably analogous to eczema of the skin. It is dependent on infection of the conjunctiva, the presence of the vesicles and of the pustules in all probability being due to the entrance of the staphylococcus pyogenes beneath the epithelium of the conjunctiva. The disease usually occurs in children of the so-called strumous diath-

esis, and is almost always accompanied with an eczematous eruption about the head or face. It is not identical with herpes, which disease depends upon derangement of nerve-terminals, usually from the fifth cerebral.

### **What is the treatment ?**

Since in this disease the constitutional condition is usually much below par, it is necessary to employ tonic remedies and to place the patient in good hygienic surroundings in order to more rapidly effect a cure. The *local treatment* consists in observing cleanliness and in the use of some medication, such as the yellow-oxide-of-mercury ointment rubbed into the eye once or twice daily.

### **What is diphtheritic conjunctivitis ?**

Probably the most rapidly-destructive form of conjunctivitis is the diphtheritic. Its onset is sudden, and destruction of the cornea may occur within forty-eight hours after the first evidence of the disease is manifest.

### **What is the cause of diphtheritic conjunctivitis ?**

Diphtheritic conjunctivitis is undoubtedly due to infection from the Löffler bacillus, as is the case in diphtheria of the pharynx. In the majority of cases the infection is primary in the conjunctiva, but in a certain proportion of cases the disease is communicated to the conjunctiva from the nose in cases of diphtheria of the nose, either by way of the tear-passages or indirectly by some other medium. Diphtheria of the conjunctivæ is seldom found as a complication of diphtheria of the pharynx.

### **What are the symptoms of diphtheritic conjunctivitis ?**

Soon after the infection the conjunctivæ become red, the lids swell rapidly, and the patient experiences quite severe pain referable to the eye. But little secretion other than a free flow of tears is at first observed. After the end of twenty-four hours a false membrane begins to appear, the lids become greatly thickened, and so distended by the presence of a fibrinous exudation into the loose tissue of the lid that the skin becomes tightly stretched and glistening. It assumes a purplish hue. At this stage the pain is intense and it is quite impossible to evert the lids. On holding the lids from the globe the conjunctival surface is found covered with a thin pseudo-membrane, which extends well up into the fornix, and eventually passes on to the ocular conjunctiva. The pressure on the cornea from the thickened lids soon causes it to become hazy, and sloughing rapidly takes place. As the disease progresses the pseudo-membrane becomes thicker and of a dirty-yellow color. It is firmly attached, and leaves a bleeding surface when removed. When recovery advances the membrane separates, leaving a swollen granular conjunctival surface: the secretion assumes more of a purulent nature, and gradually disappears.

**What is the treatment for diphtheritic conjunctivitis ?**

Cold applications should be constantly applied from the very first, and the eye should be kept as clean as possible by frequent bathing with a solution of boric acid. Should the pressure of the lid be so great as to threaten the integrity of the cornea, a free canthotomy may be made, or the lid may be split through its centre to the depth of the conjunctival cul-de-sac. As the swelling is reduced and the membrane softens, the membrane should be gently removed and applications of a 1 per cent. solution of silver nitrate made to the conjunctival surface every twenty-four hours. The applications of cold should be continued until the swelling becomes much reduced. Resolution may then be hastened by the use of hot applications. This treatment may be continued until the parts assume a normal condition.

**What is spring catarrh ?**

This is a peculiar form of disease, rarely met with in this country, in which the cornea becomes partly or wholly surrounded by an elevated, fleshy mass which encroaches to a slight extent upon its margin. This elevation is usually smooth, but may be somewhat nodular. It is accompanied by a roughened condition of the conjunctivæ of the lids. The process is unaccompanied by severe pain. There is little secretion. It is supposed to depend on a specific cause, but this cause has not yet been determined. The disease is very persistent, recurring in the same person year after year. It is worse in the summer, and almost entirely disappears in the winter months.

**What is the treatment ?**

The *treatment* is very unsatisfactory. Remedies that appear to favorably influence other forms of conjunctival inflammation have no apparent effect upon this. The use of astringents and the careful observance of cleanliness will aid in keeping the disease in abeyance. Applications of the galvano-cautery appear to produce favorable results.

**What is pterygium ?**

Pterygium is a condition of hypertrophy of the conjunctiva occurring usually at the inner side of the cornea, and often encroaching upon it to such an extent as to almost entirely cover the pupil. It is wedge-shaped, the apex being directed to the cornea, its base corresponding to the caruncle.

**What is the cause of pterygium ?**

Pterygium is undoubtedly due to long-continued irritation of that portion of the conjunctiva which is most commonly exposed to infection from without—namely, that portion opposite the palpebral fissure. It springs usually from a preceding pinguicula and extends forward on to the cornea. It is most common in men, occurs always on the inner side of the cornea at first, and may subsequently appear on the temporal side.



**What is the treatment of pterygium ?**

This consists in excision. A number of methods for the removal of pterygium are in vogue. Simple excision is performed as follows: The pterygium is grasped by the fixation forceps at a point about two lines from the margin of the cornea; a knife—usually a Beers cataract knife—is made to pass beneath the tissue of the pterygium with the cutting edge directed toward the cornea. The pterygium is then carefully dissected from the cornea, often a thin piece of the corneal tissue being removed with it. With the scissors a wedge-shaped piece of the subjacent hypertrophied tissue is then dissected off, its apex reaching the caruncle and its base being near the cornea. The conjunctival edges of the wound are then brought into apposition by the use of sutures, a compressed bandage is applied, and the patient dismissed. Healing occurs rapidly.

The method of transplantation is largely employed. It is performed as follows: The apex of the pterygium is dissected from the cornea as above. An incision is then made through the ocular conjunctiva from the first wound into the lower cul-de-sac. The point of the pterygium is turned downward into this incision and stitched into the lower cul-de-sac. The margins of the wound are then brought into apposition.

**What is a pinguicula ?**

A pinguicula is a little yellowish elevated mass which appears in the horizontal meridian of the globe to the nasal side of the cornea, situated in the conjunctivæ, usually about two lines from the free margin of the cornea. It is made up of connective tissue, elastic and non-elastic. It is usually the forerunner of pterygium, but calls for no special treatment.

**What is amyloid degeneration of the conjunctiva ?**

This rare form of disease of the conjunctiva consists in the development of translucent swellings appearing in the conjunctival tissue, the ocular conjunctiva being first affected. They consist of corpuscles and trabeculæ, with numerous nuclei in a liquid matrix contained in a limiting membrane; the corpuscles and trabeculæ give a strong amyloid reaction to iodine and sulphuric acid. The condition is local and unaccompanied by pain.

**What is xerosis of the conjunctiva ?**

Xerosis of the conjunctiva is of two varieties: First, that form of dryness of the conjunctiva resulting from atrophy following trachoma. The cornea becomes cloudy and opaque and vision is much interfered with. In the second form complete dryness is not present. This condition appears usually in poorly-nourished individuals, and is characterized by the occurrence on the conjunctiva of white foamy masses of an oleaginous or greasy nature. The patches appear in adults as small triangular masses at the margin of the cornea in the horizontal meridian, and the disease has been given the name of xerosis triangularis because of the

form assumed. In infants the foamy masses usually first appear in the folds of the lower cul-de-sac, and as the disease progresses it covers the whole conjunctiva. In infants it is known as xerosis infantilis. It always affects infants with marasmus, and appears always to end fatally. In the adult the disease is frequently accompanied by night-blindness.

#### **What are the causes of xerosis?**

It was supposed by Graefe that the disease was dependent on a cerebritis, particularly in infants, and this view was partly confirmed by researches into the condition of the brain conducted by Virchow. Later writers have recognized the association of bad food, confinement, and bad hygienic surroundings in this disease, and claim it to be dependent upon these and on mal-assimilation of food. Laber described a bacillus which is constantly found in the frothy secretion, and which he claims to be the pathogenic principle. This claim has not been verified by others. It is now generally believed that the condition of the tissues favors the growth of this micro-organism, and that it would not exist if the system were restored to the normal condition.

#### **What is the treatment for xerosis?**

When occurring in infants *treatment* is of little avail. In adults, since the secretion is of an oily nature, saponifying remedies should be employed to cleanse the affected portions. Applications of strong antiseptics may then be made, either in watery or in oleaginous menstrua. The thickened mass is first scraped away, the saponifying remedy applied, and the antiseptic used subsequently. Recovery is slow, but may be much hastened by change of air and of diet.

#### **What is subconjunctival hemorrhage?**

As the name implies, it is the escape of blood beneath the conjunctiva. It usually occurs beneath the ocular conjunctiva as the result of a blow or of strain in coughing or at stool, or from some violent exercise. It produces a peculiar deep-red patch, which may partly or wholly surround the cornea.

The *treatment* is expectant, and by the use of hot applications to hasten absorption.

#### **What is tuberculosis of the conjunctiva?**

Tubercular infection of the conjunctiva is of rare occurrence. It is not infrequently termed lupus, and is probably identical with that condition. Direct infection of the conjunctiva may occur, but it more frequently happens that the disease is communicated to the conjunctiva by way of the lachrymal passages from the nose in tuberculosis of the nasal mucous membrane. In the early stage isolated nodules resembling trachoma-follicles appear usually upon the palpebral conjunctiva, but also at times on the ocular. These nodules break down and form superficial ulcers. The disease advances slowly.

Excision and the use of the galvano-cautery are the means employed in the *treatment* of this condition.

## THE CORNEA.

### What is the structure of the cornea?

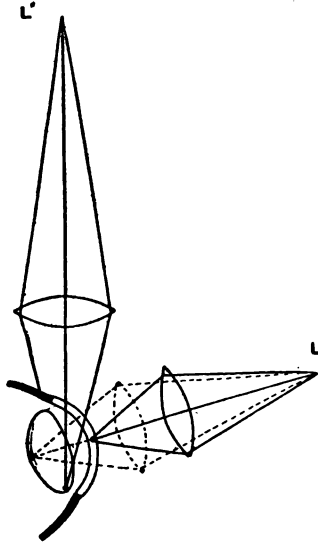
The cornea is a clear, transparent membrane forming a portion of the anterior segment of the fibrous coat of the eye. Its radius of curvature is shorter than that of the sclerotic, and the cornea consequently extends a little in advance of the curvature of the sclerotic. It is composed, from without inward, of an epithelium layer of the stratified variety placed on a basement membrane known as Bowman's membrane. Bowman's membrane is a thin, finely fibrillar layer which under ordinary powers of the microscope appears homogeneous. These two layers are continuous with the conjunctiva. Beneath Bowman's membrane is the *substantia propria* of the cornea. This is much the thickest layer of the cornea, and consists of bundles of connective tissue arranged in lamellæ placed parallel to the surface of the cornea. These lamellæ are bound together by a cement-substance. Penetrating the cement-substance in every direction are small canals, presenting at their intersections spaces known as lacunæ. This system is known as the canalicular lymph-system of Recklinghausen. They afford opportunity for the passage of the nutrient fluids from the periphery to all parts of the corneal tissue. The lacunæ give lodgment to large branching cells, the fixed cells of the cornea. Each cell occupies but a portion of a lacuna. The branches of the cell pass into the small canals and anastomose with branches of adjoining cells. The lymph-spaces also give passage to the nerve-filaments. The *substantia propria* of the cornea passes into the sclerotic. Posterior to the *substantia propria* is the thin homogeneous elastic membrane known as *Descemet's membrane*. This membrane is lined posteriorly by a single layer of hexagonal cells, the endothelium of the cornea. *Descemet's membrane* breaks up at the periphery of the cornea into the *ligamentum pectinatum*. This ligament passes back to the ciliary body and forms a portion of the root of the iris. The spaces between the meshes of the *ligamentum pectinatum* are lymph-spaces, and are in free communication with the lymph-system of the cornea. The cornea is devoid of vessels, but is very rich in nerves. Its nerve-supply is derived from the ciliary nerves. The nerve-trunks, twenty or thirty in number, pass into the cornea from the periphery into its deeper layers, where they form a plexus from which the radial bundles pass toward the surface of the cornea, breaking up into a finer plexus at the base of the epithelial layer. From this plexus the terminal filaments pass upward into the epithelium.

### What is meant by the method of examining the cornea by oblique illumination?

This method, which affords the best means of examining the cornea,

is conducted as follows: The source of light, an Argand burner, candle, or incandescent lamp, is placed slightly in front of the patient and to the side, at a distance of 1 metre and at an angle of about  $35^{\circ}$  to the plane of the face, and about on a level with the eyes. A lense having a focal distance of about 3 inches is interposed between the source of light and the cornea to be examined, in such a way as to focus the light on the

FIG. 6.



Focal Illumination.

part to be examined. The observer places himself in front of the patient, and by focusing the light as above described is enabled to determine with great distinctness the condition of the cornea in all its parts. This method of examination is also applicable to the iris and lens.

#### **What inflammatory conditions is the cornea subject to?**

Superficial, parenchymatous, phlyctenular, vascular, suppurative, and ulcerative keratitis.

#### **What is superficial keratitis?**

This form of inflammation of the cornea is frequently dependent on the presence of some irritating substance in the lids or on the friction of

the roughened lids against the cornea. It affects, as the name implies, only the superficial layers, and is usually of transient duration. There is a form of superficial keratitis which, beginning at the periphery of the cornea as a shallow depression with a whitish margin, advances over the cornea in its superficial layers, progressing slowly, causing some pain and much photophobia, and gradually involving the greater part of the surface of the cornea. This form of keratitis is undoubtedly due to infection.

#### **What is the treatment of superficial keratitis ?**

Where the cause can be ascertained it should be removed. Bathing of the eye with a solution of boric acid and the instillation of a solution of the bichloride of mercury, 1 : 10,000, every two or three hours, combined with the use of a solution of atropine in cases where iritis threatens, will usually suffice to promote a cure. In individuals of low vitality, tonics, and possibly change of air, must also be advised.

#### **What is parenchymatous keratitis ?**

This condition consists in infiltration of the deep layers of the cornea with small cells, producing more or less marked opacification of the cornea without passing on to the production of pus.

#### **What are the symptoms of parenchymatous keratitis ?**


The patient experiences slight pain at the outset, with marked dread of light. Vision becomes impaired. At first a very thin grayish film may be detected in the deeper layers of the cornea by examination with oblique illumination. This opacification increases gradually, remaining of a whitish, pearly tint in the mild cases, becoming dense and yellowish in severer cases. Examination with the magnifying-glass shows the cornea to be traversed by minute blood-vessels. In certain cases the vascularity is sufficiently marked to produce the so-called salmon patches of the cornea. The disease is very slow in its nature, requiring from six months to a year and a half to run its course. Some residue of the opacity is almost always left, and, in the cases where dense opacification includes the whole cornea, vision is permanently much impaired.

#### **What are the causes of interstitial or parenchymatous keratitis ?**

This disease owes its origin in almost every case to inherited syphilis, as has been clearly and forcibly demonstrated by Jonathan Hutchinson. In some cases heredity cannot be traced, but it probably exists. There are associated with this condition certain characteristic signs in other parts that go to complete the picture. The face is usually narrow in its lower half, the skin wrinkled, and the lips drawn or puckered. On examining the teeth a peculiar condition is apt to be found. The upper incisors are generally the ones most affected. They are narrow, placed apart from each other, round, peg-shaped, and notched at their extremities. Often the teeth decay early in life and stumps only remain. The palatine arch is frequently narrow and deep. Enlargement of the cervical and submaxillary lymphatic glands is often noticed. Parenchymatous

keratitis is most frequently observed in childhood between the ages of eight and fifteen, but may occur much earlier, and has been observed as

FIG. 7.



Syphilitic Teeth.

late as the thirty-fifth year. Although almost always due to hereditary syphilis, rare instances are on record of its occurring in individuals who have had primary sores.

### **What is the treatment of parenchymatous keratitis ?**

The *treatment* is local and general. The local treatment consists in the use of atropine and bathing of the eyes in hot water. They should be protected from bright light to prevent the annoyance that light occasions. This may be done by the use of dark glasses or by keeping the patient in a darkened room. The ointment of the yellow oxide of mercury may be introduced into the eye from time to time with beneficial results. It is a recognized fact that wherever vascularity can be induced the grayish patches will clear up to the greatest extent. The object of the treatment is therefore to stimulate the development of vessels in all portions of the cornea. The internal treatment should consist in the administration of mercury and of iodide of potassium in small, continued doses. Cod-liver oil and the syrup of the iodide of iron will be found valuable, taken internally, in their effect on the general system.

### **What is phlyctenular keratitis ?**

Phlyctenular keratitis resembles very closely the affection by that name which occurs in the conjunctiva. The phlyctenulæ first appear on the cornea in the shape of small elevated vesicles, usually connected with the conjunctiva by a number of minute vessels. As the disease progresses the vesicles are found to contain pus, and break down and form small ulcers. This affection in the cornea is quite painful and produces marked photophobia. In certain cases after a vesicle has broken down another appears, slightly in advance of the first, being also connected with the periphery by a leash of small vessels. This process may continue until a narrow path has been formed across the cornea. The process may stop short at any point, but leaves a whitish line to mark its track. Phlyctenular keratitis is not identical with herpes of the cornea.

### **What are the causes of phlyctenular keratitis ?**

The same *causes* are at work in the production of phlyctenular keratitis as are instrumental in the production of phlyctenular conjunctivitis. It is analogous to eczema of the skin, and is termed by some authors eczema of the cornea.

**What is the treatment of phlyctenular keratitis ?**

It occurs usually in children whose general condition is somewhat run down. Tonics should be employed, in connection with good food and good sanitary surroundings, to build up the health of the individual. Frequent bathing with a mild antiseptic solution and the introduction of the yellow-oxide-of-mercury ointment into the eye once or twice daily will suffice to promote a cure. In cases where deep ulcers of the cornea exist atropine may be employed with benefit.

**What is vascular keratitis ?**

Vascular keratitis, frequently termed *pannus*, usually accompanies trachoma, and is the result of friction on the cornea by the roughened lids. The vascularity affects the superficial layers of the cornea. Vessels appear, advancing from the periphery, and pass just beneath the epithelium, rendering it uneven. These increase rapidly in number, and may eventually form a red, fleshy-appearing surface over the entire cornea. Vision is very much impaired, and in some cases almost completely abolished. Frequently the vascularity will disappear if the roughness of the lids is corrected. In many cases not a trace of the previous vascularity can be determined, but in the majority of cases a residue remains which permanently interferes with vision.

**What is the treatment of vascular keratitis ?**

Removal of the cause which has produced the vascularity will, in the greater number of cases, suffice to bring about a cure. In severe cases an operation may be performed which has for its object the cutting off of the blood-supply to the vessels on the cornea. This operation is known as peritomy or syndectomy. It consists in dissecting up a narrow strip of the conjunctival and subconjunctival tissue about the whole circumference of the cornea. Instead of dissecting, the galvano-cautery may be employed for the same purpose. The narrow electrode may be passed entirely round the cornea, burning sufficiently deep to destroy all vessels that pass on to the corneal surface. These operations suffice to aid materially in clearing up dense vascularity of the cornea. It has been the practice of some operators to use the crystal of the sulphate of copper in these cases, applying it directly to the corneal surface.

**What is suppurative keratitis ?**

Suppurative keratitis is a term employed to designate a condition of the cornea in which there is a loss of substance from ulcerative processes and the formation of pus between the lamellæ of the cornea, which frequently finds its way into the anterior chamber. When suppurative keratitis is extensive it produces a condition of softening of the cornea known as *keratitis malacia*. Many authors describe a condition of abscess of the cornea. It is, however, doubtful whether true abscess of the cornea ever exists. Probably some opening to the surface is present in all these cases.

**What are the causes of suppurative keratitis?**

This is usually due to the inception of some infectious material, as wound of the cornea by the finger-nail, a piece of oyster-shell, a stalk of hay, or some germ-carrying object. These cases are of rather frequent occurrence among farmers and fish-dealers.

**What is the treatment of suppurative keratitis?**

The *treatment* of this condition is, on the whole, rather unsatisfactory. Antiseptic lotions—principal among which is the bichloride of mercury—should be used freely to promote as thorough disinfection of the parts as is possible. Atropine should be employed to prevent iritic adhesions, as in this form of keratitis iritis is a frequent complication. If the pus has entered the anterior chamber and is there accumulating—a condition known as *hypopyon keratitis*—a free paracentesis should be performed, permitting of the escape of pus, and the anterior chamber should be washed out as thoroughly as possible either with a very weak solution of the bichloride of mercury or a solution of boric acid.

**What is ulcerative keratitis?**

The term is one given to designate the loss of corneal tissue from all causes aside from traumatism. (An injury to the cornea produces a superficial defect in the corneal tissue, the walls of which are usually clean. This is known as *simple traumatic ulcer* of the cornea.) If the walls of a corneal defect are clear, the condition is known as *simple ulcer* of the cornea. When the walls of the defect assume a grayish appearance and the gray infiltration extends into the corneal tissue, the condition is known as one of *infiltrative* or *infectious ulcer* of the cornea. In some cases the grayish infiltration, with a defect in corneal tissue, appears at the margin of the cornea, extending along its periphery. The shape of this ulcer causes it to be known as a *crenate ulcer* of the cornea. In other cases a grayish infiltration appears in the corneal tissue immediately beneath the epithelium, extending in zigzag lines over a portion of the cornea, causing loss of epithelium eventually in all parts of its course. Its shape gives it the name of *serpentine ulcer* of the cornea. Ulcers are also known as *superficial* or *deep* according as they affect the superficial or deep layers.

**What are the symptoms of ulcer of the cornea?**

In advancing ulceration of the cornea pain, referable to the eye and to the parts subjacent, is more or less intense, usually being more severe when the superficial layers of the cornea, the epithelium in particular, are being destroyed. Photophobia is a marked symptom. The iris is frequently involved, and, when it is, pain, referable to the side of the head, is a prominent feature. The patient is unable to use his eyes.

**What is the treatment of ulcerative keratitis?**

In the early stage of infected ulcer, when but little destruction of tissue has ensued, it is advisable to destroy all of the tissue involved by use



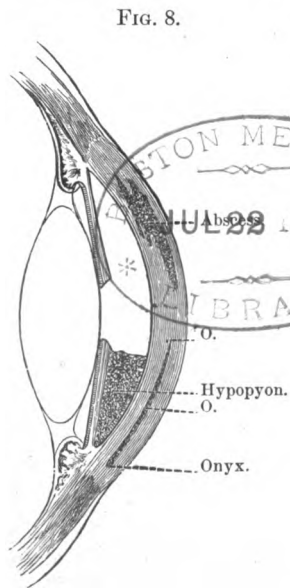
of the galvanic cautery. In cases where this is not applicable, frequent instillation of an antiseptic lotion should be used, in connection with atropine, to prevent adhesions between iris and lens. In cases where pus enters the anterior chamber and shows a tendency to accumulate, paracentesis of the anterior chamber is advisable.

### What is meant by the term "onyx" in ulcer of the cornea?

When pus is produced, accompanying ulceration of the cornea, it sometimes occurs that the pus infiltrates between the lamellæ of the cornea, and, gravitating to its most dependent portion, forms a patch in appearance somewhat like the lunule at the base of the finger-nail. This has given the condition the name of "onyx."

### What is meant by the term "hypopyon keratitis"?

When in ulceration of the cornea pus has found its way into the anterior chamber, or when during iritis a purulent deposit is formed in the lower part of the anterior chamber, the condition is termed hypopyon. In the treatment of ulcers of the cornea where hypopyon exists it often becomes advisable to make an incision through the cornea, forming paracentesis, for the purpose of evacuating the pus (Fig. 8). The operation devised by Sämisch is also applicable in these cases. It consists in making a free incision, usually through the ulcer, and evacuating the purulent lymph contained in the anterior chamber.



Vertical Section through Anterior Part of Globe (diagrammatic).

### What are some of the results of ulcerative and suppurative keratitis?

Following ulcerative keratitis as a direct result, perforation of the cornea not infrequently occurs. The anterior chamber is evacuated, the iris is pushed forward into the opening, and in some cases where the loss of corneal substance is extensive, the lens capsule is ruptured and the lens escapes. As the suppurative process runs its course and is in process of healing, the opening gradually closes by the formation of cicatricial tissue, and an opacity takes the place of the site of the ulcer. Where perforation has ensued there is, in the majority of cases, an inclusion of the iris in the

cicatrix following. The opacity resulting from ulceration without incarceration of the iris is known as simple *leucoma*. Where the iris is included in the cicatrix the condition is known as *adherent leucoma*, and the iritic adhesion to the cornea produces the condition of *anterior synechia*, which may be partial or complete. Following the ulcerative or suppurative processes in the cornea we may have cicatricial formations, including almost the entire cornea. The new-formed tissue often presents insufficient resistance to the intraocular tension, and bulges in the weak parts, forming what is known as *staphyloma* of the cornea. This is known as *partial* when but part of the cornea is involved, and is *complete* when the whole cornea bulges forward.

### **What is the treatment of leucoma of the cornea ?**

In the early formation of leucoma some benefit may be derived from the employment of various agencies for promoting the clearing up of the opacity. Hot fomentations, and at times the application of calomel or of ointments, may be of some benefit. When the leucoma is of long standing but little can be done to reduce the opacity in extent or density. Where the centre of the pupil is covered by the cicatricial tissue, if some clear portion of the cornea remains, vision can usually be greatly improved by the making of an iridectomy in the portion corresponding to greatest corneal transparency. This applies as well to simple as to adherent leucoma. In certain cases of adherent leucoma symptoms of *glaucoma* supervene which will be relieved only by the making of an iridectomy.

### **How is the operation of iridectomy performed ?**

The operation may be done with cocaine anæsthesia, but, because of some pain which almost always accompanies the operation when cocaine alone is used, ether must be given in a certain portion of the cases. The patient is placed either in an operating chair or on the table, the operator standing behind the patient's head. The eye and surrounding parts are thoroughly cleansed by washing the skin with soap and water, and the skin and conjunctival sac with an antiseptic solution, preferably solution of bichloride of mercury, 1 : 5000 or 1 : 10,000. A stop speculum is then introduced between the lids. An incision is then made through the cornea, after fixing the eye with fixation forceps, either with the keratome or Graefe knife, usually a little back of the clear margin of the cornea at the point selected. Care must be taken not to wound the iris or lens. The fixation forceps are then transferred to an assistant, and the curved iris forceps introduced through the wound into the anterior chamber with the blades closed. The blades are then permitted to open, and a firm hold is taken on the iris near its free margin. It is then gently withdrawn and a piece cut off with a small iris scissors. The remnant of the iris is then restored to the anterior chamber by means of a small spatula, the margins of the wound adjusted, the speculum removed, and

the eye bandaged. Recovery from such an operation takes place in from five to ten days.

### **What is the treatment for staphyloma of the cornea ?**

When staphyloma is in its very early stage, and is partial, it may be frequently aborted by means of iridectomy. In the advanced stage, or when it involves nearly all of the cornea, iridectomy is of no avail. The protrusion must then be excised or the eye enucleated. Excision of the staphyloma is done in various ways by different operators. A common method is to pierce the staphyloma at its base with a Graefe knife, and cut it off at the sclero-corneal margin. Before the protrusion is excised sutures are so placed through the conjunctiva and episcleral tissue that the opening may be somewhat closed afterward. The lens is usually evacuated and the sutures tied. After such an operation healing takes place gradually, and a shrunken stump is the result, suitable, however, to bear an artificial eye.

### **What is the operation for tattooing the cornea ?**

This consists in changing the color of the scar-tissue from white to black in the portion corresponding to the pupil. It is performed under anæsthesia with cocaine. A stop speculum is introduced, and india ink in the form of fine powder or a thick paste is spread over the part to be colored. Then with an instrument consisting of a number of needles placed closely together the cornea is punctured in an oblique direction over the area to be tinted. This process is continued until the desired degree of color is obtained. At times it is necessary to repeat the operation. The reaction attendant upon this operation is usually slight. In some cases it is quite severe. The operation, however, is comparatively harmless. It is done for the cosmetic effect only.

### **What deposits take place in the corneal tissue ?**

Metallic and chalky deposits. The metallic deposits usually observed are those of the carbonate of lead, which forms a white, densely-opaque mass. It results from the employment of solutions of the acetate of lead in the eye when ulcer of the cornea is present. A deposit of chloride of silver is sometimes formed as a result of the use of strong solutions or the crystal of nitrate of silver in treating corneal ulcers, followed by the instillation of solutions of the bichloride of mercury. In some cases of chronic superficial keratitis observed in trachoma chalky deposits are found. In the form of keratitis known as "ribbon-shaped keratitis" chalky deposits are frequently present.

### **What is the treatment of deposits in the cornea ?**

The most favorable results are obtained by scraping and by excision. The eye is anæsthetized with cocaine, the lids held apart by a speculum, and the cornea scraped by means of a small, sharp curette. The deposit is carefully removed and a compress bandage placed over the eye. Excision

of the deposit is effected by the use of a Beers or of a cataract knife. The knife is passed through the superficial layers of the cornea beneath the deposit and the deposit carefully excised. Atropine is instilled and the eye bandaged. Healing usually progresses rapidly.

#### **What is conical cornea ?**

It consists in the bulging forward of the central portion of the cornea, forming a cone the base of which corresponds to the periphery of the cornea, the apex to the centre of the cornea. The cone is transparent. A high degree of myopia in the centre of the cornea is produced by this condition.

#### **What is the treatment of conical cornea ?**

Because of the conical shape of the cornea vision is very imperfect, and it is difficult to adjust glasses that will be of much benefit to the patient. It is therefore desirable to restore the normal curvature of the cornea. Various methods of operating have been devised for this purpose. An operation which has given beneficial results is that of removing a small circular piece of corneal tissue from the apex by the use of a small trephine. After the piece has been punched out the cornea heals with a small central cicatrix, and the conical curve of the cornea is very much reduced. This operation was devised by Bowman. Another operation is to excise an oval piece of the cornea at the apex. This is also attended with very good results. Other operators have succeeded by the use of the galvano-cautery in cauterizing the apex of the cone, with good results in the improvement of vision.

#### **What forms of tumor is the cornea subject to ?**

Epithelioma, sarcoma, and dermoid tumors are sometimes met with on the cornea. The form of epithelioma closely resembles that met with in other parts of the body. Sarcoma, when it exists, is usually subsequent to sarcoma in other parts of the eye or is communicated from the lids or orbital tissues. Dermoid tumors are congenital in their origin, presenting the ordinary tissues of dermoid tumors in other parts of the body; that is, they present the formation of skin by hair-follicles and glands, and are sometimes pigmented.

#### **What is the treatment of tumors of the cornea ?**

Excision should be employed where practical. In cases of epithelioma it is advisable to cauterize the base of the tumor after thorough excision has been practised.

#### **What is the treatment of lacerated wounds of the cornea ?**

As a rule, in lacerated, non-perforating wounds of the cornea all that is required is careful cleansing of the eye and the application of a protective bandage. In some cases where iritis is feared it is advisable to instil atropine into the eye. In perforating wounds the iris is frequently involved. It prolapses or is incarcerated in the wound. Excision of the

protruding part of the membrane should be practised in every recent case. Atropine should be instilled, the margins of the wound adjusted as perfectly as possible, and after thorough cleansing with an antiseptic solution a compressed bandage should be applied.

#### **Are foreign bodies in the cornea met with?**

They are, and are of very frequent occurrence and of all varieties. Particles of coal and iron are most frequent.

#### **How are foreign bodies in the cornea detected?**

The patient often comes with the complaint that he has a foreign body under the upper lid. In all such cases, if on eversion of the upper lid the foreign body is not discovered, the cornea should be carefully examined by the use of the oblique method. The minutest particles can be detected in this manner and their removal effected.

#### **What is the treatment of foreign bodies in the cornea?**

The offending particles should be removed at the earliest possible time. A drop of cocaine is instilled, and after the cornea has become anaesthetic the particle is raised from its bed by the use of a spud or of a foreign-body needle, the surfaces of the depression produced thoroughly cleansed, and a solution given with which to keep the eye in an aseptic condition until the wound produced by the foreign body and by the efforts in its removal has healed.

#### **What forms of burns of the cornea are met with?**

Burns by powder, by acids, by lime and other alkalies are not uncommon. Burns by powder often produce defects which interfere with vision, but the presence of the remains of powder-grains in the cornea are of no particular danger or significance except when they occupy the pupillary area. Burns with acids leave usually but little opacity. Burns from quicklime and from other alkalies are very apt to cause dense opacities, which even without destruction of the cornea make vision almost impossible. The opacity produced by lime usually becomes much more dense some weeks after the injury has been received than is evident at the time or a few days afterward. The entrance of molten lead or iron into the conjunctival sac frequently produces but little injurious result.

#### **What is the treatment of burns of the cornea?**

In burns from powder as much of the substance of the powder-grains as possible should be removed. The use of a boric-acid solution to prevent infection should be employed. Healing under these conditions usually progresses favorably. In the case of a recent inception of acid the conjunctival sac and corneal surface should be thoroughly washed with some alkaline solution: a solution of bicarbonate of sodium is very excellent for this purpose. In the case of the inception of ammonia the eye should be well washed out with clean water to which a very few drops of acetic acid or of vinegar are added. In burns from

lime care should be taken to carefully cleanse the lids, to remove all particles of lime: a solution of boric acid may be employed for this purpose, and a 10 per cent. ointment of boric acid should be given to the patient to be stuffed into the eye at relatively frequent intervals. In addition to this, a solution of atropine may be employed to produce dilatation of the pupil and prevent adhesion should iritis threaten. Precaution must be taken to prevent adhesions between the cornea and conjunctivæ in cases where the conjunctival tissue is also injured. These may be prevented by passing a probe frequently between the conjunctiva of the globe and of the lids to break up any adhesions that may be in process of formation.

## THE SCLEROTIC.

### What is the sclerotic coat of the eye?

It is the white outer membrane of the ball of the eye which, in connection with the cornea, forms the fibrous coat of the eye. It is very strong and inelastic, and serves to retain the form of a globe by its resistance to the intraocular pressure. It forms the surface of a sphere having a radius of about 12 mm. Anteriorly it is continuous with the tissues of the cornea. At this point it measures about 1 mm. in thickness; 6 to 8 mm. back of the sclero-corneal margin it measures about  $\frac{8}{10}$  mm. in thickness. It becomes slightly thicker as it approaches the posterior pole of the eye, and in the vicinity of the optic nerve it reaches about  $1\frac{2}{10}$  mm. in thickness. It gives attachment to the tendons of the extrinsic muscles of the globe. At the equator of the globe the sclerotic is pierced by four openings which give passage to the *venæ vorticosæ*. A little to the inner side of the posterior pole of the globe there is a circular opening through the sclerotic which is crossed by bands of connective tissue, forming a sieve-like opening known as the *lamina cribrosa*. This measures about 2 mm. in diameter, and gives entrance to the nerve-bundles of the optic nerve and to the principal vessels of the retina. Encircling and near the optic nerve the sclerotic is pierced by small openings which give passage to the ciliary arteries and to the ciliary nerves.

### What is the structure of the sclerotic?

It is composed of bundles of connective tissue passing in all directions, and bound together by an interfibrillar and interfascicular cement-substance. A capillary network with wide meshes passes through the entire membrane. The sclerotic is poorly supplied with nerves. A lymph-system is found resembling that of the cornea.

### What is the canal of Schlemm?

This is a small circular canal situated about 2 mm. posterior to the sclero-corneal margin and near the inner surface of the sclerotic, which communicates with the small spaces between the fibres of the ligamen-

tum pectinatum, and is considered to be a lymph-canal aiding in the passage of fluids from the interior of the globe. It is not always single, but may be divided at times into two or three smaller canals.

### **What is the capsule of Tenon ?**

This is a sac of connective tissue which surrounds the posterior part of the eye and serves as a socket in which the globe rotates. It is thin posteriorly, but becomes thicker near the equator of the globe, passes forward, is penetrated by the muscles of the globe, and is attached to the sclerotic about 1 line back of the sclero-corneal junction. This capsule is divided into two portions, one of which, the visceral layer, is closely adherent to the sclerotic, the other, the parietal layer, lies against the fat of the orbit. The opposed surfaces of this sac are covered with endothelium, moistened by secretion, which favors the easy movement of the globe.

### **What inflammations is the sclerotic subject to ?**

A form of inflammation known as *episcleritis*, occurring in the anterior segment of the sclerotic, is not infrequently met with. It consists of a deep congestion of the affected part, which presents a dark-red appearance just beneath the conjunctiva. The conjunctiva becomes involved also, and the mass at the inflamed point is slightly elevated. The inflammation usually occurs in single patches, circumscribed and slightly nodular. It is very slow in its progress, and often includes the whole thickness of the sclerotic. It has a tendency to travel around the cornea, affecting at intervals the whole of the anterior segment of the globe. It is not infrequently associated with a chronic form of keratitis, and is also complicated in some cases by inflammation of the iris, ciliary body, and anterior segment of the choroid. It is then known as anterior uveitis.

### **What is the cause of episcleritis ?**

It occurs most frequently in gouty individuals and in those who suffer from rheumatism. Children of a tuberculous habit are also attacked, and in these the condition known as anterior uveitis is most frequently met with.

### **What is the treatment of episcleritis ?**

- Local treatment alone is seldom sufficient. Hot applications may be employed with benefit. In cases where iritis exists atropine should be used, and in cases where slow ulceration of the cornea is also threatened, some stimulating application other than the hot fomentations, such as calomel or the yellow-oxide-of-mercury ointment, may be employed with benefit. The constitutional treatment consists in the giving of remedies directed against the gouty or rheumatic condition. The salicylate of sodium and also the iodide of potash, used in connection with colchicum, given for a long period of time, produces beneficial results. Since pho-

tophobia is often a pronounced symptom in some cases, the eye should be protected from light by the use of blue glasses or the patient may remain in a room that is partly darkened.

### **What are the results of episcleritis?**

In not a few cases where the sclerotic is deeply involved, the inflammation results in thinning the sclerotic in its anterior segment, and the intraocular pressure subsequently leads to bulging of the sclerotic at the weak point and to the production of scleral staphyloma.

### **How should wounds of the sclerotic be treated?**

Rupture of the sclerotic by blows on the eye occur almost always without an accompanying opening through the conjunctiva, and portions of the vitreous, with at times the lens, escape beneath the conjunctiva. If the lens alone is found beneath the conjunctiva, it may be permitted to escape by incision through this membrane, the wound thoroughly cleansed with an antiseptic, a compress bandage applied, and the eye left to recover. If there is an escape of a considerable amount of the contents of the globe, it becomes necessary to remove the globe; and this should be done early. If the rupture is slight and the interior of the eye is clouded by the occurrence of hemorrhages, it is well to apply a compress bandage and let nature proceed to a clearing up of the media before any operative measure is undertaken, as after this operative procedure may be unnecessary. Should the wound occur through the anterior portion of the sclerotic, involving the attachment of the ciliary body, the danger to vision by slow inflammation and to affection of the fellow-eye through sympathy may be very great. It is in such cases sometimes necessary to remove the globe to prevent further injury.

Cleanly incised wounds, even if quite extensive, if they do not involve the ciliary body, usually heal kindly and favorably under the influence of a compress bandage. Wounds in the anterior fourth of the sclerotic—that portion known as the ciliary region—are particularly dangerous, because of the effect liable to ensue from infection of the ciliary body and from irritation to this part through cicatricial contraction. Such eyes, if they are not immediately removed, should be carefully watched, and on the first sign of sympathetic inflammation to the fellow-eye or of the appearance of glaucomatous symptoms to the injured eye they should be removed.

## **THE IRIS, CILIARY BODY, AND CHOROID.**

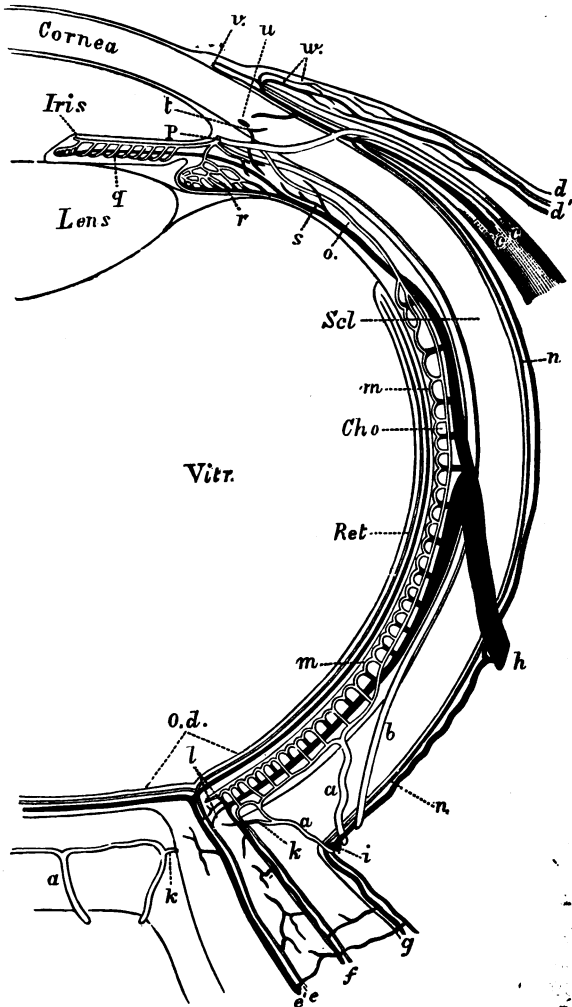
### **What is the second membrane of the eye?**

It is composed of the iris, ciliary body, and choroid, and is known as the vascular membrane, tunica vasculosa, or uveal tract. It is very rich in vessels and nerves, and is pigmented throughout except in albinos.



THE EYE.

FIG. 9.



(For description, see p. 59.)

**What is an albino?**

An individual whose tissues throughout the body are without pigment.

**What is the iris?**

The iris is a circular membrane perforated in its centre, which hangs as a curtain in the anterior portion of the eye and serves to regulate the amount of light admitted to the interior of the eye. It measures about 11 mm. in diameter. It springs from a root which is attached to the ciliary body and to the ligamentum pectinatum. Its free margin rests against the anterior capsule of the crystalline lens when the pupil is contracted or moderately dilated. In a state of maximum dilatation it hangs free in the aqueous humor. The iris serves to separate the anterior from the posterior chamber of the eye. From before backward the iris is composed of a layer of endothelium, posterior to which is the stroma of the iris, composed of a framework of connective tissue containing bundles of radiating fibres and of interlacing fibres. In the stroma of the iris are found the blood-vessels and nerves, and in colored irides pigment-cells more or less numerous are deposited. Near the pupillary margin of the iris, extending for a distance of from 1 to  $1\frac{1}{2}$  mm., and being about  $\frac{2}{16}$  mm. in thickness, is the circular muscle known as the *sphincter iridis*. Posterior to the stroma of the iris is the uveal layer, which consists of two layers of deeply-pigmented cells. The pigment consists of minute granules placed in cells having indistinct nuclei.

**What is the structure of the sphincter of the iris? and what is its nerve-supply?**

The sphincter of the iris is composed of non-striated muscle-fibres, and receives its nerve-supply from a third or motor oculi.

**From what source is the vascular and nerve-supply to the iris derived?**

The vessels to the iris come from the long ciliary arteries, which are two in number. They pierce the sclerotic near the optic-nerve entrance, pass forward between the sclerotic and choroid in the horizontal meridian, and just before reaching the root of the iris in the ciliary body divide and send one branch above and one branch below, encircling the iris. These branches meet in the perpendicular meridian and anasto-

FIG. 9.—Diagrammatic Representation of the Course of the Vessels in the Eye (horizontal section, after Lèber). The veins are represented black, the arteries clear. *a*, arteriæ ciliares posteriores breves; *b*, arteriæ ciliares posteriores longæ; *c*, arteriæ et venæ ciliares anteriores; *dd'*, arteriæ et venæ conjunctivales posteriores; *e*, arteriæ et venæ centrales retinae; *f*, vessels of the internal, and *g*, of the external optic sheath; *h*, venæ vorticosæ; *i*, venæ ciliares posteriores breves; *k*, branch of the posterior short ciliary artery to the optic nerve; *l*, anastomoses of the choroidal vessels with those of the optic nerve; *m*, chorio-capillaris; *n*, episcleral branches; *o*, arteria recurrens choroidalis; *p*, circulus arteriosus iridis major; *q*, vessels of iris; *r*, of the ciliary processes; *s*, branch to the venæ vorticalis from the ciliary muscle; *u*, circulus venosus; *v*, marginal loop plexus of the cornea; *w*, arteria et vena conjunctivalis anterior.

nose, but not very freely. This circle is termed the *circulus iridis major*. From it radial branches are sent into the iris to the pupillary margin, where they break up into a capillary network and form the *circulus iridis minor*. The venous blood from the iris is conducted to the ciliary body, and finds exit from the globe principally through the anterior ciliary veins. The iris is richly supplied with nerves of sensation, derived from the ciliary nerves, which are branches of the ophthalmic ganglion and of the nasal division of the fifth. These nerves enter the iris from the ciliary body at its root in relatively large trunks, ten to twelve in number, and pass into the stroma of the iris, where they form a rich plexus from which terminal filaments are given off.

### **What is the hyaline membrane of the iris?**

This is a thin membrane found between the uvea and the stroma of the iris, which is continuous with the lamina vitrea of the ciliary body and the choroid.

### **On what are the contraction and dilatation of the pupil dependent?**

These movements are very complex. The contraction of the pupil is brought about by nervous impulse to the sphincter papillæ through the third or motor oculi. This motion is not under control of the will, but is dominated by certain stimuli. Contraction of the pupil is brought about by light being reflected into the eye, by the effort of accommodation, etc. Dilatation of the pupil depends on stimulation of the sympathetic through its vaso-motor branches and the removal of stimuli to the filaments of the third. It cannot be demonstrated that radiating muscular fibres exist in the human iris. It is therefore thought that dilatation of the iris is brought about by contraction of the walls of the blood-vessels, and consequent diminution in their lumen. The removal of so much blood from the iris lessens the amount of its bulk, and necessitates the removal of the remaining substance of the iris toward its root. Division of the third nerve alone produces but moderate dilatation of the pupil, proving that some other influence must be operative to produce the maximum dilatation. Paralysis of the sympathetic produces maximum contraction of the pupil, demonstrating the fact that dilatation of the blood-vessels exerts a strong influence in reducing the pupil to a minimum size.

### **What is the ciliary body?**

This is a portion of the vascular tract of the eye which is composed of a connective-tissue framework containing non-striated muscle-fibre, blood-vessels, and nerves. It measures about 1 mm. in thickness in its thickest portion, and is about 4 mm. in length. It is attached to the sclerotic by an annular band of connective-tissue filaments at a point about 2 mm. back of the clear margin of the cornea. It contains the muscle of accommodation, which is composed of non-striated fibres arranged in bundles. Some of these pass meridianly; others of these

bundles pass equatorially. This muscle serves to change the curvature of the crystalline lens in such a manner that the focus of rays of light for objects at different distances may fall upon the retina at the will of the observer. Depending from the inner surface of the ciliary body are the ciliary processes. They are about seventy in number, are very vascular, and serve to secrete the nutrient fluids in the interior of the eye which go to sustain the vitality of a portion of the vitreous, the lens, and the cornea. The nerve-supply to the ciliary body is plentiful and is derived from the ciliary nerves. The ciliary body is continuous with the choroid in its deeper layers. The inner layers of the ciliary body are the lamina vitrea and the uveal layer. These correspond in structure to the same layers in the iris, and are continuous with them. Posteriorly these layers are continuous with the lamina vitrea of the choroid, with the pigment-layer of the retina, and with the framework of the retina. In the anterior portion of the ciliary body the pigmented layer is composed of a double layer of pigmented cells; in its posterior portion back of the apices of the ciliary processes the inner layer of cells is not pigmented.

### What is the choroid ?

The choroid is a pigmented membrane which covers the inner posterior two-thirds of the surface of the sclerotic. It is composed from without inward of—first, a thin pigmented layer which is attached to the sclerotic and is known as the *lamina fusca* (by some regarded as part of the sclerotic). It is composed mostly of branching pigmented cells, and is almost entirely devoid of blood-vessels. Between this and the next layer of the choroid is a space known as the perichoroidal lymph-space, the walls of which are lined with endothelial cells. The next layer is the so-called *lamina suprachoroidæ*. This membrane contains the large vessels of the choroid, of which the arteries are derived from the short ciliary arteries, eight or ten in number, which pierce the sclerotic in the region of the optic nerve. They break up into a network, and send radial branches into the inner layer of the choroid, which is known as the *choriocapillaris*. The veins in this layer gradually converge and form the trunks of four large veins which pass out of the eye at the equator and are known as the *venæ vorticosæ*. These large vessels are held in position by a framework of connected tissue, which is interspersed in the brunette by numerous branching pigment-cells. Interior to this layer is a thin membrane composed of connective-tissue fibres, elastic and non-elastic, termed the elastic membrane of Sattler. This layer extends from the optic nerve to the *ora serrata* of the retina. The *lamina suprachoroidæ* does not stop at this point, but is continuous with the ciliary body. Finally is the last layer of the choroid, the *lamina vitrea*. This is a hyaline membrane, and is closely connected with the outer layer of the retina. The choroid is richly supplied with nerves, the terminal filaments of which, however, pass forward into the ciliary body, iris, and cornea.

**What is the function of the tunica vasculosa ?**

It serves to form a dark chamber of the interior of the eye and to regulate the amount of light that enters that chamber. By its vascular supply it furnishes nutrition to the outer layers of the retina, to the vitreous, crystalline lens, and to the cornea.

**What are the general symptoms of iritis ?**

The mobility of the iris is always impaired. When light is reflected into the eye or a mydriatic instilled, the dilatation produced occurs slowly if posterior synechiæ have not formed. If they have formed, the dilatation is also slow and the pupil assumes an irregular shape. The color of the iris is always changed from the normal, is darker, and presents a blurred or muddy appearance. The vision is more or less impaired according to the amount of exudation in the anterior chamber. There is marked injection of the pericorneal blood-vessels, and a rosy zone encircles the cornea, which usually presents a dark-red appearance. Pain is usually severe in acute cases, being most noticeable to the patient at night. The pain is referred to the temple or forehead, and is of a dull, constant character.

**What are the forms of iritis ?**

They may be divided, according to appearance, into serous, spongy, and plastic; according to cause, into rheumatic, syphilitic, traumatic, suppurative, and tubercular. Simple hyperæmia of the iris sometimes occurs as an accompaniment of rheumatism or gout, without passing into the true inflammatory condition.

**What is serous iritis ?**

This form of iritis has been termed descemetitis by older writers, but in fact has nothing to do with inflammations of Descemet's membrane. It consists in the throwing out of an exudation from the iris which has been termed serous. Deposits of a fibrinous nature also take place on the posterior surface of the cornea, forming in dots usually ranged in the shape of a pyramid, with the base at the lower part of the cornea, the apex reaching to the centre of the cornea. The aqueous is turbid, and vision impaired in proportion. Adhesion of the margin of the pupil to the anterior capsule of the lens occurs, and is sometimes very persistent. The pain accompanying this form of iritis may be comparatively mild or very severe.

**What are the causes of serous iritis ?**

Serous iritis may occur as a rheumatic or as a syphilitic iritis. The name has reference purely to the form of exudation observed.

**What is spongy iritis ?**

This form of iritis also derives its name from the nature of the exudation. The exudation from the iris into the anterior chamber consists of the plasma of the blood, which coagulates when it comes in contact with the

aqueous, and fills the whole anterior chamber with a spongy mass. The tendency to the formation of deposits on the posterior surface of the cornea and to permanent adhesions between iris and lens is not great. Pain accompanying this condition is usually pronounced, and the pericorneal and conjunctival congestion is also very pronounced. For the first few days the exudation remains unchanged. On cessation of the production of the exudation, that which occupies the anterior chamber begins to shrink and the shrinkage progresses. The mass gradually diminishes and disappears.

#### **What is plastic iritis ?**

This form of iritis derives its name from the tendency which it possesses to produce adhesions between iris and lens and of forming an occlusion of the pupil. The aqueous becomes cloudy, and vision is usually greatly impaired during the progress of the disease.

The *symptoms* may at times be very severe.

#### **What are the causes of plastic iritis ?**

It may be from syphilis, rheumatism, traumatism, or from sympathy.

#### **What is rheumatic iritis ?**

It is any form of iritis which has rheumatism or gout as its cause. Rheumatism may produce serous, plastic, or spongy iritis according to the peculiarity of the individual. A form of rheumatic iritis not infrequently met with is of the plastic variety, progresses slowly, and is accompanied with very little pain or local disturbance. Rheumatic iritis is very prone to relapses, and the so-called recurrent iritis is often of the rheumatic type.

#### **What is syphilitic iritis ?**

Syphilitic iritis is any form of iritis which has syphilis as its cause. It may appear in the serous, spongy, or gummous form. It is sometimes difficult to determine the cause of iritis, particularly if of the syphilitic variety, and it becomes necessary, in the absence of the history of syphilis, accompanied by the absence of a history of gout or rheumatism, to determine the diagnosis by the employment of antisiphilitic remedies. One form of syphilitic iritis is pathognomonic. This is the so-called gummous iritis. It consists in the formation of gummata in the substance of the iris. These are at first small, and appear in the inner zone of the iris about the margin of the pupil. At times the disease is not multiple, but one gumma appearing. This may attain to a large size and extend over the whole width of the iris. These small gummata which form in the inner zone are usually of a dusky-red color. They are slightly elevated. If the gumma attains to a large size, it becomes somewhat pale at its apex. There is but one form of iritis that might be confounded with the gummous form occurring in syphilis, and that is the tuberculous iritis. This form of iritis, however, is subacute. The elevations do not first appear at the margin of the pupil, are not so red, and are not accom-

panied with such marked congestion of the iris. In the syphilitic form the perivascular injection is very pronounced. In the tuberculous but slight. Syphilitic iritis is usually accompanied with very great pain.

#### **What is suppurative iritis ?**

A form of iritis in which the production of pus takes place. It is usually accompanied with suppuration of the whole uveal tract unless it is the result of traumatism, when only the iris and ciliary body need necessarily take part. Low conditions of the system predispose to this form of iritis. It is a very uncommon disease.

#### **What is recurrent iritis ?**

Recurrent iritis may be syphilitic or rheumatic. As its name implies, it affects the individual repeatedly. Unfavorable conditions of the system produce a recurrence.

#### **What is the treatment of iritis ?**

It is very necessary to prevent and to break up adhesions between the free margin of the iris and the anterior capsule of the lens. For this purpose mydriatics are employed, the one most commonly used being atropine. In certain cases this mydriatic produces a marked inflammation of lids and conjunctiva, and will not be tolerated by the patient. In these cases it is found that duboisine will often be borne without the disagreeable results produced by solutions of atropine. Warm fomentations to the eye will also aid in promoting the action of the mydriatic in causing dilatation of the pupil. The use of atropine is frequently sufficient to allay the pain which is present. If this does not suffice, leeches should be applied to the temple in the form of the natural or artificial leech. Blisters may be used, but are not very efficient. Leeches are applied in the following manner: The skin on the temple immediately back of the angle of the eye is the place best suited for their application. The surface is cleansed with soap and water, and lastly with clean water, and the leech, contained in an ordinary leech-glass, is permitted to become attached to the skin. It is best to employ five or six, and to confine their operations to a space on the temple that could be covered with a silver quarter of a dollar. The leeches are permitted to remain until they have filled themselves and drop off. The surface should then be washed with an antiseptic solution and a warm, moist bandage applied to encourage the bleeding. Four to six ounces of blood should be removed. After leeching the patient usually experiences great comfort and enjoys a refreshing sleep. Photophobia usually exists, and the patient should be kept in a darkened room and should wear a shade or dark-blue glasses to protect the eye from the light. Frequent bathing in hot water will be found to give relief and to favor the absorption of the exudation from the anterior of the eye.

#### **What are the results of iritis ?**

The most frequent result is the formation of permanent bands of ad-

hesion between the iris and the anterior capsule of the crystalline lens. These are called *posterior synechia*. They may be partial or complete. When partial, the injury to the eye is comparatively slight. When complete, the condition is usually associated with the presence of an exudation which occludes the pupillary space. In a short time the secretions from the posterior chamber cause the iris to bulge forward; the pupil is sunken, producing a condition known as *crater pupil*. This bulging forward of the iris indicates retention of the fluids secreted in the eye, the globe becomes hard, and a condition of glaucoma ensues.

#### **What is the treatment of this complication in iritis?**

The *treatment* is principally operative, and is employed in those cases where total posterior synechia or occlusion of the pupil exists. It consists in removing a portion of the iris. In recurrent iritis it is sometimes advisable to perform iridectomy, which, in connection with internal medication, not infrequently suffices to cure the patient.

#### **What is cyclitis?**

It is an inflammation of the ciliary body, and may occur as a serous or as a suppurative inflammation. In cyclitis there is deep pericorneal injection, with pain referable to the temple and side of the head: On palpating the eye through the lids the patient experiences a tenderness of the parts. In serous cyclitis the anterior portion of the vitreous, as well as the aqueous, becomes hazy and the fundus is obscured. Suppurative cyclitis is usually associated with suppurative choroiditis and iritis.

#### **What is plastic cyclitis?**

This is a form of cyclitis by which an exudation of plastic lymph is thrown out, which usually forms a layer in the anterior portion of the vitreous behind the lens. This exudation becomes organized and takes on the form of cicatricial connective tissue. In certain cases this membrane forms a firm partition between the lens and the posterior parts of the eye. Examination with the oblique method discloses a grayish mass back of the lens, situated at its periphery when the membrane is not complete. This form of iritis is usually extremely slow in its progress and frequently compromises vision to an alarming extent.

#### **What are the causes of cyclitis?**

Rheumatism and syphilis play a prominent rôle, but traumatism is by far the most frequent *cause* of its production. The entrance of a foreign body into the eye or a lacerated or punctured wound, carrying minute germs of infection, suffices to produce the disease.

#### **What is the treatment of cyclitis?**

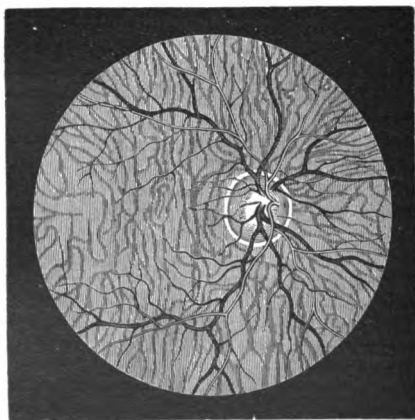
Removal of the cause if possible. If this cannot be done, atropine, hot applications, with internal medication directed to any systemic predisposing cause, should be employed.



### What is the appearance of the normal choroid?

In the living subject the choroid must be studied by use of the ophthalmoscope. When examined in this way the fundus of the eye presents a reddish reflex when light is thrown upon it. This reddish reflex is produced by the reflection of light from the choriocapillaris of the choroid, the pigment-layer of the retina, and the pigment-cells distributed throughout the choroid. The reddish background is complete throughout the fundus of the globe, except at the point of the entrance of the optic nerve, where there is a pale pink circular disk from which the nerve-fibres pass and are distributed on the surface of the retina, and the blood-vessels of the retina emerge, divide, and pass to the various parts of the retina. The fundus usually presents a mottled appear-

FIG. 10.



Ophthalmoscopic Appearance of Healthy Fundus in a Person of very Fair Complexion. Scleral ring well marked. Left eye, inverted image (Wecker and Jaeger).

ance, which is more marked in the brunette than in the blonde. This mottled appearance is due to the presence of pigment in the spaces between choroidal vessels. In the blonde the large vessels of the lamina suprachoroidæ are visible, and the fundus is of a pale-pink hue. In the brunette the color is deeper, and in the negro it becomes very dark and in some cases is of a slate color. In the albino the blood-vessels of the choroid can be distinctly seen, and the shining through of the white sclerotic gives the fundus a very light pink tone. The blood-vessels of the retina course over all parts of the fundus, except at a point near the posterior pole of the globe known as the macula lutea, where the surface

is free from blood-vessels and the fundus presents an even tone. The fundus of the eye appears lighter in proportion to the light that is reflected on to it. Consequently, examinations made when the pupil is small or illumination weak give a darker background than is the case in the same eye when the pupil is large or the illumination intense.

### **What forms of inflammation is the choroid subject to?**

Serous, plastic, purulent, tubercular, and syphilitic.

### **What is serous choroiditis?**

This form of choroiditis is characterized by a diffuse haziness of the vitreous, which contains minute floating opacities. It is usually accompanied with slight episcleral congestion and with slight pain. On looking into the eye the fundus is obscured and minute floating bodies may be discerned. Increase of the tension of the eye is sometimes noticeable.

### **What is plastic choroiditis?**

It consists in an inflammatory process which occasions the throwing out of an exudation which unites the choroid and retina, and eventuates in the destruction more or less of the outer layers of the retina.

### **What are the causes of serous and plastic choroiditis?**

In many cases it is difficult to determine, but that syphilis plays a rôle in a very large number of cases is not to be doubted. Rheumatism and gout are the causes in some cases.

### **What is the treatment of plastic choroiditis?**

Nothing can be done to prevent changes that must necessarily take place in the percipient layer of the retina from its participation in the plastic process. The internal administration of the iodide of potash and of mercury in syphilitic cases will often produce very excellent results and will stop the progress of the disease. Where syphilis is not the causative agent tonic remedies and measures to improve the general condition of the patient are advisable.

### **What is disseminated choroiditis?**

It is one form of plastic choroiditis, and it is distinguished by the general character and distribution of the atrophic patches produced by plastic choroiditis. These are distributed throughout the fundus, and are usually irregular in size, some of the patches being very small and some very large. They are also irregular in shape. The atrophic patches are the result of the exudation which is thrown out in plastic choroiditis. These spots of exudation appear first as pale, ill-defined, irregular patches. The exudation gradually absorbs, carrying with it the pigment layer of the retina and of the choroid, causing a heaping up of pigment at the margins of the patch and permitting the white sclerotic to show through.

**What is chorio-retinitis centralis ?**

This is a form of plastic choroiditis which attacks only the posterior pole of the globe, producing its greatest ravages in the vicinity of the macula lutea, the area of most distinct vision. It may produce great impairment of vision.

**What is choroiditis syphilitica ?**

A form of plastic choroiditis characterized by a peculiar formation of the patches. These are circular in shape, usually small, and more or less widely distributed throughout the entire fundus. This form of choroiditis has also been termed *choroiditis guttata*, because of the drop-like appearance of the patches.

**What is suppurative choroiditis ?**

As the name implies, it consists in the suppurative process taking place in the choroid. It is usually the result of traumatism or of metastasis from similar processes taking place in the membranes of the brain, in the genital tract, or in other parts of the system. Suppurative choroiditis is in the greater number of cases associated with suppurative cyclitis and iritis. The entrance of foreign bodies into the eye, infectious wounds, and suppurative processes affecting the cornea not infrequently produce suppurative choroiditis.

**What are the symptoms of suppurative choroiditis ?**

Occurring as the result of traumatism, it is usually rapid in its progress; the ocular conjunctiva becomes much congested and oedematous, producing a raised border about the cornea—the condition known as *chemosis*. A reflected light into the eye gives back a yellowish reflex. The pain is intense until the eye has opened and the pus permitted to escape. Suppurative choroiditis of the above type is termed *panophthalmitis*. Occurring in children and in adults as a result of metastasis, it first produces redness and swelling of the ocular conjunctiva; the globe becomes slightly harder than the normal and apparently slightly enlarged. The tension is somewhat increased. Some pain is experienced by the patient, but usually this is not intense. If the globe does not rupture, the inflammatory reaction gradually subsides, the globe becomes smaller than normal and the tension much reduced, in which condition it remains. The reflex from the interior is of a whitish-yellow color, and may readily be mistaken for the reflex produced by glioma of the retina.

**What is the treatment of suppurative and metastatic choroiditis ?**

If the pain is intense or if the globe is ruptured, enucleation is advisable. If, however, the condition occurs in childhood and is not painful, the eye may be permitted to remain and the patient may be treated simply for the purpose of relieving pain.

**What is tubercular choroiditis ?**

It is a form of choroiditis in which miliary tubercles form in its

tissues. The tubercles usually appear near the posterior pole of the eye and affect the choroid in preference to any other tunic. They always appear in connection with tuberculosis of other parts of the body. Their occurrence in cases which come before the oculist is very rare. With the ophthalmoscope a reddish point in the fundus of the eye is the first thing observable. Shortly afterward the points present a whitish appearance at their centres and are distinctly elevated. Vision is disturbed only at the points covered by the tubercle. They advance slowly, and usually produce so little disturbance that it is unnecessary to direct the treatment to them particularly during the life of the patient. At times they become large, and the surgeon finds it necessary to enucleate the eye.

**What are the microscopical appearances of tubercle of the choroid?**

The tumor is usually located in the anterior layers of the choroid, apparently springing from the choriocapillaris. They are surrounded by small infiltration-cells, and are composed of small and giant cells, usually breaking down in their centres. They contain tubercle bacilli which are easily demonstrated on section.

**What is the condition to which the name sclero-choroiditis posterior or posterior staphyloma is given?**

This is usually a passive condition, due to enlargement of the globe of the eye from the influence of the intraocular pressure on the previously weakened sclerotic coat of the eye. The gradual bulging of the eye backward, the process taking place at the posterior pole of the eye, puts the choroid on the stretch and produces atrophy, usually in that part immediately surrounding the optic nerve. In the early stage of this condition a whitish patch, crescentic in shape, usually shows itself to the temporal side of the optic disk, and is known as a myopic crescent. As the process advances atrophy of the choroid becomes more marked, and a large, irregular patch is formed about the optic disk. The development of this condition takes place in many cases about the age of puberty, and becomes stationary when the individual has reached adult life.

**What is the treatment for sclero-choroiditis posterior?**

Errors of refraction must be corrected. The eyes must not be used to excess and the general health of the individual must be improved.

**What are the characteristic appearances of rupture of the choroid? and what are its causes?**

This condition presents at first the evidences of hemorrhage from the choroid, which consists of a reddish patch, indicating the position of a clot of blood, and an indistinct whitish haziness associated with it, which marks the position of exudation not containing blood-corpuscles. As the blood and serous exudation are absorbed, a whitish patch is found to

occupy the fundus back of the clot, and when the absorption is complete a white line, usually somewhat curved, with its concave border toward the optic disk, is found to be present. It is clearly seen to be posterior to the retina, as the retinal vessels pass over it in an uninterrupted course. The white appearance is due to the showing through of the sclerotic. The cause of rupture of the choroid is contusion, usually from a blow. The blow is received on the front or anterior portion of the eye, producing rupture of the choroid nearly opposite to the point on which the blow was received, the rupture being by *contrecoup*.

No treatment can be employed to benefit the condition.

### **What is coloboma of the choroid ?**

It is a congenital condition resulting from an arrest in the development of the eye at a stage before the retinal fissure has become entirely closed. It also implies coloboma of the posterior layers of the retina, and is due to non-closure of the retinal tissue, and not to any original defect in the formation of the choroid. The condition is often associated with *congenital coloboma* of the iris and with *micro-ophthalmus*. The defect in the choroid is always in a downward direction from the optic disk. The borders of the defect are deeply pigmented. The defect itself has a white background, because of the showing through of the sclerotic. Over this defect pass a few retinal vessels, indicating that a portion of the layers of the retina are present over at least a part of the defect. A blind spot, corresponding very nearly in size to the coloboma, is always present in the visual fields.

### **To what forms of tumors are the choroid, ciliary body, and iris subject ?**

The tumor most frequently met with is sarcoma. It may be pigmented or devoid of pigment, and originate from any part of the choroid, ciliary body, or iris. Sarcoma is most frequently met with in the choroid, where it is pigmented in almost every case. Carcinoma also affects the choroid, usually secondary to carcinoma in some other part of the body. Primary carcinoma is impossible in the choroid, but may occur in the ciliary body. In this last-named part of the vascular tract carcinoma, if it develops, must develop from the epithelial cells supplied by its retinal portion. Tubercles and gummata may also form in these membranes. Cystic formations sometimes occur in the iris, but are very rare. Cavernoma of the choroid has been observed.

### **What are the symptoms of sarcoma of the choroid ?**

The patient's attention is usually first called to the trouble in the eye from a defect in vision. In the early stage of the growth no pain is experienced, but as the growth advances a stage is reached in which there is distinct increase in the tension of the eye, with pain referable usually to the side of the head. On examining the eye with the ophthalmoscope detachment of the retina is found, and a reddish nodular mass is

visible, usually either by examination with the ophthalmoscope or by oblique illumination, over the surface of which blood-vessels may be seen. Sarcoma of the ciliary body has much the same character. Occurring in the iris, it is usually deeply pigmented and produces a spherical tumor. It is of course easily recognized when it appears on this membrane. Flat sarcoma is of rare occurrence. Carcinoma of the choroid is usually flat, covering a considerable area. It affects the vision, but does not readily present any marked pathological condition in the interior of the eye, the diagnosis being made from the history of carcinoma in other parts of the body, the failure in vision, and the occurrence of an apparently exaggerated hypermetropia evident on ophthalmoscopic examination.

#### **What are the symptoms of gumma of the uveal tract?**

Gumma of the choroid is exceedingly rare. It is met with more frequently in the ciliary body and in the iris. It is usually accompanied by more acute inflammatory symptoms than is the case in carcinoma or sarcoma. In the ciliary body the differential diagnosis is made with difficulty. In the iris its color differs markedly from sarcoma. It is usually of a yellowish-white color, with blood-vessels crossing over its apex and with an inflamed base.

The *history* and the conduct of the growth, and the *treatment* with mercury and potassium, will determine the diagnosis.

#### **What is the treatment of sarcoma of the choroid or of the ciliary body?**

The globe should be removed at the earliest possible moment to prevent, as far as possible, metastatic processes from taking place.

#### **What is the treatment of sarcoma of the iris?**

When the growth is small and occupies a portion of the iris near the pupillary margin, it is sometimes possible to remove the growth by making an iridectomy without sacrificing the eye. Where the growth has attained large dimensions a removal of the eye is necessary.

## THE RETINA.

#### **What is the retina?**

The retina is the percipient membrane of the eye. It covers the whole of the interior of the eye in its posterior portion forward to a point about two lines anterior to the equator of the globe. It is an expansion of the nerve-tissue of the brain held together by a connective-tissue framework.

#### **What is the structure of the retina?**

Microscopical examination shows it to be composed of ten different layers, which from within outward are as follows: Lying next to the

vitreous is the *membrana limitans interna*. This membrane is formed by the close apposition of the expanded heads of Müller's fibres; it is very thin. Next to this layer we have the *nerve-fibre layer* of the retina, in which the nerve-fibres coming from the optic nerve are distributed. External to this layer is the *ganglion-cell layer*, composed of large branching nerve-cells disposed in rows four or five deep in the region of the fovea centralis, becoming very much scattered at the periphery of the retina. The nerve-fibres are connected with the ganglion-cells, and the cells send processes to each other and into the deeper layers of the retina. Directly beneath this layer is the *inner granular layer*. It consists of very fine connective-tissue fibres, which anastomose very freely. Posterior to this layer is the *inner layer of nuclei*, the *inner molecular layer* of some authors. It is composed of numerous round cells associated closely together. External to this layer is the *external granular layer*, resembling in structure the internal granular layer. Next to this comes the *external nuclear layer*, composed of round nuclei, resembling the inner nuclear layer; the external nuclear layer is somewhat thicker than the internal. Exterior to this layer is the *membrana limitans externa*, also apparently made up from the expanded ends of Müller's fibres. Springing from this layer is the *percipient layer of the retina*, the rods and cones. The rods consist of long rod-like processes, being attached to the external limiting membrane and fixed by the extremities into the outer layer of the retina. The cones are composed of two parts—a base, which is conical in shape and extends about one-third of the distance between the external limiting membrane and the outer layer of the retina; it is granular in structure. The outer limb is very thin and narrow, and is attached to the external layer of the retina. At certain portions of the retina the rods are greatly in excess of the cones, but near the entrance of the optic nerve the cones are more plentiful. At the fovea centralis they are much narrower than in other parts, and are present to the exclusion of the rods. Posterior to the layer of rods and cones is a single layer of large hexagonal pigmented cells, which are known as the *epithelium of the choroid*, but more properly as the pigment-layer of the retina. At the optic-nerve entrance the retina is pierced by a circular opening. The retina is limited anteriorly, or rather its functional layers are limited anteriorly, by what is known as the *ora serrata*, an irregular or serrated border where the retina suddenly becomes thinner and loses its nerve-elements.

### **What is the appearance of the retina when viewed by the ophthalmoscope?**

It is perfectly transparent in nearly all its parts, and the reflex obtained by looking into the eye with the ophthalmoscope is derived from other tissues. Blood-vessels belonging to it course over it anterior to the choroid. At the fovea centralis a circular whitish ring may sometimes be observed, which marks the border of this depression.

**What are opaque nerve-fibres occurring on the retina ?**

They are fibres passing from the optic disk on to the retina which still retain the medullary substance common to nerve-fibres in other parts of the body, especially those which go to make up large nerve-trunks. The fibres are spread out over the retina, usually near the optic disk, and form white patches which obscure all details of the portion of the fundus which they occupy. They are congenital and do not change through life.

**What disease-processes affect the retina ?**

Some of the most common are syphilitic retinitis, albuminuric retinitis, hemorrhagic retinitis, and retinitis pigmentosa.

**What is congestion of the retina ?**

It is a condition that may occur, but is very difficult of diagnosis. It is seldom possible to say that a retina is congested. It must pass into a condition of retinitis with exudation to make the diagnosis positive.

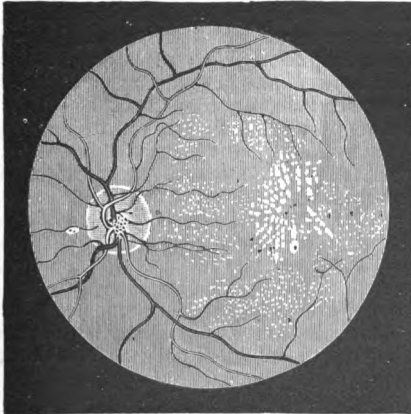
**What is albuminuric retinitis ?**

It is a condition of the retina dependent on the depraved condition of the blood, brought about by disease of the kidneys and an excessive waste of albuminoids from the blood.

**What is the appearance of albuminuric retinitis ?**

In the beginning there is a slight congestion of the disk with haziness

FIG. 11.



Renal Retinitis at a Late Stage (Wecker and Jaeger).



of the retina, particularly noticeable at the posterior pole of the eye. Soon whitish patches appear in the retina in the vicinity of the fovea centralis. These patches have usually somewhat of a symmetrical arrangement, radiating from the fovea centralis and spreading out in the shape of a fan. White spots, also due to exudation and diffuse in character, are found in the vicinity of the disk and along the blood-vessels. It not infrequently occurs that hemorrhages take place in the retina, often as forerunners of the retinal exudation. The whitish patches are due to the escape of the plasma of the blood into the various layers of the retina. When diffuse patches occur the exudation has taken place in the nerve-fibre layer. It obscures the blood-vessels and underlying structures. The sharply-cut, well-defined patches are due to the presence of exudation in the deep layers of the retina, where they occupy spaces formed between Müller's fibres. As the disease progresses the exudation becomes more plentiful until a stage is reached when the exudation ceases and absorption begins. Hemorrhages usually come from the capillaries and small veins.

#### **What are the causes of albuminuric retinitis ?**

Nephritis, whether acute or chronic, may cause this condition. In the acute form of nephritis the retinitis occurring is of the exudative variety. In chronic nephritis the retinitis following is of the hemorrhagic variety.

The *treatment* is directed to the condition of the kidneys.

#### **What is retinitis pigmentosa ?**

This is a disease characterized by the formation of small stellate pigment-patches, occurring first in the peripheral portions of the retina. It is essentially a degenerative process, affecting the choroid as well as the retina. It usually commences in early life and extends over a long period of time, gradually increasing in intensity, and eventually producing almost complete blindness. The pigmentation consists in the hypertrophy of the retinal pigment, which advances into the substance of the retina in the form of minute prolongations, and reaches and follows the course of the smaller retinal vessels. The retinal vessels become much reduced in size and the disk takes on a smoky, pale appearance. The visual fields narrow concentrically. However, when they comprise an angle of not more than thirty or forty degrees the patient's central vision is usually acute. Gradually the disease encroaches upon the remaining retina, and vision is almost if not entirely abolished. Individuals affected with this malady have great difficulty in seeing at night, because of the small area of retina capable of receiving impressions, and because of the sluggish condition of the remaining approximately normal portion. In rare cases the disease begins at the posterior part. It is then termed *retinitis pigmentosa centralis*.

#### **What is the treatment of retinitis pigmentosa ?**

*Treatment* is of but little avail, and may be ignored. The health of

the patient and the maintenance of good hygienic surroundings should be the physician's greatest care.

Associated with retinitis pigmentosa we sometimes have a form of cataract known as posterior polar cataract. In many cases the optic nerve is more or less atrophied.

### **What is hemorrhagic retinitis ?**

This is a form of retinitis dependent upon the condition of the blood-vessels. Occurring in old people, it almost always accompanies chronic interstitial nephritis, and is the expression of systemic disease of the arteries. The arterial walls become much thickened and the blood-current is interfered with. Because of stagnation produced from insufficient blood-supply to certain portions of the retina the walls of capillaries and veins become weakened and permit of the escape of blood.

### **What is syphilitic retinitis ?**

This form of retinitis is characterized by excessive exudation, and by hemorrhages more or less profuse occurring in the retina, and not infrequently also passing into the vitreous. The condition is almost always accompanied with a thickening of the walls of the vessels, a veritable syphilitic peri- and endarteritis. The disturbance to vision is very marked. The disease is not infrequently accompanied with more or less affection of the choroid. As it progresses toward recovery the exudation and hemorrhages gradually disappear, leaving the arteries reduced in size, atrophic patches in the choroid, and strings of connective tissue in various parts of the vitreous.

### **What is the treatment of this form of retinitis ?**

Potassium and mercury to saturation continued over a period of from three months to one year, and the maintenance of the system in as good a state of health as is possible. Atropine may be instilled and rest enjoined.

### **To what form of tumor is the retina subject ?**

Glioma is almost the only form. It is a kind of sarcoma. This form of tumor may spring from any part of the retina. It grows slowly at first, but in its later stages increases in size very rapidly. It occurs most frequently in children, and produces a peculiar condition which has been mistaken for purulent choroiditis. This is because of the reflex obtainable from throwing light into the pupil. When glioma is present, if it has attained to any size, a yellow reflex is noticed which has been likened to the reflex from the eye of a cat.

### **What is the treatment for glioma of the retina ?**

Since the disease is very malignant, it is necessary to remove the eye as early as the condition can be diagnosed.

Metastatic tumors appear in other organs in a large proportion of the cases.

### **What is pseudo-glioma of the retina ?**

In the progress of chronic forms of cyclitis a dense membrane is sometimes thrown out which covers the posterior part of the lens. This gives out a yellowish reflex, usually paler than the reflex obtained from an eye which is the seat of glioma. It is benign in nature, and the eye possessing it need not be removed for the purpose of saving the life of the patient.

## **THE OPTIC NERVE.**

### **What is the structure of the optic nerve ?**

The optic nerve has its origin from the optic commissure or chiasm, and receives its nerve-filaments from the brain by way of the optic tracts and chiasm. The optic tracts take their origin from the posterior portion of the optic thalamus, the anterior quadrigemina, and from the outer and inner geniculate bodies. They pass downward and forward, uniting with the opposite tract, forming the optic chiasm. The optic nerves pass from the chiasm through the optic foramina into the orbit to the posterior part of the eye. They are surrounded by a sheath which is a prolongation of the dura mater of the brain. About 14 mm. back of the globe the nerve is pierced by a canal which gives passage to the large vessels of the retina, the central artery, and central vein. The fibres of the optic nerve are arranged in bundles which are separated from each other by connective-tissue trabeculæ in which very small vessels are found. The fibres are medullated, but lose their medullary substance just before entering the eye. At the lamina cribrosa the optic nerve-fibres pass through the meshes to the surface of the retina, and are there distributed. The optic nerves measure about  $1\frac{2}{3}$  mm. in diameter as they pass through lamina cribrosa and 4 to 5 mm. in diameter in the part posterior to the globe.

### **To what diseases is the optic nerve subject ?**

Inflammation of the optic nerve is the principal disease. It may, however, be the seat of tumors, and is subject to atrophy without any preceding inflammatory change.

### **What are the causes and symptoms of optic neuritis (papillitis) ?**

The *causes* are usually extension of disease from the meninges of the brain ; it is also excited by tumor and abscess of the brain. It may be caused by tumor of the meninges and by inflammatory processes which originate external to the brain. Chief among the latter is the neuritis due to poisoning from alcohol and tobacco.

The external *symptoms* of neuritis are confined almost entirely to a diminution in vision. The ophthalmoscope must be used to diagnose the disease. On examining the optic disk with the ophthalmoscope we find that the edges have become blurred, often being entirely hidden.

The tissues are congested and raised, the elevation as determined by the ophthalmoscope often reaching from 1 to 2 mm. The central artery is usually slightly diminished in size, the veins enlarged and tortuous, and hemorrhages are frequently scattered over the surface of the disk and the retina in its immediate vicinity. The margin of the disk has a striped, woolly appearance, and because of the undoubted compression on the vessels it is known as *choked disk*. This condition reaches its highest development in infection from brain processes, as from meningitis, brain tumor, and abscess. The vision may be greatly impaired or may remain comparatively good for some time with a high degree of papillitis.

#### **What is the course of optic neuritis ?**

It usually runs a chronic *course*. In the acute cases accompanying meningitis, tumor, or abscess, or in high grades accompanying albuminuric retinitis, partial or complete atrophy of the optic nerve frequently results. In these cases vision is partly or completely abolished. In neuritis accompanying the use of alcohol or tobacco recovery with little loss of vision usually follows.

#### **What is the treatment of optic neuritis ?**

The *treatment* should be directed to the cause. The eye should be shaded and should not be used. Improvement of the general condition, with the administration of strychnine, and possibly the use of electricity in some cases, will aid in arriving at a favorable result.

#### **What is retrobulbar neuritis ?**

It is a disease affecting the optic nerve, producing an inflammatory process which shows on examination with the ophthalmoscope only as an atrophy. Diminution in vision in certain parts of the field of vision is the first symptom noticed.

#### **What are the causes of retrobulbar neuritis ?**

Poisoning from alcohol and tobacco, injury, and la grippe are the principal causes.

#### **What are the symptoms in retrobulbar neuritis from alcohol and tobacco ?**

The patient comes on account of dimness of vision, and on examination it is found that the central vision has fallen below the normal, while peripheral vision remains in the milder cases unimpaired. There is a central scotoma for red and green probably always present in this form of neuritis, and, while not pathognomonic, it is so seldom met with in other diseased conditions of the visual apparatus that it should always arouse suspicion of this as a cause of the disorder. In early cases the ophthalmoscope shows a slight degree of congestion of the optic disk, which never passes into a decided choked disk. If the case has existed for some months, there becomes apparent an abnormal paleness of the outer and lower quadrant of the optic disk.

**What is the treatment of retrobulbar neuritis from alcohol and tobacco ?**

This consists in entirely stopping the use of alcohol and tobacco, and recovery may be favorably influenced by medication to improve the general condition, and by the use of strychnine and the iodide of potassium.

**What are the causes of atrophy of the optic nerve ?**

Diseased processes in the brain affecting the cerebral centres of the optic nerve, optic neuritis, diseased processes occurring in the retina, as retinitis pigmentosa and albuminuric retinitis, traumatism, poisoning with lead, alcohol, and tobacco, and tabes dorsalis. Atrophy, originating in the central nervous system, is known as descending atrophy; originating in the eye or in the nerve itself, as ascending atrophy.

**What are the symptoms of atrophy of the optic nerve ?**

No pain is experienced in this disease. The *symptoms* consist in a loss of vision, which is gradual and usually progresses by concentric limitation of the field. Examination with the ophthalmoscope discloses a pale disk, which becomes more white as the atrophy progresses. The paleness of the disk is due to an absence of the capillaries of the tissues of the disk. The central arteries become very much reduced in size, frequently disappearing almost entirely. The veins also are reduced in size. In atrophy that is not preceded by papillitis there is more or less shallow cupping of the disk, which begins at its margin, gradually sloping to the centre. This form of atrophy permits the trabeculae of the lamina cribrosa to become visible throughout its entire extent. In atrophy preceded by papillitis the disk presents an even white appearance, no cupping being present. The new-formed connective tissue which has developed at the time of the papillitis forms a cicatricial mass which fills in the disk.

**What is the treatment of optic atrophy ?**

The general condition of the patient should be improved as much as possible. The cause, if it can be determined, should be removed. Strychnine in gradually increasing doses is sometimes employed with benefit. *Treatment* is often of no avail.

**Does hemorrhage into the optic nerve-sheath occur ?**

Rare instances of this condition have been observed.

The *symptoms* are those of sudden diminution in vision. On examination with the ophthalmoscope it frequently occurs that a small crescent-shaped hemorrhage may be seen partly encircling the disk at its margin.

The *prognosis* in this condition is favorable, vision improving as the clot is absorbed.

**What interruptions to the blood-current in the central artery of the retina occur ?**

Thrombosis and embolism of the central artery or of its branches are the principal forms of interference. Embolism is relatively rare, and is occasioned by endarteritis, which favors the formation of clots, followed

by partial or total obstruction. This condition accompanies general arterial sclerosis in elderly individuals. Embolism is much more frequent than thrombosis. It is most frequently met with in those suffering from endocarditis, and a few cases are observed during recovery from the puerperal state. The plugging usually takes place at the point of the first division in the artery, just below the lamina cribrosa. The small plug may advance beyond this point, and affect only a branch of the central artery after it has passed on to the disk.

#### **What are the symptoms of thrombosis or embolism of the central artery of the retina?**

Rapidly-diminishing vision, gradually deepening, is characteristic of thrombosis. Immediate and total loss of vision is the result of embolism. Both are unaccompanied with pain. Examination with the ophthalmoscope in recent total occlusion of the artery gives almost a milky-white appearance of the fundus in the immediate vicinity of the disk, which gradually fades at the periphery into the normal red reflex. This is due to the escape of the plasma of the blood into the nerve-fibre and superficial layers of the retina. The vessels are hidden. At the fovea centralis a cherry-red spot is always present, which is the result of the showing through of the blood-vessels of the choroid, the transparency of the retina at this point not being interfered with.

#### **What is the treatment of thrombosis or embolism of the central artery?**

In many cases *treatment* is of no avail, but in a relatively large percentage of the cases rather forcible massage performed by directing the patient to forcibly turn the eye inward or downward, and rubbing and otherwise manipulating the eye as far backward as possible, so as to produce some disturbance in the condition of the parts at the optic-nerve entrance, may succeed in releasing the clot to such an extent that some blood may find its way into the arteries and supply nutrition to the starving layers of the retina in time to preserve some vision. In some cases the vision will rapidly increase to almost the normal. The result of such manipulation in embolism is liable to be much more beneficial than the same manipulation employed in thrombosis. Other forms of treatment are of little avail, and permanent loss of vision results. In cases where a branch only is occluded the field of vision is impaired in the portion corresponding to the area of the retina supplied with nutrition from the occluded branch.

## **THE VISUAL FIELD.**

### **COLOR-BLINDNESS.—HEMIANOPSIA AND ITS VARIETIES.**

#### **What is meant by the term visual field?**

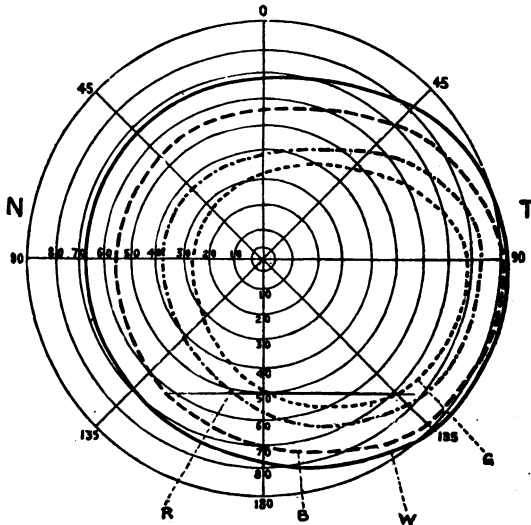
It is the extent or space through which we are able to discern objects

with one eye alone or both together when directing the line of vision to one point. Each eye has a visual field peculiar to itself. The eyes have a visual field *common* to each other, and there is also what is known as the *combined* field of vision. The visual field of the right eye extends temporally  $90^\circ$  when the eye is fixed on an object directly in front. It extends  $60^\circ$  to the nasal side,  $65^\circ$  below and  $55^\circ$  above. The visual field of the left eye covers the same extent. The size of the field common to both eyes is  $60^\circ$  temporally on both sides,  $55^\circ$  above,  $65^\circ$  below. It is not perfectly circular, but is slightly contracted in the median line. The combined fields of vision reach to an angle of  $90^\circ$  on either side,  $65^\circ$  below,  $55^\circ$  above, and is notched in the centre, as is the common field.

### How is the field of vision determined ?

It may be roughly and quickly determined by placing the patient with his back to the light, having him close one eye, and directing him to look

FIG. 12.



Field of Vision of Right Eye, as projected by the patient on the inner surface of a hemisphere, the pole of which forms the object of regard (half-diagrammatic): T, temporal, N, nasal side. W, boundary for white; B, for blue; R, for red; G, for green (Landolt).

at your own corresponding eye, which should be about 1 foot in front of the patient. The hand may then be approached midway between the patient and yourself toward the line of fixation, and a slight movement of

the fingers be made. If the field of vision is normal, the patient should be able to detect the approach of the fingers toward the line of fixation as soon as you can yourself see them. This is a comparative test, and is very useful in the rapid approximate determination of the extent of the field. Accurate charts of the field of vision may be obtained by measurements made with any one of the perimeters now in use. That of Priestly Smith or the one made by Meyrowitz will be found to serve the purpose admirably. They are supplied with charts on which the extent of the normal field of vision is marked.

### **What is the extent of the visual fields for colors?**

The extent is considerably smaller than for white, and of the four principal colors, blue, yellow, red, and green, is about as follows: For blue, 90° toward the temple, 55° nasally, 55° above, and 65° below; for yellow, very slightly smaller; for red, 80° to the temple, 40° nasally, 40° above, and 50° below; for green, 75° to the temple, 25° nasally, 35° above, and 45° below.

### **Of what value is the visual field in the determination of diseased conditions of the visual apparatus?**

It enables us to detect the influence of disease-processes on the vision and to locate in certain forms of disease the position of the lesion. It gives valuable information of the condition in cases of atrophy of the optic nerve and retina, and valuable suggestions regarding the time and propriety for operation in glaucoma.

### **What are scotomata?**

They are defects in the visual fields, and may be total or relative. *Total scotoma* is where the vision is entirely abolished over the area of the defect. *Relative scotoma* is blindness for certain colors only. There is a normal scotoma, or blind spot, in the visual field of each eye which corresponds to the optic-nerve entrance. This is situated a little to the inner side of the point of fixation and slightly below the horizontal meridian. Certain diseases produce characteristic scotomata. In gradual atrophy of the nerve the scotoma is concentric; in alcoholic amblyopia the scotoma is central and is relative; in glaucoma the scotoma is concentric, but greatest on the nasal side, and is absolute. In affections of the cortex of the brain it includes usually one-half of the field of vision of both eyes and on opposite sides. The latter is termed hemianopsia.

### **What is color-blindness?**

Color-blindness is an inability to distinguish between certain shades of color. It is usually confined to an inability to recognize greens and reds. Very few cases of total color-blindness have been seen.

### **How is color-blindness detected?**

The test usually applied is that of Holmgren's wools. These are



skeins of worsted of different tints of all the principal colors. The test is usually made by handing the patient a skein of one of the colors of which the tint is very decided, requesting him to pick out all the tints of this color in the collection. If color-blindness is present, the patient fails to recognize the different shades of the same color, the failure usually being in the reds and greens. The reds are usually mixed with the browns, the greens with the skeins of lighter color.

### Of what significance is color-blindness ?

It renders the patient unfit for service where signals of different colors are employed, such as railway, navigation, and general signal service.

### What are the various forms of hemianopsia ?

This condition is divided into two classes, termed homonymous and heteronymous. In homonymous hemianopsia one-half of the field of

vision on corresponding sides is abolished. In heteronymous hemianopsia the median, temporal, upper, or lower portions of the fields are abolished. The first form owes its production to a defect of the transmitting apparatus in the optic tract of one side or of the radiating fibres in the occipital lobe, or to a disease-process destroying the function of the visual area in the cortex of the brain, which is located in the region of the angular gyrus and cuneus. (See Fig. 13.)

FIG. 13.

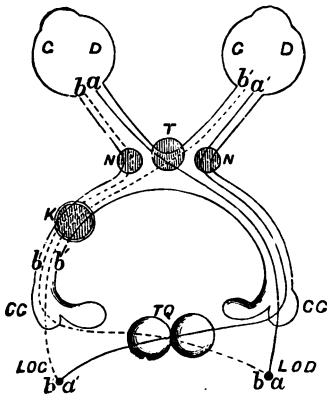


Diagram of Decussation of the Optic Tracts (after Charcot): *T*, semi-decussation in the chiasma; *TQ*, decussation of fibres posterior to the external geniculate bodies (*CG*); *a'b'*, fibres which do not decussate in the chiasma; *b'a'*, fibres coming from the right eye, and coming together in the left hemisphere (*LOG*); *K*, lesion of the left optic tract, producing right lateral hemianopsia; *a*, lesion of the left hemisphere (*LOG*), producing crossed amblyopia (right eye); *T*, lesion producing temporal hemianopsia; *N,N*, lesion producing nasal hemianopsia.

### What is the cause of nasal and temporal hemianopsia ?

Nasal hemianopsia can only be caused by lesion affecting the outer angles of the optic chiasm, compromising the nerve-fibres at these points and causing blindness of the temporal halves of each retina. Temporal hemianopsia can be caused only by a lesion affecting the optic chiasm in its anterior or posterior angles, causing blindness of the nasal half of the retina. Defects of the upper or lower halves of the fields of vision in both eyes at the same time are extremely rare.

**What is the line of division between the seeing and blind halves of the fields of vision in hemianopsia?**

In lateral hemianopsia the dividing-line usually passes perfectly perpendicularly through the line of fixation, deviating usually toward the blind side about  $3^{\circ}$  at the point of most acute vision.

**What is the field of fixation?**

It is a term given to the angular deviation of the eyes which can be produced by the muscles of the eye, enabling the eyes to fix any point in common without double vision. This can be determined by use of the perimeter. Landolt gives the following table of limitation of the field of fixation, arrived at after many tests: Outward,  $45^{\circ}$ ; downward,  $50^{\circ}$ ; inward,  $45^{\circ}$ ; upward,  $43^{\circ}$ . A knowledge of the normal field of fixation is of value in determining muscular defects that may exist.

**What is amaurosis?**

It is a term signifying loss of vision, and was applied by the old writers to conditions where the cause of loss of vision was obscure. The term at present is used but little.

**What is meant by the term "amblyopia"?**

It signifies a diminution in visual acuteness less in degree than that implied by the term "amaurosis." It is at present applied to but few conditions. The partial loss of vision which results from confirmed squint is termed amblyopia, and, since it is believed by some oculists to be due to non-use of the eyes, it is termed amblyopia from non-use.

**What is metamorphopsia?**

A condition in which there is distortion of images either from irregular astigmatism or from disease-processes affecting the retina.

**What is micropsia?**

An unnatural diminution in the size of the image, due to disease-conditions which cause a spreading of the rods and cones.

**What is megalopsia?**

The opposite of micropsia: objects appear to be abnormally large.

**SYMPATHETIC OPHTHALMIA.****Define sympathetic ophthalmia.**

It is a diseased condition produced in a previously healthy eye through the agency of a disease-process which has partly or totally destroyed the fellow-eye. It frequently results from injury to one eye, whereby infectious material has been carried into the eye and has there set up an inflammatory process, usually of the nature of an irido-cyclitis. Injuries in the region of the ciliary body are most prone to produce sympathetic

ophthalmia, but infectious wounds occurring in any part of the globe may serve to bring about this condition. Suppurative diseases of the eye which result in panophthalmitis seldom produce sympathetic ophthalmia. Operations for iridectomy and for the extraction of cataract sometimes lead to this disease. The eye first involved is termed the *exciting eye*, the other the *sympathizing eye*.

### **What are the symptoms of sympathetic ophthalmia ?**

The patient first experiences slight difficulty in the use of the eyes, a little pain in the region of the temple, and dimness of vision. The pain gradually increases, dimness of vision becomes more marked, and total blindness often ensues. The first objective sign is often slight pericorneal injection just below the cornea. Slight pressure in the ciliary region above produces pain. On examining the optic disk it is, in a number of cases, found to be in a condition of commencing papillitis. In the greater number of cases the first evidence of inflammation in the interior of the eye is visible in the iris, which is sometimes muddy in appearance; the free margin of the pupil becomes uneven, and posterior synechiæ form at an early date. With the formation of posterior synechiæ there is also the throwing out of plastic exudation, the aqueous becomes slightly turbid, and the iris is swollen and thrown into folds. At this stage the fundus of the eye cannot be seen because of the opacities in the aqueous and vitreous humors. The pericorneal injection becomes very marked, pain increases, and the disease goes on to the production of permanent blindness.

### **What is the theory of reproduction of sympathetic ophthalmia ?**

Older writers were of the opinion that the inflammation took place through the medium of the ciliary nerves, and that it was purely a sympathetic process. Recently it has been thought that the infectious material reaches the sound eye through the medium of the optic nerve-sheaths, and that it is in the nature of a micro-organism. While the theory of infection is the most plausible, it is not yet proven.

### **What is the treatment of sympathetic ophthalmia ?**

In the greater number of cases, particularly if all vision is lost in the exciting eye, it should be removed. However, in cases where the inflammation is well advanced in the sympathizing eye, and some vision remains in the exciting eye, it may be well to allow the exciting eye to remain, as the amount of vision to be obtained in the sympathizing eye cannot be determined with certainty, and the best vision may remain in the eye from which the sympathetic trouble was derived. In addition to enucleating the exciting eye, the local application of atropine and the use of hot applications should be commenced early. It is often found that the free administration of the iodide of potash with mercury is very valuable. Patients should be given perfect rest in bed and the eye should be protected from light.

**What is the duration of sympathetic ophthalmia ?**

It usually runs a long and tedious course.

The *prognosis* is bad even when the case is taken in its early stage.

In cases where total occlusion of the pupil has resulted from sympathetic ophthalmia some benefit may be derived by the formation of an artificial pupil.

**GLAUCOMA.****What is glaucoma ?**

A name given to a series of symptoms, most prominent among which is an increase in the tension of the globe.

**How are the different degrees of tension of the globe indicated ?**

They are indicated by the letter T, preceded by a plus sign when the tension is increased ; by a minus sign when the tension is decreased. The degrees of plus or minus tension are indicated by the numbers 1, 2, and 3 following the letter T. When the tension is normal the sign T N is employed ; when the increase in tension is perceptible and unmistakable the sign + T 1 is employed ; when of stony hardness the tension is indicated by the sign + T 3. The degrees of tension below the normal corresponding to those just described as above the normal are indicated by corresponding figures under the minus sign. The tension is determined by palpation with the fingers.

**What are the varieties of glaucoma ?**

They are comprised under two principal heads, primary and secondary. Primary glaucoma has reference to a condition of increase in the tension of the globe, originating in the eye itself without external influence. Secondary glaucoma is the term given to the same condition following an injury or some previous inflammatory process, or occurring as the result of lesions in other parts of the system, as in valvular lesions of the heart.

**What are the forms of primary glaucoma ?**

They are usually designated as simple, inflammatory, hemorrhagic, and fulminating or malignant. The term "absolute glaucoma" is applied to a condition where the disease has run its course and absolute blindness has resulted.

**What are the symptoms of simple glaucoma ?**

This form of the disease comes on very insidiously, and is usually first brought to the attention of the patient by partial failure of vision. It is unaccompanied by pain. The power of accommodation fails more rapidly in patients subject to this form of glaucoma than in the normal condition. The visual field becomes contracted nasally, the appearance of the eye changes but little, the veins in the anterior segment of the sclerotic become somewhat tortuous, and we sometimes notice a bluish

tinge of the sclerotic. On examining the interior of the eye with the ophthalmoscope we find that the optic disk is depressed; the blood-vessels appear to be interrupted at its margin; pulsation of the retinal arteries on the disk may be noticeable, but if not present may be readily excited by slight pressure on the globe exerted with the finger. The pupil is sluggish and may be slightly dilated. The anterior chamber and cornea often remain normal.

**What is inflammatory glaucoma?**

In this form pain is a pronounced feature. The disease may be chronic in character with occasional exacerbations, during the intervals between which the patient may experience but little discomfort. Great dimness of vision exists during an acute attack, which is somewhat recovered from when the attack passes over. During the inflammation the ocular conjunctiva is congested, the pupil dilated and oval, the anterior chamber shallow, and the cornea hazy. The tension is increased usually to a marked degree. Examination with the ophthalmoscope is often impossible because of the haziness of the cornea and of the media.

**What are the symptoms of hemorrhagic glaucoma?**

They resemble those of inflammatory glaucoma, except that in hemorrhagic glaucoma there is escape of blood from the vessels of the iris, ciliary processes, and at times from the vessels of the retina and choroid.

**What are the symptoms of fulminating or malignant glaucoma?**

They resemble those of inflammatory glaucoma, except that they are greatly intensified. The tension may reach + 3, and sight may be lost in twenty-four hours.

**What are the symptoms of secondary glaucoma?**

They are usually those of inflammatory glaucoma.

**What are the symptoms of absolute glaucoma?**

Total blindness, with increase of tension, with or without pain.

**What are the causes of glaucoma?**

Glaucoma is a disease peculiar to old age. Rare cases are on record of its occurrence in children, but the vast majority of the cases take place after the age of forty. It is very frequent in Hebrews, and is supposed to be due to consanguinity. It occurs in the rheumatic and gouty, and these diatheses seem to exert some causative influence. It most frequently occurs in hypermetrops, glaucoma in myopia being very rare. In probably every case the disease originates by interference with the escape of the intraocular fluids through the filtration angles of the eye. This may be brought about by a plugging up of the spaces, as sometimes occurs from a deposit of lymph in iritis, or it may be occasioned by a pressing forward of the root of the iris from an enlarged lens, or by sudden pressure against the lens from the vitreous chamber. Priestly

Smith is strongly of the opinion that the enlarged, flattened lens present in hypermetrops is chiefly instrumental in the production of primary glaucoma by pressure against the root of the iris, compromising the lymph-spaces at the iris angle. In secondary glaucoma, produced by injury to the eye, by a kerato-iritis, by hemorrhage from retinal vessels, as sometimes occurs in hemorrhagic retinitis, or by rupture of the lens capsule, any or all of these causes act to compromise the iris angle and to prevent the free escape of intraocular fluids.

### **What is the treatment of glaucoma ?**

It is medicinal and surgical. The *medicinal treatment* of glaucoma is best applied in primary glaucoma of the milder types. It consists in the use of warm applications and in the instillation of solutions of eserine or of pilocarpine in strength of from  $\frac{1}{4}$  to 1 per cent. A valuable formula for eserine is the following :

R. Eserin. sulph., gr.  $\frac{1}{2}$ ;  
 Solution cocain. hydrochlorat., 2 per cent.,  $\text{ʒ}$  ij.—M.

Sig. Instilled into the eye two or three times daily.

### **What is the operative treatment of glaucoma ?**

That which is found to give most satisfactory results is iridectomy. The iridectomy must be large, and it must be made so as to secure the removal of the iris as closely to its root as is possible. This is applicable in all cases of glaucoma, and should be done early in the disease. Also an operation known as sclerotomy, which consists in passing a Graefe knife through the sclerotic into the anterior chamber, making puncture and counter-puncture as deep in the iris angle as possible, including about one-fifth of its circumference, and cutting outward, leaving a small bridge of scleral tissue to prevent the wound from gaping. This operation, applicable only in the milder forms of glaucoma, is sometimes successful, but must usually be supplemented by an iridectomy. In absolute glaucoma, accompanied with pain, and in some forms of secondary glaucoma, enucleation must be resorted to.

## **THE LENS.**

### **What is the crystalline lens of the eye ?**

It is a transparent, lens-shaped body suspended in the anterior portion of the globe immediately back of the iris. It measures from 9 to 10 mm. in its longest and from 4 to 5 mm. in its shortest diameter. It consists of a semi-solid substance confined in a thin capsule, and serves to focus on the retina rays of light which enter it through the pupil.

### **What is the structure of the crystalline lens ?**

It is composed of a capsule and lens-substance proper. The capsule consists of a thin, homogeneous membrane which is lined on the posterior surface of its anterior half by epithelial cells from which the lens-fibres

are formed. Its posterior half consists simply of the thin homogeneous membrane. To the anterior and posterior portions near the equator are attached the fibres of the suspensory ligament. The lens substance proper is lamellated, the lamellæ, which are arranged concentrically, being composed of a single layer of lens-fibres placed side by side. The fibres and lamellæ are joined by an inter-cement substance. The spaces also give passage to lymph-streams which supply nutrition to the different parts of the lens. That portion of the lens formed before birth is commonly known as the nucleus, that after birth the cortex. The lens-fibres are long and narrow, being larger at each end than in the centre, and are hexagonal on cross-section. The lamellæ are arranged so that the ends of the fibres abut on each other in such a manner that a star-shaped figure is formed on the anterior and posterior aspect of the lens, the figure having the shape of an inverted  $\Lambda$  anteriorly, of an upright  $\Upsilon$  posteriorly. The lens rests in a fossa in the vitreous humor.

### What is the suspensory ligament?

It is a thin, fibrillated membrane which takes its origin from the ora serrata, from the cells of the pars ciliaris retinae, and from the inner layer of cells of the ciliary processes. These fibres pass downward and forward in the form of a membrane, dividing just before reaching the equator of the lens. A portion passes to, and is inserted into, the anterior capsule at about 2 mm. from the equator, and a portion passes to the posterior capsule and is inserted in it at about the same distance. The stronger attachment is to the anterior capsule. Some fibres pass through the triangular space which is known as Petit's canal, and find their attachment to the capsule of the lens. The lens capsule is also known as the zonula of Zinn. It marks the anterior limit of the vitreous humor.

### What constitutes cataract?

Cataract is an opacification of the crystalline lens or of its capsule.

FIG. 14.



**Nuclear Cataract:** 1, section of lens, opacity densest at centre; 2, opacity as seen by transmitted light (ophthalmoscope mirror) with dilated pupil; 3, opacity as seen by reflected light (focal illumination). The pupil is supposed to be dilated by atropine.

### What are the most common forms of cataract?

Nuclear, cortical, zonular or lamellar, anterior polar, posterior polar, Morgagnian, mixed, congenital, and traumatic.

**What is nuclear cataract ?**

In certain forms of cataract the opacity first appears at the nucleus of the lens, and extends from the nucleus to the peripheral portions.

**What is cortical cataract ?**

In this form opacities are first observed at the equator of the lens: they extend in wedge-shaped processes toward the centre, the base of the wedge being toward the equator. The opacities gradually advance until the lens becomes opaque throughout.

**What is zonular or lamellar cataract ?**

This is a form, usually occurring about the time of birth, which comprises opacification of a few lamellæ of lens-fibres located at the periph-

FIG. 15.



Lamellar Cataract.

ery of the nucleus, the centre of the nucleus and the cortex remaining clear. This form of cataract usually changes but little throughout life.

**What is mixed cataract ?**

This term is applied to the innumerable forms of cataract in which the plan of opacification follows no definite rule. Opaque spots and striæ appear throughout the lens-substance. To this form belong many of the congenital cataracts which have little tendency to increase.

**What is Morgagnian cataract ?**

When senile nuclei or cortical cataract has existed for a long time, the cortical portion sometimes becomes liquefied, only a small solid nucleus remaining. The term Morgagnian is given to this form.

**What is anterior polar or pyramidal cataract ?**

It is a form of capsular cataract usually caused by adhesion of the anterior capsule of the lens to the cornea, following a perforating ulcer of the cornea and escape of the aqueous humor. When healing of the ulcer occurs and the lens is drawn back into position by reaccumulation of the aqueous, the anterior capsule is slightly detached from the lens-substance, and the small conical protrusion so formed is filled by fibres apparently developed from the epithelioma of the anterior layer of the lens capsule. These new-formed fibres are opaque and remain unchanged.

**What is posterior polar cataract ?**

Any opacity at the posterior pole of the lens is termed posterior polar



cataract. It is usually caused by remnants of foetal blood-vessels. It not infrequently accompanies retinitis pigmentosa.

### **What are the causes of cataract?**

Cataract is undoubtedly due in the vast majority of cases to interference with the nutrition of the lens. In commencing senile cataract careful examination of the periphery of the fundus frequently discloses vascular changes, evident in the presence of peripheral choroiditis. Cataract not infrequently accompanies diabetes mellitus. Convulsions are said to occasion zonular cataract. Injury is a fertile source for the production of cataract, and exposure and privation also act as causes.

### **What is the method employed for the examination of cataract?**

The oblique illumination (previously described) is very valuable in the examination of the crystalline lens. If the pupil is dilated, the reflection of light into the eye obliquely will serve to disclose any considerable opacity that may exist in the lens. Opacities occurring in the lens usually have a whitish appearance when examined by oblique illumination. Certain forms of nuclear cataract give an amber tint, and in the exceptional cases of black cataract the color is a deep brown. The plane mirror of the ophthalmoscope is also used for the examination of opacities in the lens, the opaque portions appearing as dark spots against the red field of the fundus.

### **What are the symptoms of cataract?**

The patient frequently first experiences an interference with the vision in the form of dark lines or branching opacities which are projected into space. In some cases a general dimness of vision is first noticed. In the case of nuclear cataract the patient will say that he sees better when the day is dark or just at twilight, when the illumination is so weak that the pupils become somewhat dilated. No pain is experienced. If the cataract is well advanced, the pupil is occupied by an opaque mass which may be white or of a pearly color or brown or almost black. In lamellar cataract examination discloses a circular line of opacity which is most dense at its periphery. It can be seen that the centre of the lens between the layers of opacity is clear, and if the pupil is widely dilated a transparent zone is seen at the periphery of the lens.

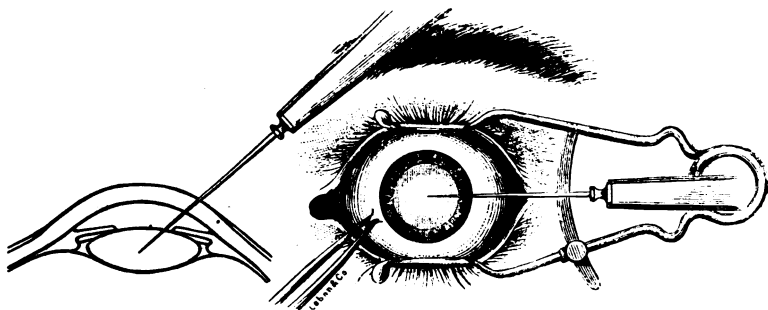
### **What is the treatment of cataract?**

In lamellar cataract it is sometimes advisable to make an artificial pupil, which will enable the patient to utilize the transparent cortex for visual purposes. If by dilating the pupil, maximum vision is greatly improved in this form of cataract, it is warrantable to make an iridectomy, as the operation is attended with little danger. Cataracts that occur before the age of twenty-five or thirty years are said to be soft cataracts, because the substance of the lens is not so firm as it becomes in later years. In this form of cataract the operation known as "needling" is employed.

### How is the needle operation performed ?

The eye is cocainized or the patient is given ether. Since the operation under cocaine is painless, this local anæsthetic may be employed. A stop speculum is used to separate the lids. The eye is then fixed with the fixation forceps. A sharp needle known as a cataract needle is made to enter the anterior chamber at a point midway between the centre and periphery of the cornea, usually in the horizontal meridian. The anterior capsule of the lens is divided and a portion of the lens cortex broken up. This is done through the pupil. The needle is withdrawn, atropine is instilled, the eye bandaged, and the patient put to bed. The

FIG. 16.



The Needle Operation.

operation of needling affords opportunity for the absorption of the lens-substance. It must be repeated three or four times, one operation following the other at intervals of three to eight weeks, to promote perfect absorption of the lens.

### What is the flap extraction ?

This is the method employed for the complete extraction of the lens, usually without its capsule. It consisted originally in making a flap of the lower half of the cornea. The flap was then tilted outward, the lens-capsule wounded, and the lens compelled to escape through the pupil, after which the iris was returned to its former position and a bandage applied. Instead of making a flap of the lower half of the cornea, Jacobson modified the operation by making a flap below, with the incision passing through the sclerotic about 1 mm. back of the sclero-corneal junction.

FIG. 17.



FIG. 18.

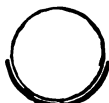

FIG. 20.



FIG. 19.



FIG. 19.—Fixation Forceps.  
 FIG. 20.—Von Graefe's Linear Cataract Knife.

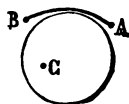
### What are the instruments required for the extraction of cataract?

A stop speculum, Graefe or Beers cataract knife, fixation forceps, cystitome, iris scissors, spatula, and small scoop or spoon.

### What is the linear extraction of Graefe?

It consists in making a linear incision in the globe above the cornea. The incision is commenced on a tangent with the horizontal meridian of the cornea, beginning about 2 mm. below the tangent with the perpendicular meridian. The point of the knife, after making the puncture, is directed toward the centre of the pupil; it is then carried upward, and emerges at a point corresponding to the puncture on the opposite side where the counter-puncture is made. By a gentle sweeping motion the blade is made to cut its way out, the centre of the incision reaching to the clear margin of the cornea. An iridectomy is then made. The capsule of the lens is then divided with the cystitome. Pressure on the lower portion of the cornea, directed toward the centre of curvature of the globe, made with a small spoon, is sufficient to cause the lens to tilt forward and to escape from the wound. The iris is then disengaged from the wound by means of the spatula, the margins of the wound adjusted, and the eye bandaged.

FIG. 21.



### What is the simple operation for cataract?

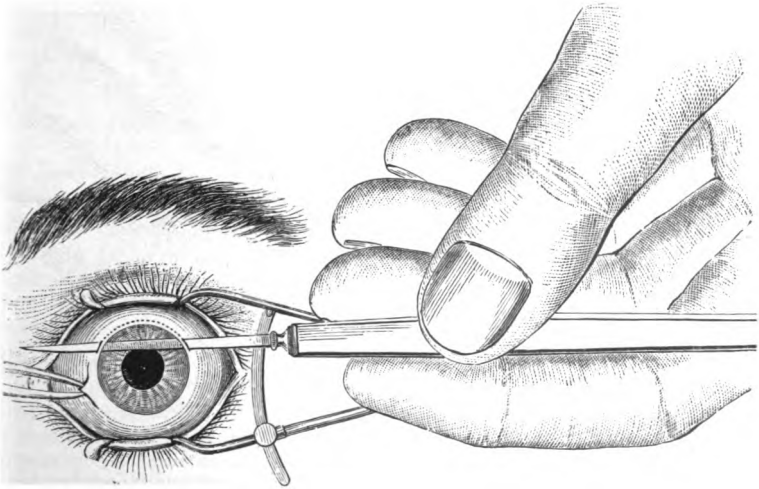
At the present time this operation is much in vogue. The incision made is usually in the nature of a flap. It consists in opening the anterior chamber to the extent of about a third of the circumference of the cornea, the incision being carried through the sclero-corneal junc-

tion just within the clear margin of the cornea or just external to the clear margin in the sclerotic, finishing in the corneal tissue at the sclero-corneal junction or just within the opaque border, according to the idea of the individual operator. The lens-capsule is lacerated either in its centre or near the periphery, pressure is made on the lower part of the cornea, and the lens is expelled through the pupil. No iridectomy is made. The subsequent treatment is as in the Graefe operation.

### What accidents are apt to occur at the time of operation ?

It sometimes happens that the lens, instead of escaping, is pressed backward into the vitreous chamber. When this occurs the wire loop

FIG. 22.

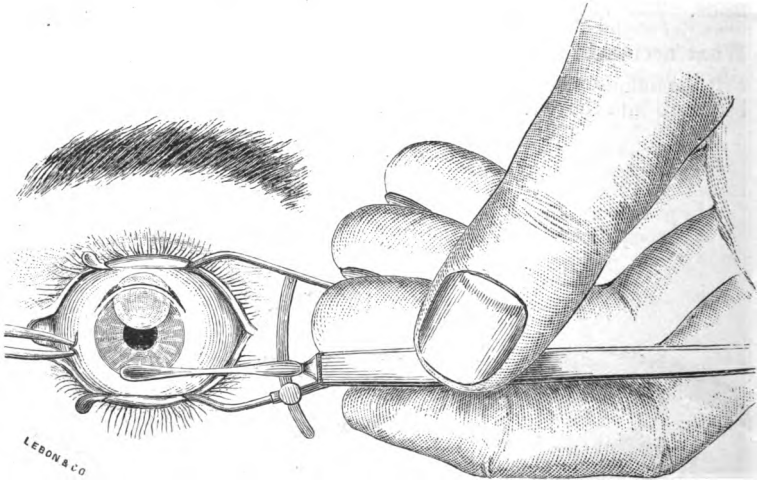


Operation for Cataract: the incision.

may be passed into the vitreous chamber, the lens engaged, and withdrawn. The manœuvre is not easy, and considerable damage may be done to the eye before the lens is extracted. Escape of vitreous may occur. If this is not large in amount, it is of little importance. The protruding vitreous should be excised, the wound rendered as free as possible from the protruding tissues, and the eye bandaged. In making the incision the iris may fall before the knife and a portion of it be excised. This usually is of little importance. It, however, almost always

necessitates the making of an iridectomy. The iris may be engaged by the point of the knife as it enters the anterior chamber. If the knife cannot be readily withdrawn sufficiently to disengage the iris, it should be passed through boldly and the incision completed.

FIG. 23.



Operation for Cataract: the removal of the lens.

### **What accidents may occur during the healing process?**

From engagement of the capsule in the wound a filtration opening may remain, which may cause a permanent fistula of the anterior chamber. Usually, however, when this complication arises the anterior chamber remains empty for some days, when the wound closes firmly and the anterior chamber is re-established. If fistula occurs, it may usually be closed by means of the cautery. The wound may reopen at any time in from twenty-four hours to ten days after the operation by reason of force applied to the eye. This usually simply entails the emptying of the anterior chamber and some hemorrhage into it, except after simple extraction, when prolapse of the iris is sure to follow. Prolapse of the iris, if observed soon after its occurrence, should be remedied by replacement or excision.

### **What is the treatment of traumatic cataract?**

It may be treated as the ordinary form of senile cataract. If, how-

ever, laceration of the lens-capsule has taken place, it sometimes happens that the lens-substance swells to such an extent that injury to vision is threatened from the production of a glaucomatous condition. A corneal incision must then be made and the lens-substance permitted to escape. In many cases where laceration of the capsule occurs the lens may be permitted to become absorbed, as in the operation for soft cataract.

#### **What is secondary cataract?**

Secondary cataract is opacification of the remnants of lens-matter and of the capsule of the lens, which sometimes occurs after the extraction of cataract.

#### **What is the treatment for secondary cataract?**

An endeavor should be made to effect a clear opening through the opaque structure. This may often readily be done by the use of the knife-needle, the operation being conducted as is the operation for the division of soft cataract. In certain cases it will be found necessary to operate by the use of double needles. When this is done the needles are made to enter the anterior chamber at opposite points. They are then made to pierce the opaque structure at the same point (at the centre of the pupil), and an opening is made by separating the points of the needles from each other. When the opening is made sufficiently large the needles are withdrawn, atropine is instilled, and the eye bandaged.

#### **What is dislocation of the crystalline lens?**

It is a condition in which the lens is freed from the suspensory ligament partially or completely. It may be a congenital condition, and is then known as *ectopia lentis*; however, it is most frequently traumatic in origin.

#### **What are the symptoms of dislocation of the lens?**

The patient's vision is markedly impaired. On examination the lens is found to have dropped from its normal position: it sometimes hangs by shreds of the suspensory ligament, but is often found lying at the bottom of the vitreous chamber on the ciliary processes. The iris is tremulous and the anterior chamber deep. It sometimes happens that the dislocation takes place into the anterior chamber. When this occurs marked symptoms of irritation are produced. The dislocated lens usually becomes opaque, and when this is the case and partial displacement only has occurred, diminution in vision is very great.

#### **What is the treatment of dislocation of the lens?**

If the lens falls into the vitreous chamber, or if it is still retained nearly in its former position and is not opaque, no *treatment* is necessary. If the lens, however, becomes opaque and occludes the pupil, or if it is dislocated into the anterior chamber and is producing inflammatory symptoms, an attempt should be made to remove it. The same plan of

operation is employed in most cases as that used for the extraction of cataract.

## THE VITREOUS HUMOR.

### What is the vitreous humor?

It is a transparent, jelly-like mass that occupies the large posterior chamber of the globe known as the vitreous chamber. It is composed of very fine fibrillæ which enclose a gelatinous fluid in their meshes.

### What pathological changes take place in the vitreous humor?

Small molecular opacities occur (usually accompanying a debilitated condition of the system) which are likened to flies by the patient, who projects their images into space. These are of little significance. They are known as *muscæ volitantes*. Large floating opacities, the remnants of exudation and of hemorrhages into the vitreous, also occur.

### What is *synchysis scintillans*?

It is a condition in which the interior of the eye is filled with small glistening particles, principally in the vitreous. On movements of the eye they become kaleidoscopic. They consist of crystals of tyrosin and cholesterin, and occur in degenerated conditions of the globe.

This condition calls for no special *treatment*.

### What is the treatment when foreign bodies enter the vitreous?

These may consist of substances of all kinds, but particles of iron and steel are most frequently met with. If the foreign body is not of a nature to produce inflammatory reaction, it is probably best to permit it to remain. If it is large or is apt to produce inflammatory changes, an attempt at its removal is advisable. If the substance is of a metallic nature, such as may be attracted by the magnet, an opening through the sclerotic may be made, the magnet point introduced into the vitreous, and an attempt made to find and remove the foreign body. Failing in this, the eye should be enucleated.

### What parasites are sometimes found in the eye?

The parasite most frequently found is the *cysticercus cellulosæ*. This parasite is seen most frequently in the vitreous. It may appear sub-retinal, and is also found at times in the anterior chamber.

The *treatment* consists in removal. Failing in this, the eye should be enucleated.

## OPTICAL PRINCIPLES.

### What is meant by the term "refraction"?

This term is used to indicate that change in direction which a ray of light undergoes when it passes from one transparent medium into another of greater or less density.

**What is a ray of light?**

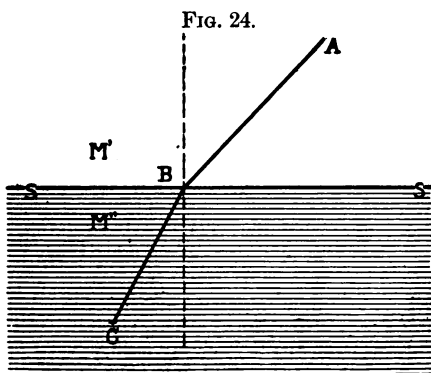
A single line or beam of light emanating from a luminous point.

**What is the normal of a surface?**

This term is used in physics to indicate an imaginary line drawn at right angles to the surface.

**What is the law of refraction relative to the passage of a ray of light from one transparent medium into another of different density?**

The ray of light is refracted toward the normal of the denser medium when it enters in a direction other than the normal to its surface. The



Law of Refraction:  $AB$ , incident ray;  $BC$ , refracted ray;  $M'$ , rare medium;  $M''$ , dense medium;  $SS$ , surface separating media.

reverse is true when a ray of light passes from a denser into a lighter medium under the same conditions regarding direction (Fig. 24).

**What is an incident ray of light?**

A ray of light that impinges on the surface of a refracting medium.

**What is implied by the term "index of refraction"?**

This term is applied to the number indicating the ratio between the sine of the angle of refraction and the sine of the angle of incidence.

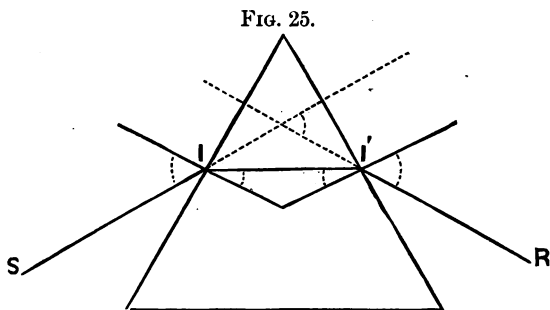
**What is the unit from which the index of refraction is computed?**

The conduct or course of a ray of light through air is taken as the unit for the computation of the index of refraction of all other media. Computed in this manner, the index of refraction of crown glass is 1.53; of rock-crystal pebble, 1.56; of flint glass, 1.70; of the crystalline lens of the eye, 1.42.



**What is the effect produced on a ray of light as it passes through a prism?**

It is refracted toward the base of the prism at both surfaces, since the law governing refraction is operative to produce this result as the ray

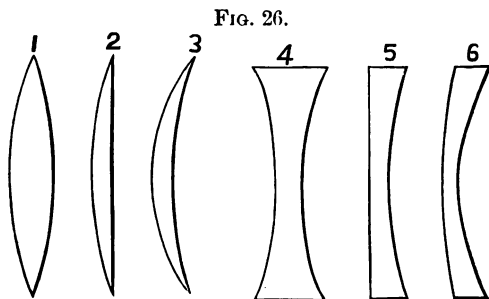


Refraction of Light, as shown by a Prism: S I, incident ray; I I', course through lens; I' R, emergent ray.

enters and as it leaves the prism. The relative relation of rays of light as they enter and leave the prism is not changed (Fig. 25).

**What is a lens?**

A lens is a transparent medium having two regularly ground opposing surfaces, one or both of which are curved, the curve either describing the segment of a sphere or of a cylinder.



Forms of Lenses.

**What are the different forms of lenses?**

They may be biconvex (1); biconcave (4); plano-convex (2); plano-

concave (5); converging meniscus (3); diverging meniscus (6); ground as portions of a sphere or as portions of a cylinder (Fig. 26). Periscopic lenses are forms of the meniscus.

**What is the principal axis of a lens?**

A line which cuts the lens at its centre and passes through its centre of curvature.

**What are secondary axes?**

Lines which pass through the optical centre of the lens (impinging on any part of its surface other than that corresponding to the principal axis), which are practically not changed in direction.

**What are biconvex and biconcave lenses?**

They are virtually two plano-convex or plano-concave lenses joined in such a manner that their principal axes coincide.

**What is the centre of curvature of a lens?**

It is the centre of a sphere of which the curved surface of the lens forms a part.

**What is the radius of curvature of a lens?**

A line extending from the centre of curvature of the sphere of which the curved surface of the lens forms a part.

**What is the optical centre of a lens?**

It is the point through which all secondary axes pass after entering the lens. In the case of a medium with a single curved surface it corresponds with the centre of curvature of the surface.

In the case of a medium with double curved surfaces, as in the biconvex lens, the secondary axial rays are first directed to a point anterior to the centre of the lens, and then to a point posterior to the centre of the lens. These are termed "nodal points." The optical centre in these lenses lies between the nodal points.

**What is the principal focus of a lens?**

It is a point at which parallel rays of light entering the lens are brought to a focus. In the biconvex or concave lenses their principal foci correspond with their centres of curvature if the index of refraction of the substance of which the lens is composed is 1.5.

**What is the principal focal distance of a lens?**

It is the distance between the optical centre of a lens and the principal focal point.

**What effect do the different forms of lenses produce on rays of light entering them?**

Convex lenses collect, concave lenses disperse, rays of light that pass through them. The former are called plus lenses, the latter minus lenses.

**What are conjugate foci?**

Points in relation to a lens at which, if the object is placed at one point, an image will appear at the other point.

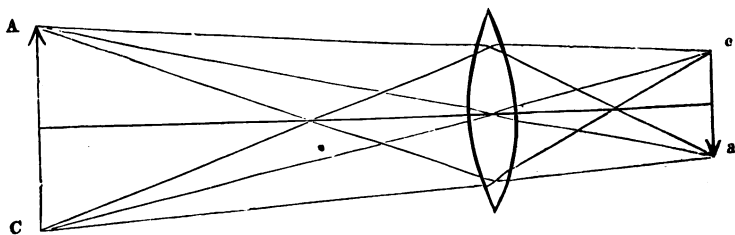
**What is an image of an object?**

It is a picture or reproduction of the form of an object in a plane where some of the rays of light from every point of the surface of an object are brought to a focus. The plane at which this occurs is known as the focal plane.

**What kind of images are known in physiological optics?**

The *real* or inverted and the *virtual* or upright. The real image (Fig. 27) is always on the side of the lens opposite to the object, and may be

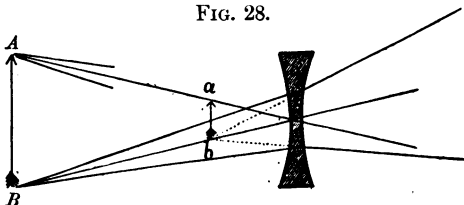
FIG. 27.



A C, object, upright; c a, real image, inverted.

projected on a screen. The virtual image is on the same side with the object, and is formed only in the mind of the observer. All images

FIG. 28.



A B, object, upright; a b, virtual image, upright.

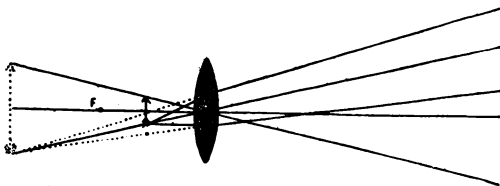
from concave lenses are virtual (Fig. 28), as are also those from convex lenses where the object is placed between the principal focus of the lens and the lens itself (Fig. 29).

**What is meant when rays of light are said to be projected?**

The faculty that the eye possesses of referring all rays of light which

enter it from an object to a point in space where the rays from all points of this object would, if prolonged, cross each other. The plane so formed may correspond with the object itself where the object is the direct source

FIG. 29.



Projection of Rays.

of the rays, or to an image if the rays from the object are refracted before they enter the eye.

### How are lenses classified or numbered ?

A lens is said to be a strong lens if it is of a high refractive power. There are a number of systems of notation for classifying lenses, the principal of which are the inch and dioptric systems.

### What is the inch system of notation ?

It is a system based on the inch as the unit of focal distance. It differs in various countries according as the unit is of greater or of less length. The French, German, and English inches are all of different lengths, which causes some confusion in the use of the inch system. The system consists in the employment of the unit as a numerator and the focal distance of the lens as the denominator; thus, a lens having a focal distance of 1 inch would be known as  $\frac{1}{1}$ ; having a focal distance of 4 inches, as  $\frac{1}{4}$ . This system of notation is being replaced by the dioptric system because of its uniformity.

### What is the dioptric system ?

It is based on the French dioptré as a unit. The dioptré is a lens whose focal distance is 1 metre, or 39.4 English inches, in length. A lens having a focal distance of 39.4 inches is known as a lens of 1 dioptré. A lens with 20 inches focal distance is known as a lens of 2 dioptries. A lens of a focal distance of 79 inches is known as a lens of  $\frac{1}{2}$  dioptré focal power.

### What are trial-glasses ?

They are sets of lenses, usually arranged in pairs, composed of sphericals and cylindricals ranging from  $\frac{1}{4}$  dioptré to 20 dioptries. They are marked in dioptries and in equivalents in inches, and are used for the

purpose of determining what glass is appropriate for the correction of any error of refraction.

**What is a dioptric surface?**

It is the surface between two transparent media of different densities.

## THE EYE AS AN OPTICAL INSTRUMENT.

**What is the dioptric system of the eye?**

The cornea, aqueous humor, crystalline lens, and vitreous humor.

**What is the index of refraction of each?**

Of the cornea, aqueous and vitreous humors it is, approximately, 1.3365 (Helmholtz); lens, 1.4480 (Aubert).

**What is the principal focal distance?**

The eye acts as a collecting or plus lens, and has a principal focal distance of 22.2 mm. (Helmholtz), 22.8 mm. (Landolt).

**What is necessary for distinct vision?**

The dioptric media must be transparent, the curvature of the surfaces must be regular, the location of the retina must correspond with the principal focal plane, and the optic-nerve tracts must be in perfect functional condition.

**What is the point of most acute vision in the eye?**

The fovea centralis. It is a small area of the retina, about  $\frac{1}{16}$  inch in diameter, situated  $\frac{1}{16}$  inch to the temporal side of the optic-nerve entrance. It is usually a very little to the outer side of the posterior pole of the globe.

**What is the optical axis?**

It is a line cutting the centre of the cornea and the posterior pole of the globe.

**What is the visual line?**

It is a line extending from the fovea centralis through the optical centre of the eye.

**How do you determine the acuteness of vision?**

Usually by the employment of test-cards on which are arranged letters of different sizes suitable to be seen at different distances by the normal eye. These cards are known as test-cards, and are made for near and distant vision. Those intended for distant vision are usually read at 20 feet, which is termed infinity; that is, a distance at which rays of light emanating from a point are virtually parallel when they enter the eye. To distinguish detail in an object it is necessary that rays of light from each of the different points on the object make a visual angle of 1 min-

ute. In the construction of a letter it is found that five points must be seen—the bars, which are three in number, and the spaces between, two in number. Hence the visual angle made by the rays of light from such an object must be 5 minutes, and this is the basis on which the letters on the test-cards are constructed. The test-cards usually employed are those devised by Snellen, and contain letters that should be read at from 15 to 200 feet. The distance at which the letters should be seen is used as the numerator, the distance at which the letter is seen as the denominator; thus, if a patient at a distance of 20 feet sees the letters that should be read at that distance, the vision is said to be  $\frac{20}{20}$ . If he can read only the letter that should be read at 100 feet, the vision is  $\frac{20}{100}$ . Test-cards constructed on the same principle are also used for the ordinary reading distance.

### **Can the refraction of the eye be changed at the will of the patient?**

Yes. A change can be made in the curve of the dioptric surface of the lens by which the refraction is increased. This is known as the power of accommodation.

### **By what means is the eye enabled to accommodate itself to see objects distinctly at different distances?**

By the contraction of the ciliary muscle, also known as the muscle of accommodation, the suspensory ligament which is attached to it becomes relaxed. The elastic properties of the lens produce a bulging forward of its anterior surface, symmetrically increasing the acuity of curvature of its surface. This shortens the principal focal distance of the dioptric system of the eye, and makes the focusing of rays of light coming from different distances within infinity possible.

### **What is meant by the term "amplitude of accommodation"?**

It is the distance between the nearest point at which objects may be seen distinctly and the farthest point at which objects may be seen. The far-point is known as the punctum remotissimum; the near-point, as the punctum proximum.

### **How is the near-point determined?**

By ascertaining, by actual measurement, how close to the eye an object may be brought and still be seen distinctly. The far-point may be determined by noting the distance, unimproved by a plus glass, at which an object may be seen distinctly.

### **How much of the power of accommodation is available for constant use?**

About two-thirds; in other words, it is necessary that the individual should hold about one-third of his amplitude of accommodation in reserve in order that he may do continuous work without distress.

**How is accommodation influenced by age?**

The amplitude of accommodation is shortened at the expense of the punctum proximum, which recedes, and after it has passed the point of 8 inches from the eye the condition is known as *presbyopia*, or the vision of the old, and glasses are required to make near vision easy.

*Amplitude of Accommodation at Different Ages (Landolt).*

Years.	Range of Accommodation.	Far-point.
10 . . . . .	14 D . . . . .	2 $\frac{3}{4}$
15 . . . . .	12 " . . . . .	3
20 . . . . .	10 " . . . . .	4
25 . . . . .	8.5 " . . . . .	4 $\frac{1}{2}$
30 . . . . .	7 " . . . . .	5 $\frac{1}{2}$
35 . . . . .	5.5 " . . . . .	7
40 . . . . .	4.5 " . . . . .	8 $\frac{3}{4}$
45 . . . . .	3.5 " . . . . .	11 $\frac{1}{2}$
50 . . . . .	2.5 " . . . . .	16
55 . . . . .	1.75 " . . . . .	23
60 . . . . .	1 " . . . . .	39.5
65 . . . . .	0.75 " . . . . .	
70 . . . . .	0.25 " . . . . .	
75 . . . . .	0 " . . . . .	

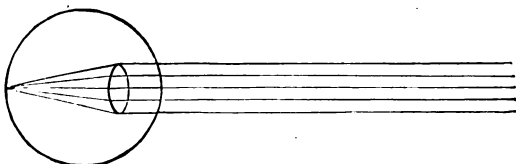
**What may be the refractive conditions of the eye when at rest regarding parallel rays of light?**

The rays of light may be focused on the retina; they may come to a focus in front of the retina or behind the retina.

**What terms are used to indicate these conditions?**

Where the rays fall at a focus on the retina the condition is termed *emmetropia* (Fig. 30); where the focus falls in front of the retina, *myopia*; where they fall behind the retina, *hypermetropia*.

Fig. 30.



Emmetropic Eye: parallel rays focused on the retina.

**What is meant by the term "ametropia"?**

Any condition of refraction other than emmetropia.

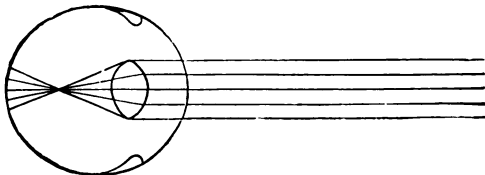
**What is emmetropia ?**

A condition of the eyeball in which the antero-posterior diameter is of the right length, the principal focus of the dioptric system at 22.2 mm.

**What is myopia ?**

It is a condition of the eyeball in which the antero-posterior diameter is elongated (Fig. 31). The condition may be congenital, acquired, spasmodic, or real.

FIG. 31.



Myopic Eye.

**What is congenital myopia ?**

It is a condition in which the eye, when formed, is too long in its antero-posterior diameter, or in which the dioptric system is more strongly refractive than in the normal eye.

**What is acquired myopia ?**

A condition in which there has been an antero-posterior elongation of the globe due to weakness of its coats. This form of myopia is marked by sclero-choroiditis of greater or less degree. It may supervene on a previous hypermetropia, emmetropia, or myopia. It is a diseased condition, and should always be regarded as an element of danger to vision.

**What is spasmodic myopia ?**

It is a form of myopia produced by spasmodic contraction of the muscle of accommodation, and may convert a hypermetropic or emmetropic eye into a myopic eye, or a myopic eye into an eye more highly myopic. The latter is not common.

**How may the actual condition be determined ?**

By the use of a mydriatic, which acts to paralyze the muscle of accommodation and to place the accommodative apparatus in a condition of rest.

**What is the course of the rays of light coming from the retina in the myopic eye ?**

Since the retina is placed at a distance greater than the principal focal point of the dioptric system from the optical centre, the rays of light coming from the retina converge as they pass from the myopic eye.



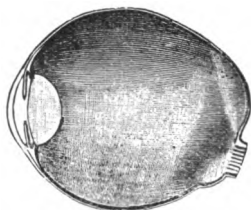
**What is the relation of punctum remotissimum (P. R.) and punctum proximum (P. P.) in myopia ?**

The amplitude of accommodation is not lessened, but P. R. is brought within infinity, and is found at the point where rays of light emanating from the retina come to a focus. P. P. is brought correspondingly nearer to the eye.

**What is the danger in high degrees of progressive myopia ?**

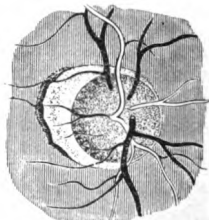
If the posterior elongation of the eye continues, the choroid and retina in the vicinity of the fovea centralis are much altered in structure; the extreme stretching and thinning that the retina is subject to induce detachment of this membrane in some cases. Vision becomes imperfect, and in high grades of myopia may be entirely lost. Hemorrhages

FIG. 32.



Section of a Highly-myopic Eyeball: the retina has been removed.

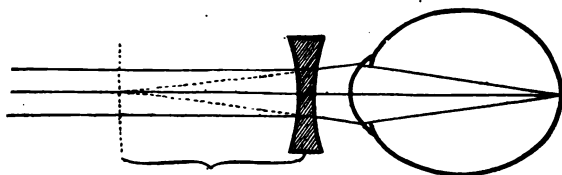
FIG. 33.



Myopic Crescent of a Small Posterior Staphyloma (Wecker and Jaeger).

sometimes take place into the retina and vitreous, and interfere largely with vision (Figs. 32, 33).

FIG. 34.



Correction of Myopia.

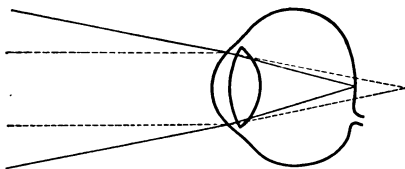
**How is myopia corrected ?**

By placing before the eye a concave or dispersing lens equivalent to the degree of myopia (Fig. 34).

**What is hypermetropia ?**

It is a condition of the eye in which the antero-posterior diameter is too short (Fig. 35). It is not the result of a disease-process, and need give no apprehension of loss of vision, as is the case in acquired myopia.

FIG. 35.



Hypermetropic Eye.

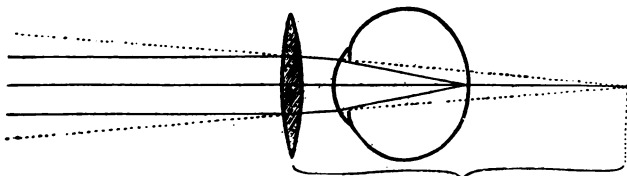
**What is the conduct of rays of light coming from the retina in hypermetropia ?**

Since the retina is placed at a shorter distance from the optical centre than the principal focal distance, the rays of light coming from the retina diverge as they pass out of the eye, the degree of divergence corresponding to the degree of the hypermetropia.

**What effect does this have on P. R. and P. P. ?**

In emmetropia rays of light emanating from the retina pass out of the eye parallel to each other, and P. R. is said to be at infinity. In hypermetropia, since the rays of light pass out in a divergent direction, P. R. is said to be beyond infinity to a degree represented by the lens which serves to bring the rays of light coming from the hypermetropic eye parallel to each other. P. P. is removed from the eye to a corresponding degree.

FIG. 36.



Correction of Hypermetropia.

**How is hypermetropia corrected ?**

By placing a convex glass before the eye of sufficient power to bring the far-point to infinity (Fig. 36).

**What is astigmatism ?**

It is a condition of the refraction of the eye in which rays of light passing through one of the principal meridians are refracted differently from those passing through the other meridian. Astigmatism is either regular or irregular.

**What are the principal meridians in an astigmatic eye ?**

The meridians of greatest and least refraction: they are usually at right angles to each other.

**What is regular astigmatism ?**

A condition in which the dioptric surfaces are regularly curved, but in which the refraction is different in the different meridians. It may be corneal or lenticular, or both. If corneal, the curvature of one meridian of the cornea is more acute than the curvature of the meridian at right angles to it. If lenticular, the curvatures of the lens vary in the same manner, or the lens is set at an angle with the visual line, which produces the same result.

**What are the varieties of regular astigmatism ?**

One meridian may be hypermetropic or myopic, while the other meridian is emmetropic. This is termed simple hypermetropic or simple myopic astigmatism. Both meridians may be hypermetropic or myopic, one to a greater extent than the other. It is then known as compound hypermetropic and compound myopic astigmatism, respectively. One meridian may be hypermetropic and the other myopic. This condition is known as mixed astigmatism.

**What is the cause of astigmatism ?**

It depends on the shape of the eye, and is not necessarily the result of diseased processes.

**How is astigmatism corrected ?**

By the use of cylindrical glasses, so adjusted as to correct the difference between the refraction of the principal meridians. To this may be added a plus or minus spherical glass, which may be employed when there is hypermetropia or myopia common to both meridians.

**What is irregular astigmatism ?**

It consists in the presence of facets or irregular surfaces over the cornea. These are usually due to ulcerative processes that have preceded.

**How is this detected ?**

Examination with the oblique illumination will serve to disclose a few smaller opacities in the majority of cases. Where this is not easy of demonstration the peculiar broken appearance of the image of the fun-

dus will suffice to make the diagnosis. The use of a Placido's disk will also aid in determining the nature of the condition.

### **What are the methods employed for the detection of errors of refraction ?**

They are subjective and objective. To the subjective method belong trial-lenses, Scheiner's test, Thompson's ametrometer, and others. The objective tests are Placido's disk, retinoscopy or skioscopy, the ophthalmoscope, and others. In testing the refraction of an eye, especially in younger people, it is always well to employ a mydriatic for the purpose of putting the accommodation at rest. If this is not done, tonic spasm may hide the real condition, and a proper correction of the error of refraction cannot be obtained. Atropine, homatropine, or duboisine may be used.

### **How is the refraction determined by the use of the trial-lenses ?**

The patient is placed at a distance of 20 feet from the trial-cards, which are sufficiently illuminated. Glasses are placed before the eye (each eye should be tested separately), beginning with the plus lenses. If vision is not blurred when a weak plus lens is placed before the eye, the far-point must be beyond infinity, and the condition must be one of hypermetropia. The plus glass is increased until the test-letters begin to be blurred. For simple hypermetropia the strongest glass that gives distinct vision represents the amount of hypermetropia, and the strongest glass that gives distinct vision immediately after the eye has recovered from the mydriatic should be prescribed. If the plus glass blurs the vision, a weak minus should be substituted, and a stronger minus glass placed successively before the eye until a clear image is formed on the retina. The weakest glass that will correct the condition is the one that should be given. In order to correct astigmatism a minus or plus cylinder may be tried in the various meridians, and the glass selected which will give the most distinct vision. Scheiner's test is based on the fact that rays of light entering two small apertures, passing into the eye, fall on the same point on the retina in the emmetropic eye, but in the hypermetropic or myopic eye the points are duplicated, since the rays of light impinge upon the retina before they come together in the hypermetropic eye and after they come together in the myopic eye. Thompson's ametrometer consists in the adjustment of two small flames so that they can be changed to correspond to the different meridians of the eye. The circles of diffusion produced by these lights in the various forms of ametropia indicate the refractive error. Scheiner's and Thompson's tests are but little used, because of their inaccuracies.

### **What are the subjective methods ?**

Placido's disk consists of a circular plane surface 23 cm. in diameter. In its centre is an opening of about  $\frac{1}{2}$  inch in diameter, which is surrounded by concentric white and black rings, each of about  $\frac{1}{2}$  inch in

width. Extending backward from this central opening is a short tube of the same diameter. This instrument is employed by placing the patient's back to the light and directing him to look into the opening in the centre of the disk, the disk being placed at about a foot from the patient's face and parallel to the plane of the face. On looking through the tube the observer sees a reflection of the disk from the cornea of the patient. If the corneal surface is regular in its curvature, the image of the circles on the disk will appear regular. If astigmatism is present, the image will become oval, its shortest diameter corresponding to the meridian of most acute curvature. If irregular astigmatism is present, an irregular image of the disk will be produced. This test is serviceable only to indicate the condition of the cornea regarding its curvature.

## THE OPHTHALMOSCOPE.

### What is the ophthalmoscope ?

It is an instrument devised for the purpose of examining the interior of the eye. It was discovered by Helmholtz in 1851. As now constructed it consists of a mirror perforated in its centre, and so arranged that lenses may be rotated into place behind the central perforation. The mirror acts as a source of light with which to throw light into the interior of the eye. A portion of the light that enters the eye is reflected from the retina and choroid, passes out through the pupil, and passes through the small aperture in the centre of the mirror, entering the eye of the observer. The mirror of the modern ophthalmoscope is usually concave, with a principal focus of from 7 to 13 inches, and it is so arranged that plus and minus lenses can be rotated into position behind the small central opening. The ophthalmoscope is used to determine the refraction of the eye as well as to examine into the condition of the interior of the eye.

### How is the ophthalmoscope employed ?

There are two methods for its employment, known as the direct and the indirect. For the direct method the source of light, which may be a lamp or Argand burner, is placed at the side and back of the patient on a level with the eyes. The light is reflected into the eye by the mirror, the observer occupying a position in front of the patient. If both eyes are emmetropic and the accommodation at rest in both, a clear picture of the fundus of the patient's eye may be seen by the observer. If hypermetropia exists, the fundus may also remain clear: the addition of a plus lens will render the image of the fundus more distinct, and plus lenses should be placed back of the aperture until the image of the fundus begins to blur very slightly. This last lens indicates the degree of hypermetropia present. If myopia exists, a clear image of the fundus of the eye will not be obtained until minus glasses are placed behind the aperture in the mirror of sufficient strength to render parallel the

rays of light that come from the eye of the patient. The weakest glass that will give a clear image of the interior is the approximate estimate of the myopia present.

### **How is this method applied to astigmatism ?**

In the determination of refraction with the ophthalmoscope the small vessels in the region of the fovea centralis, or the fine stippled appearance of the fundus in the region of the posterior pole of the eye, should be selected as the object of which to obtain a clear and distinct image. If astigmatism is present, the small vessels in one meridian will be seen to be more distinct than vessels of a similar size which pass in another direction. The strongest plus or the weakest minus glass with which the vessels in the meridians of greatest and of least curvature can be seen indicates the refraction of these two meridians, and the difference between the glasses required for the two principal meridians indicates the degree of the astigmatism.

### **What is the value of the ophthalmoscope in determining refraction ?**

If the accommodation of the patient and of the observer is relaxed, it may be relied upon to give results that are approximately correct. If the accommodation is not under control, it is liable to great error.

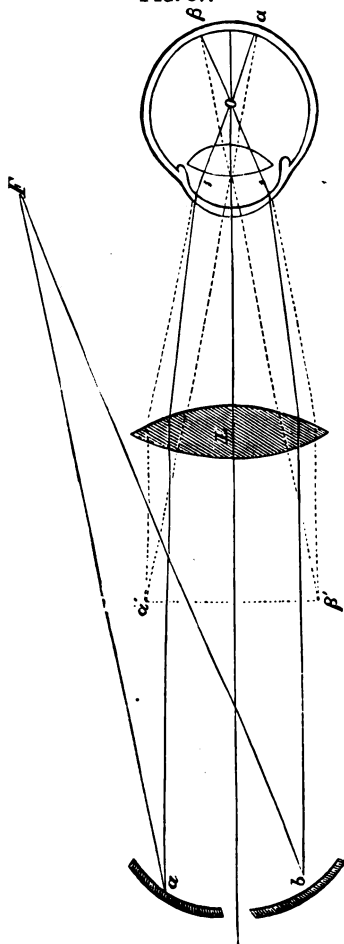
### **What is the indirect method for the use of the ophthalmoscope ?**

It consists in placing a biconvex lens of the focal distance of  $2\frac{1}{2}$  to 3 inches between the eye of the patient and the ophthalmoscope employed by the observer at its focal distance from the patient's eye (Fig. 37). The ophthalmoscope, held at a distance of 12 to 14 inches from the observed eye, is made to reflect the light through the lens and into the eye of the patient. The rays of light which return from the eye pass again into the lens, and are brought to a focus at a point corresponding to the principal focal point of the lens. This area of image is visible to and is seen by the observer. Since it is desirable that the accommodation should be at rest in all work with the ophthalmoscope, many oculists employ a lens for a focal distance of 10 inches behind the ophthalmoscopic mirror, for the purpose of rendering the rays of light parallel as they enter the eye from the aerial image. The direct method in the use of the ophthalmoscope produces an image by projection, a virtual upright image. The ophthalmoscope by the indirect method produces a true aerial image, which is inverted. The indirect method is employed but little for the purpose of determining refraction, and cannot be depended upon to give an accurate estimation of the degree of refraction.

### **What is retinoscopy or skioscopy ?**

It is the study of the conduct of the disk of light which fills the pupil when light is reflected into the eye by a plane or concave mirror. The observer's eye is so placed that it may intercept the rays of light reflected

Fig. 37.



from the fundus. The source of light is placed behind and a little above the patient's head. The observer stations himself at a distance of 1 or  $1\frac{1}{2}$  m. in front of the patient, and, holding the mirror before his eye, reflects the light into the eye of the patient. A circular reddish disk will be seen to fill the pupil, which moves in various directions as the mirror is rotated on its axis. If the patient is emmetropic, on movement of the mirror the reddish disk disappears suddenly, apparently leaving the pupil in all its parts at about the same time. If a plane mirror is used and the eye is hypermetropic, the disk of light moves in the same direction across the area of the pupil with the mirror, followed by a relatively deep shadow. If the eye is myopic, the image moves in the opposite direction, also followed by a shadow. In determining the refraction of the eye a plus or minus lens is placed before the eye until the shadow conducts itself as in emmetropia. The glass which produces this condition is approximately the one required to correct the error of refraction. In examining the eye by retinoscopy the different meridians of the eye must be tested separately. In this way astigmatism, if any exists, may be detected, the difference between the glass required to produce an emmetropic condition in different meridians at right angles with each other being the estimate of the astigmatism present. This method of examination determines the total astigmatism.

### What is the ophthalmometer of Javal and Schiotz?

It is an instrument devised for the purpose of determining the curvature of the cornea in its various meridians. It is so constructed that the

difference between the curvatures of the principal meridians may be determined and indicated in dioptries. By this instrument the corneal astigmatism may be accurately estimated, but the total astigmatism when lenticular astigmatism is present cannot be determined. It is an aid, in a limited sense, for the determination of refraction.

#### **What is the ultimate test for refraction ?**

The trial-lenses must be depended upon for determining the glass which is best suited for the correction of errors of refraction in every case, and the prescription must be given according to the results arrived at by use of these lenses.

## **THE MUSCULAR APPARATUS.**

#### **Give the names of the muscles that are attached to the exterior of the eye.**

These are six in number: four recti muscles, known as the internal, external, superior, and inferior recti; two oblique muscles, known as the superior and inferior oblique.

#### **What are their origin and insertion ?**

All of the muscles of the eye, except the inferior oblique, take their origin from the apex of the orbit encircling the optic-nerve canal. The recti muscles extend forward and are inserted as follows: The internal rectus is inserted into the sclerotic at a distance of about 6 mm. from the sclero-corneal junction by a thin spreading tendon which extends from the lower to the upper tangent of the perpendicular meridian of the cornea. The external rectus is inserted in a like manner at the outer side of the globe 7 to 8 mm. from the sclero-corneal junction. The superior rectus is inserted in a like manner into the superior portion of the sclerotic about 7 mm. from the sclero-corneal junction. The inferior rectus has a similar insertion into the lower part of the sclerotic. The superior oblique passes forward to the upper inner angle of the orbit, where it passes through a tendinous pulley, is reflected on to the globe below the superior rectus, and is inserted into the sclerotic a little back of the equator of the globe at the upper margin of the external rectus. The inferior oblique takes its origin from the inner angle of the margin of the orbit, passes backward and outward beneath the inferior rectus, and is inserted into the sclerotic slightly back of the equator and beneath the external rectus.

#### **What is the source of the motor nerve-supply to these muscles ?**

The superior, inferior, and internal recti and the inferior oblique are supplied with motor nerve-filaments from the motor oculi; the superior oblique, from the fourth cranial nerve; the external rectus, by the sixth cranial or abducens.



### **What is the action of the extrinsic muscles of the eye ?**

The external and internal recti muscles produce the lateral movements of the eye on its horizontal plane. The superior rectus rotates the cornea upward and inward, turning the perpendicular meridian of the cornea inward above; the inferior rectus rotates the cornea downward and inward, rotating the perpendicular meridian of the cornea inward below; the superior oblique rotates the cornea downward, and turns its perpendicular meridian inward above; the inferior oblique rotates the cornea upward and outward, and turns its perpendicular meridian inward below. In the production of the lateral movements the external and internal recti alone are involved. In upward movement the superior rectus and the inferior oblique are employed; in downward movements, the inferior rectus and the superior oblique.

### **What are the associated movements of the globes ?**

They are the movements which the eyes make together for the accomplishment and continuation of binocular single vision. These movements are very complex. The one of greatest consequence is that of convergence, which is employed for seeing all objects within infinity. With it are closely associated the accommodative effort and the movements of the pupil. Convergence assists accommodation, and on strong convergence the pupils become contracted.

### **What is necessary for binocular single vision ?**

The visual axis of each eye must be directed toward the same point, and the image of the object must fall on a corresponding part of the retina of each eye. The accomplishment of this is termed binocular fixation. The sensorium interprets the images as one, and single vision is the result. Deviation of the visual lines produces diplopia. The deviation may be very slight or it may be very pronounced. In the slighter forms the images may be fused by an effort on the part of the muscles; in the decided forms the image is either disregarded or remains double. The deviation may be in any direction.

### **How may double images be united ?**

If double images are present, are of the same color, and are near each other, an effort is made on the part of the eye-muscles, entirely without conscious volition, to place the visual lines in the direction necessary for the fusion of the images, and diplopia will be overcome.

### **How can the effort be detected ?**

If a prism with the base up or down of sufficient strength is placed before one eye, and a red glass is placed before the other eye, double images are produced, and because of the change in the color of the images and the forced perpendicular displacement the effort at fusion is reduced to a minimum. If there exists a tendency to deviation in the internal or external recti muscles, the images will be displaced laterally.

If toward the interni, the image seen through the red glass will correspond to the side of the eye over which it is placed. If toward the externi, the images will be crossed. Where the images are found on the side corresponding to the position of the eyes they are said to be homonymous; if crossed, heteronymous.

### **What are the varieties of strabismus or squint?**

Apparent or false, concomitant, and paralytic.

### **What is apparent strabismus?**

It is a form in which the visual lines and the optic axes do not correspond. The visual line usually cuts the cornea to the inner side and a little below the centre of the cornea, forming an angle with the optic axis which is known as the angle  $a$ . When, as in some cases of hypermetropia, the visual line passes to the inner side of the optic axis, the angle  $a$  is large and the eyes appear as though they diverged. If, as in some cases of high degrees of myopia, the visual line passes to the outer side of the optic axis, the eyes appear to converge. In the first case the angle  $a$  is said to be positive; in the second case the angle  $a$  is said to be negative.

### **How do you differentiate between apparent or false and true strabismus?**

If the eyes are caused to fix on an object, and are then alternately covered and uncovered, the uncovered eye describes a movement when it first sees the object if squint be present. If the squint is only apparent, the eyes remain stationary.

### **What is concomitant strabismus?**

A condition in which the tendency to deviation is real, but in which the normal degree of rotation of the globe is present and the conjugate movements of the eye unimpaired. There is no loss of muscle-power. Double images are seldom observed, as the mind has become accustomed to disregard the image formed on the squinting eye.

### **What are the forms of concomitant strabismus?**

In regard to constancy they are divided into periodic, alternating, and absolute; in regard to direction, into convergent, divergent, upward, and downward squint. Periodic strabismus is a condition in which the squint obtains only at intervals. Alternating strabismus is a condition of constant squint, sometimes with one eye, sometimes with the other. Absolute strabismus is a form where one eye always squints. The terms convergent, divergent, upward, and downward squint explain themselves.

### **What are the causes of concomitant strabismus?**

In the hypermetropic eye the near-point is carried to such a distance from the eye that the effort at accommodation is reinforced by the effort at convergence, and the tendency to convergence becomes confirmed in

many cases; thus, at first periodic strabismus of the convergent variety becomes manifest. As the case goes on without the correction of the hypermetropia the squint becomes alternating, and finally is confined to one eye. Hypermetropia is instrumental in producing probably 90 per cent. of the cases of convergent strabismus. Divergent strabismus is probably also produced by an unconscious effort on the part of the individual to avoid using convergence, as the near-point is already too near to the eye in the myope, the individual whose class presents the greater number of cases of concomitant divergent strabismus. Inequality in the vision of the eyes, irregularities in the surface of the cornea, or opacities of the cornea, cataractous conditions of the lens, and other conditions in which imperfect vision obtains, serve to produce a certain number of cases of strabismus of all varieties.

#### **What is meant by the term "heterophoria"?**

A tendency to the deviation of visual lines which does not result in decided strabismus, but which, from the effort on the part of the eye-muscles to properly adjust the eyes for the visual acts, often produces headache and other disturbances of a very annoying character.

#### **How is this detected?**

The test for the detection of fused double images reveals the presence of this condition, and its amount may be measured by the employment of prisms which serve to superimpose or to bring the images on the proper level, as the case may be.

#### **What is the treatment of concomitant strabismus and of heterophoria?**

When symptoms of the production of strabismus first become manifest a correction of the error of refraction may often prevent its development. Appropriate glasses should be fitted to the eyes and the patient made to wear them constantly. Strabismus which has already become alternating may sometimes be corrected by this simple procedure. Where this will not suffice operative procedure is usually necessary.

#### **At what age does strabismus make itself manifest? and what are its effects on vision?**

It usually develops in children between the ages of two and eight years, or during the time in which near vision is beginning to be employed very constantly by the individual. If the eyes are tested shortly after the first evidence of strabismus is manifest, the vision seems to be about the same in each eye. When the strabismus is confirmed it is found that the squinting eye has less acute vision, as a rule, than its fellow, and if squint has been present for a number of years the vision in the squinting eye becomes greatly reduced. A strabismus established at the age of five often shows vision reduced to counting fingers at a few feet when the individual reaches adult life. This loss of vision is termed "amblyopia from non-use," as it is thought that by disregarding the im-

age formed on the retina of the squinting eye the acuity of vision does not develop.

### **When should the operation for strabismus be performed ?**

Many operators are of the opinion that the patient should not be operated upon before he has reached the age of six or seven years; others are of opinion that it should be corrected by operative measures, if necessary, as soon as the strabismus has become confirmed. Since it has been observed that strabismus sometimes corrects itself before the individual reaches the age of ten or twelve years, and since there is greater danger of over-correction by operation in young children, it is probably wiser to wait until there can be no doubt of the permanent nature of the condition before operating.

### **What are the operations for the correction of strabismus ?**

Tenotomy of the muscle acting in the direction of the squint, and in some cases advancement of the tendon of its opponent, are necessary.

### **What instruments are necessary in the operation for strabismus ?**

A stop speculum, fixation forceps, strabismus scissors, two strabismus hooks, thread, needles, and needle-holder.

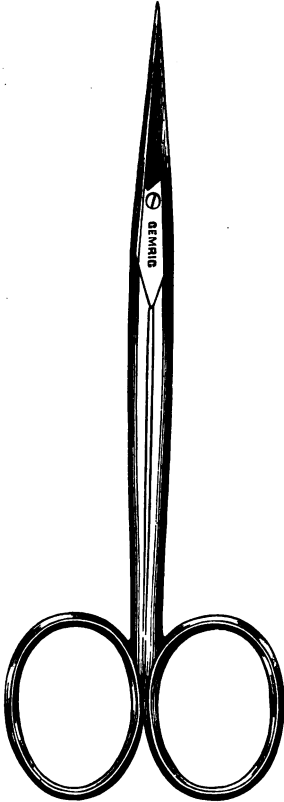
### **Describe the operation of tenotomy for correction of strabismus.**

The operation may be subconjunctival or open. The subconjunctival operation is done as follows: Cocaine or ether may be employed. The stop speculum is introduced to separate the lids, and the conjunctiva and subconjunctival tissues are grasped by the fixation forceps at the lower margin of the tendon at its insertion. This will be found for the internal rectus at a distance of 6 mm. from the sclero-corneal junction, at the inner lower part of the eye, at an angle of 45° from the horizontal meridian of the cornea, and at 8 mm. for the externus on the same angle to the outer side. With the scissors the conjunctiva and subconjunctival tissues are divided with one snip, and the opening continued along the sclerotic far enough to divide the thin aponeurosis of connective tissue which is attached to the borders of the tendons. A strabismus hook is then passed through the small opening, the point always being pressed against the sclerotic, and brought up beneath the tendon of the muscle. The fixation forceps are removed, and the tendon divided between the sclerotic and the strabismus hook close to the sclerotic. The hook should be passed again, to be sure that all fibres of the tendon are divided. When this has been accomplished, the strabismus hook may be drawn to within 1 mm. of the margin of the cornea beneath the conjunctiva.

### **How is the open operation performed ?**


The conjunctiva is seized with the fixation forceps over the centre of the insertion of the muscle, and a vertical incision made through the conjunctiva at this point, running parallel with the perpendicular meridian of the cornea when a tendon of the lateral muscles is to be

FIG. 38.



Strabismus Scissors.

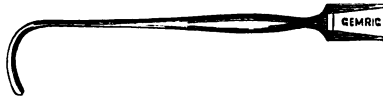FIG. 39.



Fixation Forceps.

divided. The tendon at the middle of its insertion is then seized and a small opening made through it. The strabismus hook is then passed so as to catch up either the upper or lower half of the tendon, and each is divided successively. The conjunctival opening in the subconjunctival

FIG. 40.



Strabismus Hook.

and in the open operations is usually closed with sutures to prevent infection.

**What effect may be produced by the operation of simple tenotomy?**

A deviation of from  $13^{\circ}$  to  $20^{\circ}$  may often be corrected by simple tenotomy. It often occurs that the operation must be divided between the two eyes, as excessive motility inward often exists in each eye. The extent of the operation may be somewhat limited, a small effect being produced by simple division of the tendon; a greater effect by division of the thin aponeurosis of Tenon's capsule attached to the borders of the tendon.

**What is the operation for advancement of the tendon of a muscle in strabismus?**

This operation is performed for the purpose of exaggerating the effect of a simple tenotomy. The open operation of the opponent of the tenotomized muscle is performed. The conjunctiva next to the cornea is dissected up and sutures are passed. These are three in number—a central, one above, and one below, each passing through the margins of the muscle, the conjunctiva, and Tenon's capsule, beginning at a distance usually of  $\frac{1}{4}$  inch from the insertion of the tendon. The sutures are then tied, after first having removed a small piece of the tendon. The middle is first tied and tightened, and then the lateral sutures, until the desired effect is reached.

**What are the varieties of heterophoria?**

Esophoria, or deviation inward; exophoria, or deviation outward; hyperphoria, or deviation upward.

**What is the treatment of heterophoria?**

Not infrequently the condition may be remedied by a simple correction of the error of refraction. When this does not suffice, an attempt may be made to relieve the patient by combining a prism with the lens of proper strength to correct the deviation, with the base placed outward in esophoria, inward in exophoria, and downward in hyperphoria. If the heterophoria is excessive, it becomes necessary to perform a partial or complete tenotomy of the stronger muscles, and in some cases to advance the opponent.

**What is paralytic strabismus ?**

A deviation of the eyes caused by paralysis of one or more muscles.

**How may we differentiate between concomitant and paralytic strabismus ?**

If the eyes are made to follow the movements of an object in various directions, in concomitant strabismus both eyes will move to the same extent and their movements will not be restricted in any direction. In paralytic strabismus the movement of the affected eye will be restricted in the direction of the action of the paralyzed muscle. If in concomitant strabismus the fixing eye is covered and the squinting eye is caused to fix the object, it will be found that the deviation of the first eye is the same as that of the squinting eye. In paralytic strabismus the deviation of the non-squinting eye, when it is covered and the squinting eye made to fix the object, is greater than that of the squinting eye. In other words, the secondary deviation in concomitant strabismus equals the primary deviation; in paralytic strabismus the secondary is greater than the primary.

**What is the cause of paralytic strabismus ?**

Traumatism, syphilis, tabes dorsalis, tumors and hemorrhages in certain parts of the brain, diphtheria, inflammatory processes at the apex of the orbit, and peripheral neuritis resulting from poisoning with alcohol, tobacco, etc.

**How is paralytic strabismus classified ?**

Usually according to the nerve affected; sometimes according to the muscles or muscle affected.

**What are the symptoms in paralysis of the third or motor oculi ?**

This nerve supplies the levator palpebræ superioris, the internal, inferior, and superior recti, and the inferior oblique. When these are paralyzed the lid droops and the eye turns outward and a little downward. The sphincter of the iris is supplied by the third, and in paralysis of this nerve the pupil becomes dilated. The drooping of the lid often causes such pronounced closure of the eye that the eyeball itself can be seen with difficulty. Diplopia exists, the images being crossed. The image of the squinting eye is on the opposite side and slightly higher, its apex turning a little inward above. The outward and downward movements are preserved.

**What are the symptoms in paralysis of the sixth or abducens nerve ?**

As only the external rectus is affected, the eye turns inward, producing a convergent strabismus. Double images result, the image of the affected eye being on the same side or homonymous. Diplopia is

most marked when the object is passed in the direction of the action of the paralyzed muscle. The image is upright.

**What are the symptoms in paralysis of the superior oblique ?**

Since this muscle helps to rotate the cornea downward and outward, the cornea passes upward and a little inward. The diplopia is most marked in the direction of the action of the muscle, as is the rule in all cases of paralysis. The images are homonymous, the apex of the image inclining a little inward above.

**What is the treatment of paralytic strabismus ?**

*Treatment* must be directed to a correction of the cause. Since syphilis is the most frequent cause, its possible influence must be carefully inquired into and antisyphilitic remedies given if it exists. Paralysis from diphtheria usually follows some two or three weeks after the pseudo-membrane in the pharynx has disappeared, and generally disappears spontaneously in from three to six weeks. Operative procedure is only permissible when the paralysis has lasted for a long time and is not complete.

**What is ophthalmoplegia externa ?**

A condition where all the extrinsic muscles of the eye are paralyzed.

**What is ophthalmoplegia interna ?**

A condition in which the internal muscles of the eye—*i. e.* the muscle of accommodation—and the sphincter of the iris are paralyzed. These are supplied from the motor oculi, but may become paralyzed independently of the extrinsic muscle.

**What is the treatment of ophthalmoplegia externa and interna ?**

*Treatment* must be directed to the cause. It is often unsatisfactory regarding the external muscles, but recovery of function of the internal muscles is the rule.

## DISEASES OF THE ORBIT.

**What are the contents of the orbit ?**

The eyeball, Tenon's capsule, the ocular muscles, the optic nerve, nerves, blood-vessels, and the orbital fat. The orbital fat is a cushion of adipose tissue which assists to support the globe in its position.

**What inflammatory diseases is the orbital tissue subject to ?**

Orbital cellulitis is the principal form. It is produced by traumatism, erysipelalous infection, and also at times accompanies la grippe.

**What are the symptoms of orbital cellulitis ?**

The patient usually experiences considerable pain, which he refers to the side of the head and orbit. The eye becomes prominent, and sooner



or later, as the inflammation proceeds, the pus which usually forms finds an opening into the conjunctival sac or on the surface of the lids.

#### **What is orbital periostitis?**

An inflammatory condition affecting the periosteum, usually at the margin of the orbit. Caries of the bone in the vicinity involved sometimes occurs, and a suppurating sinus opening on to the face may result, and continue to discharge pus and débris for a long time.

#### **What is the treatment of these two affections?**

In orbital cellulitis free drainage by incision must be established at the earliest possible moment, escape being given to all pus that may form. Orbital periostitis is treated as periostitis is in other parts of the body.

#### **What tumors are found in the orbit?**

Solid and cystic tumors are met with. Sarcoma, carcinoma, neuroma, exostoses, and polypoid growths from the ethmoid cells are the principal forms.

#### **What is the treatment of tumors of the orbit?**

Removal at the earliest possible date.

#### **What are the cystic tumors met with in the orbit?**

Echinococcus, dermoid and cystic tumors.

The *treatment* employed in these cases is evacuation of the contents and removal or destruction of the walls.

#### **What is pulsating tumor of the orbit?**

It is usually due to an arterio-venous intercommunication taking place in the cavernous sinus, whereby the veins and arteries in the orbit become abnormally distended and pulsation ensues. It is usually the result of traumatism.

#### **What is exophthalmic goitre?**

It is a disease due to a disturbance in the sympathetic nervous system in which the action of the heart is greatly accelerated, the thyroid gland becomes enlarged, and the eyes protrude. The upper lid becomes somewhat retracted, particularly when the patient looks downward, making the appearance of the projection of the globe more pronounced. In exaggerated cases it becomes impossible to close the lids over the globe, and ulceration of the cornea from exposure results.

The *treatment* is directed mainly to the general condition. If ulceration from exposure is liable to ensue, the eye may be protected by the employment of a bandage, or the palpebral fissure may be made somewhat shorter and narrower by freshening the edges of the lids at the outer canthus, stitching them together, and permitting them to heal.

## REMEDIES AND FORMULÆ.

**What are the antiseptics used in the treatment of diseases of the eye ?**

Mercuric bichloride is the most serviceable. Hydrogen dioxide in a two-volume solution may be employed in suppurative processes with good results. Creoline in a 1 per cent. solution may be used, but is somewhat irritating to the conjunctiva. Chlorine-water is also effectual in suppurative conditions. Nitrate of silver is an excellent antiseptic as well as stimulant and astringent. Alcohol and boiling water for the cleansing of instruments are superior to carbolic acid. Mercuric bichloride should be used according to the following formula :

R.	Mercuric bichloride,	1 part ;
	Sodium chloride,	5 parts ;
	Aquæ,	2000 to 12,000 parts.—M.
Sig.		

The stronger solutions may be employed for cleansing the lids and adjoining parts, the weaker solutions for dropping into the conjunctival sac and for protracted bathings of the eye.

Boric acid is of little account as an antiseptic, but is aseptic, and may be used to advantage to cleanse the eye at frequent intervals in suppurative conditions in solutions of 2 to 3 per cent.

**What astringent solutions are employed in diseases of the eye ?**

The following formulæ will be found useful :

R.	Nitrate of silver,	gr. j-xx ;
	Water,	℥j.—M.
Sig.		

Solutions of nitrate of silver are very valuable in all cases where purulent or muco-purulent discharge is taking place from the eye. It should be applied by the surgeon, and the strength of solution used modified according to his judgment. In mild cases of muco-purulent conjunctivitis applications of a weaker solution made at intervals of twenty-four to forty-eight hours are very beneficial. In severe cases applications of a stronger solution made at more frequent intervals must be employed.

R.	Sulphate of zinc,	gr. j-ij ;
	Distilled water,	℥j.—M.
Sig.		

This is a stimulating and astringent collyrium, and may be employed in

the subacute and chronic stages of conjunctivitis to drop into the eye two or three times daily.

R. Alum,	gr. j-ij;
Distilled water,	ʒj.—M.
Sig.	

To be used as the formula for zinc.

The sulphocarbolate of zinc, sulphate of copper, acetate of lead, and chloride of zinc may be used in the same proportions and in the same manner as the sulphate of zinc and alum.

A stimulant astringent of some value is a solution of tannic acid in glycerin in the proportion of 1 part to 8. This is used particularly in granulated lids by painting it freely on the everted lid once or twice daily.

### **What are the mydriatics, and how are they used?**

Mydriatics are medicines employed to dilate the pupil. Chief among them are atropine, homatropine, daturine, duboisine, hyoscyamine. Atropine is the principal one used, and is employed in the following solution:

R. Sulphate of atropine, 1-4 gr.;	
Distilled water,	1 oz.

One or two drops are dropped into the eye at intervals of one to twelve hours. It is used for the purpose of dilating the pupil in cases of iritis and of paralyzing the accommodation in the determination of errors of refraction.

In some individuals the lids are particularly susceptible to the irritating influence of atropine. In these cases it must be discontinued and some other mydriatic employed in its place. Care must be taken in the use of atropine not to produce the systemic poisonous effects. A few drops of the stronger solution placed in the conjunctival sac of a child suffices in some cases to cause the flushed face, dry fauces, and general distressed condition characteristic of atropine-poisoning. The passage of atropine in solution through the nasal duct into the nose and throat, in patients whose cases require the frequent use of atropine, produces a dryness of the fauces which is often very annoying. This condition may be obviated by making pressure over the lachrymal sac for a few minutes immediately after the instillation of the drug.

Homatropine in a 1 to 2 per cent. solution is preferable for transient dilatation of the pupil. Its effects disappear after twenty-four hours, while those of atropine and the other mydriatics last from five to seven days.

**What are myotics ?**

They are remedies employed to contract the pupil. The principal ones are eserine and pilocarpine :

R. Eserin. sulph., gr. ss to iv ;  
 Distilled water, ℥j.—M.  
 Sig.

This remedy is used chiefly for the purpose of reducing the tension of the globe in glaucoma and in glaucomatous conditions. It is also employed in ulcerative processes of the cornea. Eserine in a strong solution sometimes produces iritis, and should be employed with caution. Pilocarpine also acts to contract the pupil, but must be used in about twice the strength of eserine.

**What local anæsthetics are employed in diseases of the eye ?**

The one of most value is cocaine, which is used in the form of the hydrochlorate, and is employed in a solution of 2 to 10 per cent. in distilled water. The anæsthesia is produced by instillations of one to three drops into the conjunctival sac at intervals of from three to ten minutes. The anæsthetic effect continues for from ten to thirty minutes, amply sufficient for the minor operations performed on the eye.

**What ointments are employed in treating diseases of the eye ?**

There are very many of these employed for various purposes. The following formula is much used in blepharitis marginalis and in phlyctenular affections :

R. Yellow oxide of mercury, gr. ij ;  
 Vaseline, ℥j.—M.  
 Sig.

Apply to the margin of the lids twice daily, or rub into the eye once or twice daily, as may be required.

An ointment of boric acid, 10 per cent., in vaseline is very serviceable, to be introduced between the lids in cases of burns from lime or other escharotic.

Ointments of the sulphate of copper, of eserine, and of atropine are at times employed to effect the same purpose for which their solutions are used.

**What powders are employed in treating diseases of the eye ?**

Calomel, which is used as an antiseptic and as a stimulant in indolent ulcers of the cornea, in phlyctenular keratitis, in interstitial keratitis, and in a few other conditions ; boric acid, sometimes employed to dust into the eye in cases of conjunctivitis ; iodoform and iodol, for the dressing of wounds. Jequirity is employed to produce an inflammatory process in

the conjunctiva in trachoma, for the purpose of effecting the removal of the trachoma-granules.

**What medication is employed in the solid form ?**

The crystals of the sulphate of copper and of alum, made smooth and of proper shape, are employed for the treatment of granulated lids. The method of employment has been spoken of under the head of the Treatment of trachoma. The solid stick of the nitrate of silver is employed in certain forms of ulcers of the lids, and by some oculists in the treatment of purulent conjunctivitis. The mitigated stick of the nitrate of silver is employed in a similar manner.

# THE EAR AND ITS DISEASES.

## ANATOMY OF THE EAR.

### What constitutes the external ear ?

The external ear consists of the auricle and the auditory canal.

### Name the different portions of the auricle.

(*a*) Helix; (*b*) antihelix; (*c*) concha; (*d*) tragus; (*e*) antitragus; (*f*) lobule; (*g*) fossa of the helix; (*h*) fossa of the antihelix. (See Fig. 41.)

### Name the muscles of the auricle.

The muscles of the auricle are divided into two sets: The first set are those which connect it with the head, and comprise the *attollens aurem*, *atrahens aurem*, and *retrahens aurem*.

The second set connect the various parts of the auricle, and comprise the *helicis major*, *helicis minor*, *tragicus*, *antitragicus*, *transversus auriculæ*, and *obliquus auris*.

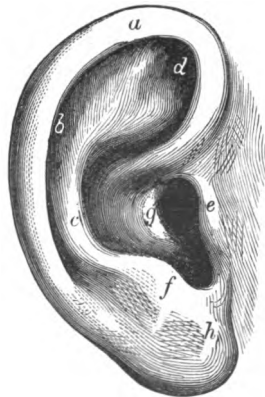
### Describe the external auditory canal.

The external auditory canal consists of two portions, a cartilaginous and a bony portion. (See Fig. 42.) The cartilaginous portion is a continuation of the cartilage of the concha and tragus prolonged inward. The cartilage is deficient in the upper and posterior portion, where there is a layer of fibrous membrane. There are two or three deep fissures in the cartilage known as the *incisuræ Santorini*. (See Fig. 43.) The bony portion is longer than the cartilaginous, and terminates at the *membrana tympani*.

### What arteries supply the meatus ?

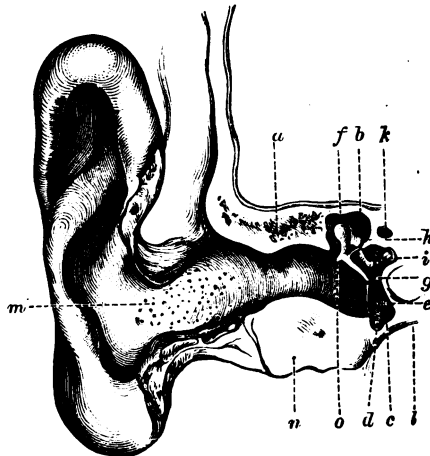
Branches of the posterior auricular, internal maxillary, and temporal.

FIG. 41.



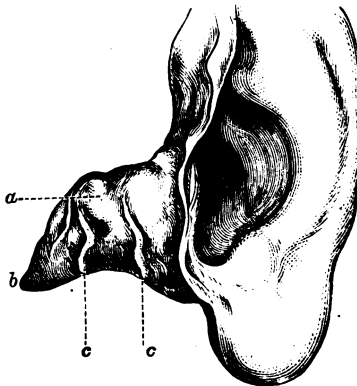
The Auricle: *a*, helix; *c*, antihelix; *b*, fossa of the helix; *d*, fossa of the antihelix; *e*, tragus; *f*, antitragus; *h*, lobule; *g*, concha.

FIG. 42.



Vertical Section of the External Auditory Canal, Membrana Tympani, and Tympanic Cavity, viewed in front (Politzer): *a*, upper osseous wall of the canal; *n*, lower osseous wall of the same; *b*, tegmen tympani; *c*, osseous floor of the tympanic cavity; *d*, tympanic cavity; *e*, membrana tympani; *f*, head of the malleus; *o*, short process of the malleus; *h*, body of the incus; *i*, stapes in the oval window; *k*, Fallopian canal; *l*, jugular fossa; *m*, glandular orifice in the skin of the cartilaginous canal.

FIG. 43.



The Auricle and the Cartilaginous Part of the External Auditory Canal (left side) (Politzer): *a*, cartilaginous meatus; *b*, inner pointed end which unites with osseous part of the auditory canal; *c*, fissures of Santorini.

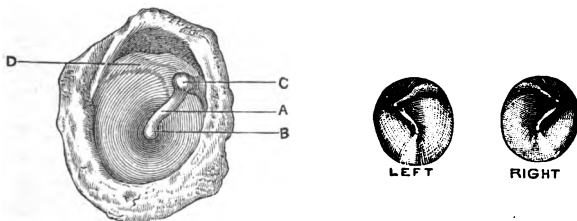
**Give the nerve-supply.**

Branches of auriculo-temporal branch of the inferior maxillary nerve.

**Describe the membrana tympani.**

The membrana tympani is composed of three layers—an external dermoid layer, middle or fibrous layer, and an internal or mucous membrane layer. (See Fig. 44.) In shape it is elliptical. The color, though it varies, is usually of a pearl gray. A ridge runs from above downward and back-

FIG. 44.



View of Outer Surface of Membrana Tympani (Gruber): A, malleus; manubrium; C, short process; B, the tip of the manubrium; D, posterior fold.

The Normal Membrana Tympani.

ward to the centre of the membrane. This ridge is formed by the handle of the hammer. In the centre of the membrane is seen a depressed point which is known as the umbo. Situated in the anterior and lower portion of the membrane is seen a triangular reflex of light. The apex touches the tip of the handle of the hammer, whilst the base lies on the periphery of the membrane. Two folds may be seen passing from the handle of the malleus, the one forward and the other backward. Above these folds is situated the membrana flaccida or membrane of Shrapnell.

**Describe the middle ear, or tympanum.**

The middle ear, or tympanum, is an irregular cavity situated within the petrous bone. The cavity is bounded by (1) a roof. (2) A floor, which corresponds to the jugular fossa and presents a small opening for the passage of Jacobson's nerve. (3) An outer wall, which is formed chiefly of the membrana tympani and the ring of bone into which the membrane is inserted. It has three openings—viz. the iter chordæ posterius, the Glaserian fissure, and the iter chordæ anterior. (4) An internal wall, which has the following parts: fenestra ovalis, fenestra rotunda, promontory, ridge of the aquæductus Fallopii, pyramid, in which is the opening for the stapedius. (5) A posterior wall, which presents for examination the mastoid cells. (6) An anterior wall, which presents the canal

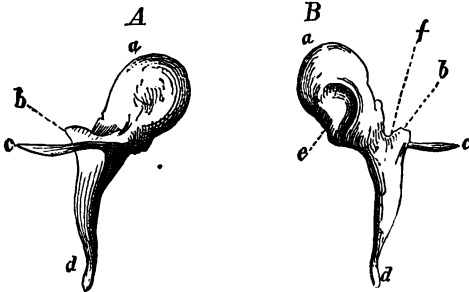


for the tensor tympani, orifice of the Eustachian tube, processus cochleariformis.

### Describe the Eustachian tube ?

The Eustachian tube connects the tympanum with the pharynx. It is from  $1\frac{1}{2}$  to 2 inches in length. It consists partly of bone, partly of cartilage, and partly of fibrous tissue.

FIG. 45.

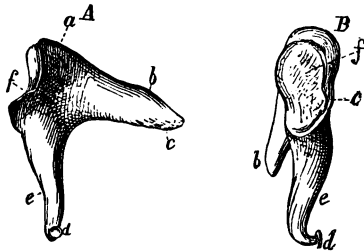


Right Malleus: *A*, from in front; *B*, from behind (magnified 4 diam., Henle): *a*, head; *b*, short process; *c*, long process; *d*, manubrium; *e*, articular surface; *f*, the neck.

### Name the ossicles of the tympanum.

The malleus or hammer (Fig. 45); the incus or anvil (Fig. 46); the stapes or stirrup (Fig. 47).

FIG. 46.

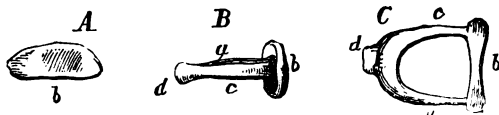


Right Incus (magnified 4 diam., Henle): *A*, inner surface; *B*, view in front; *Aa* and *Bc*, body; *b*, short process; *e*, long process; *d*, processus lenticularis; *f*, articular surface for the head of the malleus; *c*, surface which lies in contact with wall of tympanic cavity.

### Name the muscles of the tympanum.

Tensor tympani and stapedius.

FIG. 47.



Right Stapes (magnified 4 diam., Henle): *A*, from within; *B*, from in front; *C*, from beneath; *b*, foot-plate or base; *d*, capitulum; *c*, anterior; *a*, posterior shaft, or crus of stapes.

### Name the arteries of the tympanum.

Tympanic branch of the internal maxillary; stylo-mastoid branch of the posterior auricular; petrosal branch of the middle meningeal; a branch from the ascending pharyngeal; a branch from the internal carotid.

### What are the nerves?

The nerves which supply the muscles are a branch from the otic ganglion, which supplies the tensor tympani; a filament from the facial, which supplies the stapedius. The nerves which supply the lining membrane are derived from the tympanic plexus.

### Describe briefly the internal ear.

It is composed of a bony portion and a membranous portion (Fig. 48). The bony portion consists of three parts—the vestibule, semicircular canals, and cochlea. The membranous portion is a sac which contains fluid and endolymph, and has the same form as the vestibule and semicircular canals in which it is enclosed. It consists of two portions: *a*, vestibular portion, which consists of two sacs, the cuticle and the saccule; *b*, membranous semicircular canals.

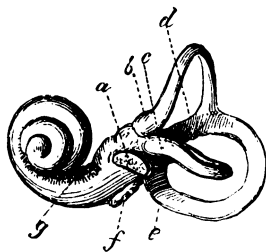
The arteries are the auditory from the basilar, the stylo-mastoid from the post-auricular, and occasionally branches from the occipital.

The auditory nerve is the special nerve of the sense of hearing, and divides at the bottom of the internal auditory meatus into two branches, the cochlear and vestibular.

(For a more detailed description of the anatomy of the ear the student is referred to the volume on *Anatomy* in this series.)

a membranous portion (Fig.

FIG. 48.



External View of a Cast of the Left Labyrinth (Henle): *f*, fenestra cochleæ, or round window; *a*, fenestra vestibuli, or oval window; *b*, ampulla of superior semicircular canal; *e*, ampulla of posterior semicircular canal; *d*, common shaft of union of these two canals; *c*, ampulla of the horizontal semicircular canal; *g*, tractus spiralis foraminosus.

## EXAMINATION OF THE PATIENT.

**In examining a patient suffering from ear trouble, what is the first step to be taken?**

Test his power of hearing. This may be done in three ways: 1st, by the watch; 2d, the human voice; 3d, the tuning-fork.

**How is the watch employed to test hearing?**

Place the patient in a chair with closed eyelids, and bring the watch, held at a distance, toward the ear under examination until the ticking is heard. The distance is recorded in inches by means of a fraction. The denominator of the fraction would be the number of inches heard by a normal ear, and the numerator the number heard by the patient under examination. For example, take 20 inches as the distance heard by the normal ear, and if the patient under examination heard only 8, we would record it as  $\frac{8}{20}$ .

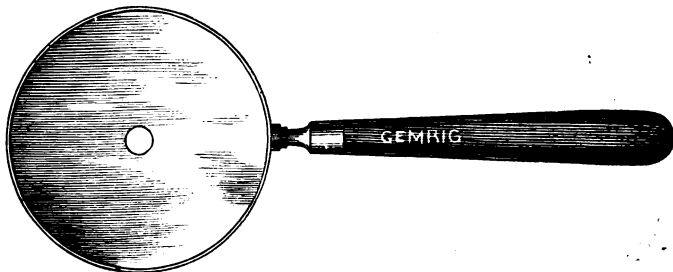
**How is the voice employed as a means of testing the hearing power?**

Have the patient close his eyes, and the ear not under observation firmly closed. Speak ordinary words, and note the distance they can be heard in feet, expressing as before in a fraction.

**For what purpose is the tuning-fork employed?**

To determine whether the deafness be due to a diseased condition of the sound-conducting apparatus or the nerve portion. If there is obstruction in the external auditory canal or disease of the middle ear, the tuning-fork placed in vibration on the frontal bone will be heard best in the defective ear. If the deafness is due to a diseased condition of the internal ear, the tuning-fork will be heard least distinctly in the defective ear.

FIG. 49.

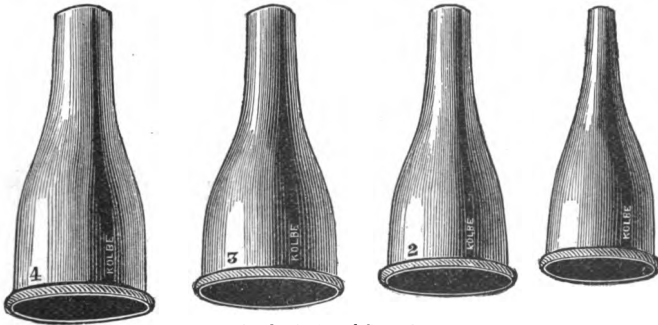


Ear Mirror.

**In making an examination of the external auditory canal and membrane, what instruments are requisite ?**

First, light, which may be either direct or reflected. Daylight or artificial light may be used. In using artificial light the argand gas-burner serves the purpose as well as any. To reflect the light a hand (Fig. 49) or head mirror is necessary. In using the head mirror one with a ball-and-socket joint is the best. Next, a speculum is required. Various specula have been recommended, but perhaps the best are those

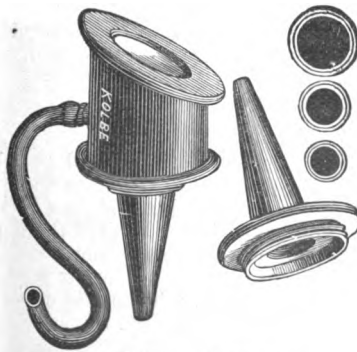
FIG. 50.



Gruber's Aural Specula.

used by Gruber and Childe (Fig. 50). For determining the mobility of the membrana tympani an otoscope has been devised by Siegle (Fig. 51).

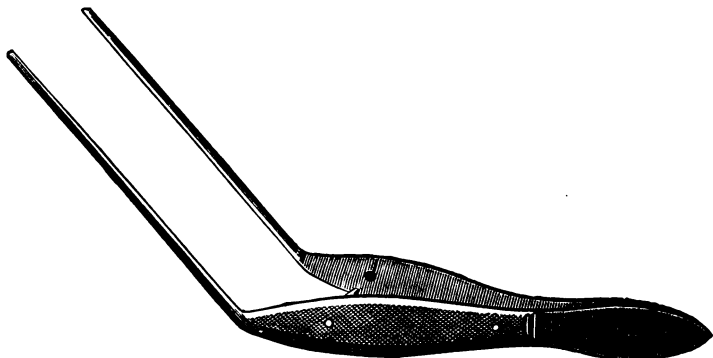
FIG. 51.



Siegle's Pneumatic Otoscope.

The other instruments requisite are a curette for removing scabs, etc.; a cotton-holder for drying, cleansing, and making applications; a forceps

FIG. 52.



Delicate Forceps for removing Foreign Bodies from the Ear.

for removing foreign bodies (Fig. 52); a syringe, which can also be used for the same purpose, as well as for cleansing the canal.

**What methods are employed to introduce air into the middle ear?**

There are three methods: I. Valsalva's method; II. Politzer's method; III. Catheterization of the Eustachian tube.

**Describe Valsalva's method.**

This consists in a forced expiration, the mouth and nasal passages being closed. The air is forced up by this means through the Eustachian tube into the middle ear. By means of an otoscope placed in the ear of the patient and the ear of the physician a slight noise is heard as the air passes against the drum-membrane.


**Describe Politzer's method.**

In using this method the patient is directed to take a mouthful of water and hold it until the physician tells him to swallow. The physician then places the nozzle of a Politzer air-bag in one of the nostrils and holds the nose firmly pressed over it. He then directs the patient to swallow, at the same time compressing the air-bag. In the act of swallowing the soft palate is elevated. The air passes up through the Eustachian tubes into the middle ear, having no other means of escape.

**Describe catheterization.**

There are various methods of catheterizing the Eustachian tube. The

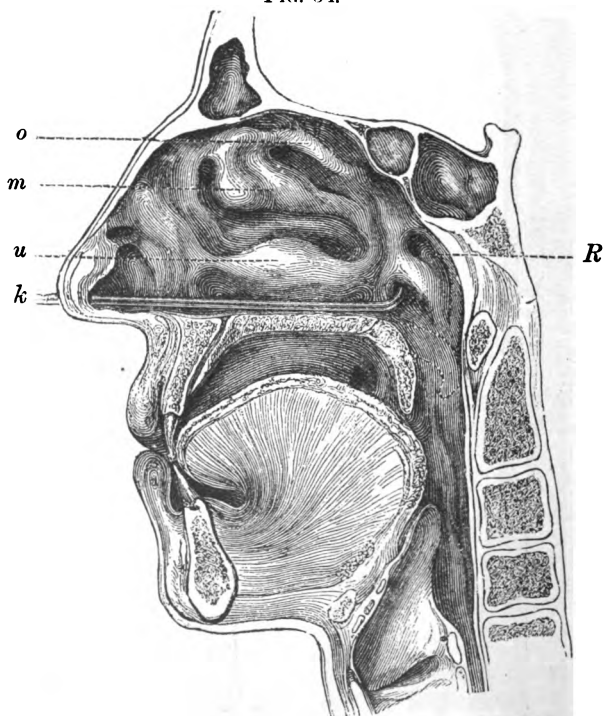
FIG. 53.



Eustachian Catheters of Hard Rubber (three sizes, A, B, and C): D, hard-rubber mount of the air-bag, made to fit accurately into the large end of all catheters on the principle of the ground joint.

one chiefly used is as follows: The physician takes a middle-sized catheter (Fig. 53) and introduces it into the nose with the curved portion downward. He then passes it along the floor of the nose as far back as the posterior pharyngeal wall. The curved portion is then turned inward at an angle of  $45^{\circ}$ , and brought forward till it is felt touching the septum. The curved portion is then made to describe an angle of  $90^{\circ}$ , when the

FIG. 54.



Inner View of the Right Half of the Head (antero-posterior section) (Gruber): *o*, superior turbinated bone; *m*, middle turbinated bone; *u*, inferior turbinated bone; *R*, Rosenmüller's fossa, bounded in front by the cartilaginous lip of the tube; in front of the latter is the pharyngeal opening of the Eustachian tube, in which the catheter *k* is placed.

mouth of the catheter, provided there be no obstruction present, will slip into the opening of the tube. A ring is usually attached to the

proximal end of the catheter, so that the physician can keep himself informed as to the direction the curved portion takes (Fig. 54).

## DISEASES AND AFFECTIONS OF THE AURICLE.

### What are the symptoms of eczema of the auricle ?

Redness and swelling of skin, followed by vesicular eruption, loss of epithelium, and serous oozing ; also itching and burning. These are the symptoms of acute eczema. In the chronic form there is thickening of skin, with formation of crusts and exudation of pus.

### Give the etiology.

It is apt to occur in infants during dentition, due to nerve-irritation. It may appear during adolescence, when skin diseases are most prevalent. We are apt to find the chronic form in old people, due, likely, to lack of nerve-force in branches supplied to the auricle.

### Give the treatment of eczema.

In the acute form some powder to relieve the itching and burning, or the oxide-of-zinc ointment may also be used. In the chronic form stimulating applications or a preparation of tar is advisable. Crusts are best removed by olive oil. Regulation of the diet is a necessary adjunct of treatment. Tonics are also of service, such as iron, cod-liver oil, etc.

## HÆMATOMA AURIS OR OTHÆMATOMA.

### What is hæmatoma auris ?

Hæmatoma auris is a swelling of the auricle in which there is an effusion of blood between the cartilage of the auricle and the perichondrium. It often occurs in the insane, and is traumatic or idiopathic in its origin. There are swelling, fluctuation, and some pain in the growth.

### What is the treatment ?

It consists in the alleviation of pain and the prevention of subsequent deformity. Some recommend the incision of the swelling. Gruber uses a trocar where the blood is fluid ; if it is coagulated he makes an incision and removes the clot. Tincture of iodine is recommended for the thickening. Others recommend the use of cold or warm applications.

### What are the new growths which have been observed affecting the auricle ?

I. Fibroid tumors. These are usually the result of piercing the lobule or are due to irritation from wearing an earring.

The *treatment* consists in their removal. They are liable to recur.

II. Epithelioma of the auricle has been observed.

Removal of the growth is the form of *treatment* to be adopted.



**What are other affections of the auricle ?**

Syphilitic gummata and syphilitic ulcerations.

*Treatment* is the same as syphilis occurring elsewhere.

Herpes zoster of the auricle is rare. Cleft lobule may occur as the result of wearing earrings.

Frost-bite, due to extreme cold.

*Treatment* consists in rubbing with snow and application of cold.

Congenital malformation has been observed, as also congenital fistula.

## DISEASES AND AFFECTIONS OF THE EX- TERNAL AUDITORY CANAL.

**Give symptoms and diagnosis of impacted cerumen.**

Deafness, buzzing in the ear, and vertigo.

The *diagnosis* is made by means of the speculum, which reveals a dark-colored mass lying in the canal. It may be hard or soft in consistency, according to the length of time it has been there.

**Give the etiology.**

An increased secretion may give rise to it, as also disease of the middle ear. Catarrh of the nose and pharynx is often found associated with it.

**What is the treatment ?**

If the mass be soft, syringing with warm water will usually suffice to remove it. If it be hard and does not come away, softening by filling the canal with olive oil or warm water, followed by syringing, should be resorted to. The forceps and curette can also be used, care being taken not to injure the tympanic membrane.

**What foreign bodies are found in the external auditory canal ?****Give the symptoms and treatment.**

I. Insects, such as the ordinary fly or grub. Their movements cause great pain, and they are best removed by means of the syringe.

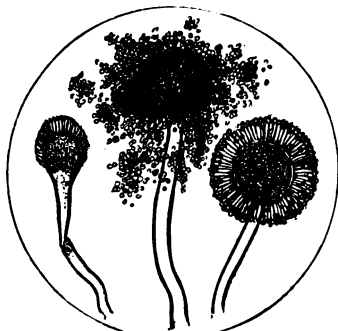
II. Vegetable parasites. The *aspergillus nigricans* and *aspergillus flavescens* are the parasites most usually found. They give rise to itching, pain, dizziness, and difficulty of hearing. On examination they appear as yellowish or black spots. The disease may be acute or chronic (Figs. 55, 56).

The *treatment* consists in first removing the parasite, which can be effected by the use of the syringe and warm water. Then fill the canal with alcohol and dry with cotton. By adopting this procedure every second or third day the growth is usually destroyed. Buck recommends nitrate of silver, 60-120 grs.- $\bar{3}$ j.

Other foreign bodies, such as beads, buttons, etc., are sometimes found in the external auditory canal. These may give rise to deafness, buzz-


ing, and dizziness. By means of the mirror and speculum they are easily recognized. They are best removed by syringe and warm water.

FIG. 55.



Aspergillus.

FIG. 56.



Spores.

Should this means fail, then the blunt hook or forceps may be used, but with caution.

### INFLAMMATIONS.

**How does diffuse inflammation of the external auditory canal show itself?**

As acute, chronic, primary, or consecutive. The latter form occurs usually in connection with middle-ear disease, and is secondary to that disease. As a primary disease it is due to traumatic or mechanical causes or to the presence of irritating substances.

**What are the symptoms?**

Pain, moderate or severe, intensified by pressure on the ear and by movements of the jaw; itching and tinnitus may also be present. On examination the canal presents a whitish appearance, due to the exfoliation of epithelium. After this is removed by means of the syringe and warm water, the canal appears reddened and narrow, and is painful when touched with a probe. In the chronic form there is but slight pain, some discharge, and a feeling of itchiness.

**What is the prognosis?**

The *prognosis*, if the disease remain uncomplicated, is favorable, the inflammation subsiding in the course of a few days.

**What is the treatment of diffuse inflammation of the auditory canal?**

Leeches may be applied in front of the tragus. Syringing with warm

water and scarification in the early stages are very beneficial. The gelatin preparations of morphine and opium used by Gruber give relief. Poultices may also be used. In the chronic form cleansing of the canal by means of warm water and insufflations of boric acid are recommended. Solutions of nitrate of silver are sometimes useful. The application of diachylon ointment on a plug of cotton is recommended by Buck and Pease.

**What are the causes of circumscribed inflammation of the external auditory meatus—viz. furuncles and boils?**

Discharges from the ears and irritation from foreign bodies. It usually attacks adults, and occurs in the spring and autumn. Anæmic and debilitated subjects are apt to be affected. It occurs also in women suffering from menstrual disorders.

**What are the symptoms?**

Pain, which may be severe or moderate, and which may extend up the side of the head, and may be intensified by pressure on the auricle and by movements of the jaw. Deafness may be complained of, as also buzzing. There may be one or several furuncles. They usually attack the cartilaginous portion of the canal. On examination swelling and redness may be noticed, which increase until rupture ensues. The patient may also have febrile disturbances.

**What is the treatment?**

Incisions through the swollen and painful portions. For this purpose the use of an anæsthetic or the instillation of a solution of cocaine is necessary. After the incision has been made syringing of the canal should be done. Poultices are beneficial, as also are warm instillations and anodynes. Painting the canal with carbolic acid in glycerin (1 : 30) has been recommended, or boric acid in alcohol. Attention to the general health, diet, etc. is necessary.

**What is diphtheritic otitis externa?**

An inflammation of the walls of the meatus, with the formation of a false membrane of a whitish color. It is of rare occurrence, and then usually as a complication of diphtheritis of the throat and middle ear. Primary diphtheritis has been observed during epidemics of diphtheria.

**What are the symptoms?**

In the primary form there are deafness, buzzing, and a sense of fullness in the ear. When it is secondary to diphtheria of the throat and middle ear, the pain is but slight or entirely absent. On examination there is seen a false membrane, which when removed leaves a bleeding and tender surface. The primary form usually ends in recovery, whilst the secondary may be followed by ulceration of the membrana tympani, destruction of the ossicles, and caries of the temporal bone.

**What is the treatment?**

The *treatment* consists in the use of antiseptics. The membrane should not be forcibly removed. Instillations of lime-water, followed by syringing with a solution of boric acid, help to loosen the membrane. The surface may be brushed over with a solution of carbolic acid in glycerin or boric acid in alcohol.

**Describe exostoses and hyperostoses of the external auditory canal.**

Exostoses and hyperostoses are usually situated at the outer portion of the osseous meatus or on the inner portion near the membrana tympani. They may be single or multiple, and have either a pedicle or broad base. They are congenital or acquired. They do not cause disturbances of hearing unless they block the lumen of the meatus. On examination they appear as whitish prominences, and on probing are found to be firm and hard.

**What is the treatment?**

Cleansing of the canal beyond the growth, especially if there be suppurative middle-ear disease. If they cause a stricture, dilatation may be resorted to by means of metal plugs. When the canal is narrow and deafness is present, as well as pain, removal of the growth often becomes necessary. This may be effected by the gouge or mallet or the dentist's drill, which is preferable. The galvano-cautery may also be used. Operative interference is rarely required.

**What other affections of the meatus occur sometimes?**

I. Syphilis may affect the meatus, showing itself in the forms of ulceration and condylomata.

The *treatment* consists in local and constitutional measures.

II. The meatus may be the seat of enchondroma, osteoma, sarcoma, and epithelioma.

III. The meatus may occasionally be found absent as a result of ulcerative inflammation of the walls, and a subsequent union of the walls by means of granulation-tissue. The atresia may be osseous or fibrous.

The *treatment* consists in the division or excision of the septum and dilatation by means of leaden pegs.

**DISEASES AND AFFECTIONS OF THE MIDDLE EAR OR TYMPANUM.****What are the causes of middle-ear disease?**

Changes of temperature, exposure to cold air, bathing where the ear becomes filled with cold water, and foreign bodies causing irritation. Disease of the middle ear may also occur as a sequel to other diseases, such as scarlet fever, measles, diphtheria, typhoid fever, etc. Nasal catarrh and adenoid vegetations are also frequent causes.


**What are the symptoms of acute catarrh of the middle ear ?**

Pain, which is intensified by the movements of the jaw or any muscular exertion or pressure over the tragus, noises in the ear, deafness, and dizziness. On examination slight redness of the membrane is noticeable, which increases as the inflammation spreads. If considerable exudation be present, there is bulging.

**In what does treatment consist ?**

Application of leeches to the tragus, filling the canal with warm water, and hot applications will relieve the pain and bulging. Paracentesis: the incision should be made downward between the handle of the hammer and the periphery of the membrane in the lower posterior quadrant (Fig. 57). If the pharynx or nose be affected, it should also receive

FIG. 57.



Paracentesis Knife.

treatment. To remove abnormal secretions inflation of the tympanic cavity should be resorted to by means of Politzer's method, which has been already described.

**What are the symptoms of subacute catarrh ?**

Pain, which may be present in some cases, but which when present is not so severe as in the acute inflammation. This non-severity of the pain is one of the distinguishing points between this form of the inflammation and the acute. The patient is hard of hearing, but this is merely temporary; the attacks occur frequently. On examination the transparency of the membrane is seen to be lost, and it is sometimes vascular. The light spot, which is triangular in shape with its apex at the extremity of the handle of the malleus, is found absent or smaller than is usual. Hearing is impaired, and with the tuning-fork bone-conduction is better than the aërial.

**What are the causes ?**

Bad nutrition, prolonged bathing, and diseases of the naso-pharyngeal membrane extending to the middle ear. It is most apt to occur in children.

**In what does the treatment consist?**

Look after the hygienic condition of the patient: tonics, regulation of diet; inflation of the tympanum by means of Politzer's method; removal of enlarged tonsils or adenoids, and treatment of the naso-pharyngeal mucous membrane by means of astringents; cleansing of the nose by Dobell's solution when necessary.

**Describe hemorrhagic inflammation of the middle ear?**

It is a rare disease, and is characterized by severe pain, which lasts but a few hours and is followed by hemorrhage through the membrana tympani. It is a severe form of acute inflammation. Hemorrhage into the membrana tympani has been observed after the use of the nasal douche; it is also due to traumatism.

**What is the treatment?**

Cleanse the auditory canal from blood if perforation has already occurred. If it has not occurred, leeches should be applied. These sometimes abort the disease. Pus does not usually form, and the blood is gradually removed.

**Into how many forms is chronic non-suppurative inflammation of the middle ear divided?**

It may be divided into two forms: (1) the catarrhal and (2) the proliferous.

**What are the pathological changes which may occur?**

There may be collections of mucus or serum in the tympanic cavity, with hypertrophy of the mucous membrane and filling of the cavity with lymph. In the proliferous form, or where both are combined, there may be formation of connective tissue, filling up the tympanum. Ankyloses of the ossicles and adhesive bands in the mastoid cells may be present. The membrana tympani is sometimes found adherent to the walls of the labyrinth, and atrophy and fatty degeneration of the tensor tympani may exist.

**What are the causes?**

Various diseases may give rise to it, such as syphilis, bronchitis, measles, scarlet fever, etc., and the inflammations of the naso-pharyngeal mucous membrane. Repeated attacks of acute inflammation may also occasion it.

**What are the symptoms?**

The patient will complain of a feeling of stuffiness in the ear, and of noises in the ear, which may be of a varied character, such as the roaring of the sea, the chirping of birds, or musical sounds. He also may complain of his throat. The hearing is impaired, the patient hearing better in a noise. On testing with the tuning-fork bone-conduction is

found better than aërial. On examination with the speculum opacities of the membrane may be seen, and the light spot will be found altered or absent. The membrane will be found rigid and retracted. To test the mobility of the membrane we make use of Siegle's otoscope, with a syringe attachment for exhausting the air. The Eustachian tube is often affected, it being impossible sometimes to drive air through the tube. The naso-pharynx is usually also affected. In the proliferous form of inflammation there are no changes in the naso-pharyngeal region; there is no catarrh of the tympanum; the drumhead is more sunken, and the tinnitus aurium more pronounced. In some cases the hearing is better on clear, dry days, and worse on wet ones.

### **In what does the treatment consist?**

The *treatment* is not altogether satisfactory. Constitutional treatment is requisite, such as the administration of tonics. Regulation of the diet and hygienic treatment are of importance. Care of the skin by means of daily bathing and rubbing, as also proper clothing. In catarrhal cases the treatment of the naso-pharyngeal spaces is requisite. Excessive secretions should be removed by means of Dobell's solution or other cleansing solutions. Hypertrophies should be removed or cauterized, as also enlarged tonsils and adenoid vegetations.

The treatment of the Eustachian tube and tympanum by inflation is of great importance. For this purpose we make use of the Eustachian catheter and Politzer's method. This inflation should be carried out daily if possible. Mild astringent solutions in catarrhal cases, forced into the tube by means of the air-bag, are sometimes found serviceable. For dilating strictures in the Eustachian tube bougies are recommended by some authors. Exhaustion of the air in the auditory canal by means of a plug of cotton is useful in lessening the retraction of the drum. Tinnitus aurium is often relieved by this method.

### **What are the pathological changes which occur in acute purulent inflammation of the middle ear?**

There is hyperæmia of the mucous membrane, cellular and serous infiltration of the connective tissue, and exudation of pus into the tympanic cavity. The mucous membrane appears red and swollen. Perforation of the drum occurs in the greater number of cases. The mucous membrane of the tympanum, Eustachian tube, and mastoid cells is usually affected by these changes.

### **What are the causes of this disease?**

It may occur as the result of cold, as the result of traumatism, or from an extension of inflammation from the naso-pharynx. It may occur in the course of various diseases, such as measles, small-pox, scarlet fever, diphtheria, etc.

### **What are the symptoms?**

Pain which may shoot over side of head: it is usually most severe at

night, and is lancinating in character; noises in the ear, such as hissing, roaring, etc.; a feeling of fullness in the ear; fever may be present or absent, the thermometer often showing a temperature of 100°-103° F. Deafness is present, and increases as the tympanic cavity becomes filled with pus. The pressure from secretion may press the secondary membranes inward, thereby paralyzing the auditory nerve.

To test whether the conducting power or the nerve is affected, the tuning-fork will aid in the diagnosis. When placed on the forehead it will best be heard in the affected ear if the conducting apparatus be alone at fault, and in the unaffected ear if the nerve portion be affected. On examination with the mirror and speculum the membrane appears at first slightly injected. This, however, increases to a general redness, and the membrane loses its transparency. The position of the membrane may be altered. It may be flat throughout its whole extent, or, if there be considerable exudation, it will bulge forward in certain portions. Its mobility is destroyed. Very often on auscultation, if the Eustachian tube be open, we can hear moist bubbling râles.

Perforation takes place in the majority of cases, and is followed by almost instant relief, the pain ceasing and the sense of fullness disappearing. The secretion then pours out, and is very profuse at first. It gradually ceases and the perforation heals.

#### **What is the duration of the disease?**

It is variable: four weeks where the perforation is small; where the perforation is large it may last three or four months.

#### **By what causes may the disease be prolonged?**

By a low state of the general system from other diseases. Inflammation of the mastoid may be present and keep up the tympanic inflammation. Otitis externa may develop secondarily and keep up tympanic congestion, also interfere with drainage, and thus prolong the disease. Granulations sometimes develop in the course of this disease, and serve to keep up the trouble; hence they should be early recognized and properly treated. Ulceration may occur, often destroying a portion or even the whole of the membrane. Meningitis is apt to occur, though it is a rare complication.

#### **For what diseases are we apt to mistake it?**

In the earlier stages for catarrhal inflammation. The most common form of error is, however, in considering the disease in the early period as a neuralgia. The congestion, swelling, etc. point, however, to inflammation of the tympanum. Perforation is present, which can be detected by the eye or by inflation.

#### **What is the prognosis?**

In healthy persons usually favorable with proper treatment. Where there are present general diseases, the prognosis is not so favorable. If the perforations occur early the prognosis, as a rule, is good.



**What is the treatment?**

In the early stages local applications for the relief of pain. Dry heat, applied by having the patient rest his head on a bag of hot salt or bran, is often soothing. Politzer recommends a piece of linen folded several times, dipped in tepid water, applied over the ear and covered first with oiled silk and then with a dry silk handkerchief. This is to be changed several times a day. The patient should be kept in the house or in bed if there be febrile disturbance present. When there is bulging of the membrane and perforation has not taken place, paracentesis is indicated. This is usually seen in the posterior lower quadrant. The tympanic cavity should be cleaned of the secretion by inflation, either by Politzer's method or by catheterization. The meatus should then be syringed with warm water and dried with absorbent cotton. This should be followed by the insufflation of boric acid, which acts as an antiseptic. If the discharge continues, we must then resort to astringents, such as zinc sulphate, 1 : 300, etc. A few drops of an astringent solution is poured into the meatus, allowing the patient to retain it for about ten minutes. This can be done daily, or even twice daily if necessary. If granulations develop, these should be touched with nitrate of silver by fusing a little on a probe and then making the application.

Should otitis externa arise during the course of the disease, it should also receive treatment by antiseptics and fomentations. Should the walls of the meatus be swollen to such a degree as to prevent the free discharge of pus, a tube should be passed beyond the swelling and the ear then syringed.

The mastoid tenderness requires no direct treatment. If it becomes decided, however, active measures must be resorted to.

**What are the causes of chronic purulent inflammation of the tympanum?**

It may develop from an acute inflammation or primarily. Rarely it is developed secondarily to an inflammation of the meatus. Scarlet fever and tuberculosis are the most common causes, then typhoid, variola, measles, etc.

**Give the pathology of this disease.**

There are two distinct pathological conditions in this disease, the one a swelling and hypertrophy, the other a thinning of the mucous membrane and submucous tissues. The thickening consists in an infiltration: this is followed by the development of connective tissue, which may take place either in the submucous tissue or over the free surface of the mucous membrane. In the condition accompanied by thinning the normally existing tissue disappears and is not reproduced. The newly-developed inflammatory products do not become organized, but are thrown off in the discharge.

**What are the symptoms of chronic purulent inflammation ?**

There is discharge, which may be purulent, muco-purulent, and sometimes tinged with blood. It may be profuse or slight, and sometimes dries up in the meatus. Deafness is present, which may be extreme or moderate, depending on various conditions, such as the hypertrophy of the membrane, the loss of tissue, and the amount and position of the secretion. Noises in the head are not common symptoms, but patients may complain of weight in the head, with mental depression or an obstinate headache. On inspection the appearances vary much. When there has been profuse suppuration the epidermis often appears white and ulcerated. There may be stenosis, or we may find granulations on the walls of the canal. Exostoses are occasionally found in the bony meatus. Perforations are found in all parts of the drum-membrane. They are very frequently found in the anterior lower quadrant, sometimes a number of perforations, and they may vary in size from a pin's point to complete destruction of the membrane. In shape they are oval and elliptical. In severe forms of the disease the ossicles may be found absent, due to ulceration of their ligamentous attachments. The cavity of the tympanum is then exposed to view, and we can make out the promontory, the openings of the fenestra rotunda and fenestra ovalis. Provided we have carefully cleansed the auditory canal, perforations are, as a rule, easily recognized. Valsalva's or Politzer's method will give the perforation whistle, which is a sure indication that a perforation is present. The appearances of the mucous membrane vary. It may be œdematous, dark red, pink, smooth, or granular.

**Is one apt to make a mistake in diagnosing a perforation ?**

Yes. An inexperienced eye may often mistake a cicatrix for a perforation, especially where the cicatricial tissue is so thin as to escape detection. Auscultation will give us the whistling character of a perforation.

**In testing the hearing what degree of deafness is found ?**

Deafness accompanies every case, but varies. If the perforation is small, if there is but little swelling or thickening to diminish the mobility of the membrane and ossicles, if the stapes is freely movable in its membrane, and if the nerve-structures are intact, the loss of functional power is but slight. If the conducting mechanism is covered with swollen tissue, deafness is present to a marked degree. Where the drum-membrane is destroyed the amount of deafness depends upon the condition of the stapes, provided the nervous parts are intact. A fair degree of hearing is present if the stapes remains in good condition. Total deafness is found only where the labyrinthine structures are affected. The tuning-fork, placed on the forehead, is usually heard loudest in the affected ear.

**What is the course of chronic purulent inflammation of the middle ear ?**

It depends chiefly on the local changes in the ear, on the condition of the naso-pharynx, and on the general health. For description, cases can be divided into three classes :

The *first class* is where there is merely simple suppuration present. In these cases the suppuration may cease of itself ; in tuberculous patients the discharge may continue indefinitely or even last through the whole course of life.

The *second class* of cases is where there is granular suppuration of the mucous membrane. This runs nearly the same course as the preceding, except that it is more tedious.

The *third class* is where there are complications present. These may be retained secretions, polypi, caries and necrosis, mastoid disease, and disease of the labyrinth. These must first be got rid of before any cure can result. By appropriate treatment one should endeavor to reduce the case to one of simple inflammation. Having done this, the further course of the disease depends upon the nature of the perforation. Where conditions are favorable a cicatrix forms, and hence a cure.

**What is the prognosis of chronic purulent inflammation ?**

This depends upon its nature, whether it be simple or complicated. If simple and the naso-pharynx is properly attended to, as well as the general health, the inflammation can generally be reduced and the discharge checked. If the perforation closes, a cure can generally be said to be effected. Where there is granular suppuration the *prognosis* is not so good. In tubercular cases it is usually very difficult to check.

In complicated cases the prognosis depends to a great extent upon the nature of the complications and our ability to get rid of them. The prognosis as regards the restoration of hearing-power depends upon the condition in which the parts are left after the inflammation has subsided. The prognosis as regards life is favorable, so long as none of the fatal complications make their appearance. These are meningitis, phlebitis, thrombosis of the sinuses, and pyæmia.

**What is the treatment ?**

The first step consists in cleaning of the cavity. This is effected by means of the syringe or douche ; the fluid should be warm. Antiseptic solutions, such as carbolic acid, boric acid, etc., are useful. Where the drum-membrane is wholly destroyed, syringing is often ineffectual in removing completely the masses of secretion. Inflation by means of Valsalva's and Politzer's method or cauterization is of service in helping to remove the secretions from the deeper portions of the meatus. Suction by means of Siegle's speculum has been recommended. This instrument sometimes produces congestion. There are some cases in which it is found necessary to pass the point of a syringe into the

tympanum to remove the secretion. This can be done by attaching a small canula to a syringe and passing the end within the perforation. Politzer has found syringing through the Eustachian tube sometimes useful. The largest-sized catheter should be used, and a syringe attached to its end. Where there is swelling of the Eustachian tube the small elastic catheter can be passed through the Eustachian catheter into the tympanum, and the tympanum thus syringed. This method is not wholly devoid of danger, and great caution should be exercised in its use. After syringing the ear it should be thoroughly dried with absorbent cotton. Local medication should then be adopted in the form of powder, liquids, or medicated cotton for the purpose of checking the secretion. Boric acid in simple cases, applied by means of an insufflator, is often found useful. Loewenberg recommends the use of alcohol. It diminishes the congestion, reduces the oedema, and tends to reduce the thickened membrane. It is applied by instillation with equal parts of water, the patient being allowed to retain it from five to fifteen minutes. Schwartze recommends the cauterization of the diseased membrane by nitrate of silver. This can be applied in solution by instillation or by painting. Dry treatment, advocated by some, consists in cleansing without the use of fluids, and then applying a plug of medicated cotton.

#### **How would we treat granular suppuration?**

By the use of caustics or alcohol. Alcohol has the power of shriveling up the granulations. The nitrate of silver, applied by means of a probe, is very effective. The use of the galvano-cautery requires great caution. Where the granulations are isolated a wire snare or a sharp curette can be used.

#### **Where the perforation is so small as to prevent the secretion from making its escape, or where granulations prevent its escape, what it is sometimes necessary to do?**

Enlarge the perforation or establish a second perforation. This is done by means of the paracentesis needle, as previously described.

#### **What other adjuncts of treatment are necessary?**

If the Eustachian tube be involved, it should receive appropriate treatment. Inflammations of the naso-pharynx should receive attention. The general health should be looked after. Anæmia, by iron, tonics, etc. Where syphilis is present, mercury and iodide of potassium should be administered. Attention to the diet, clothing, etc. should also be given.

#### **How is the deafness treated?**

By the use of remedies just described, by inflation, etc. In a certain number of cases where the perforation does not heal the use of an artificial drum-membrane has been found serviceable. Many artificial mem-

branes have been devised, but a piece of absorbent cotton, made into the proper shape and size, will often answer the purpose. Its use is indicated where there exists extreme deafness of both ears. When dizziness and irritation result, the artificial membrane should be discarded.

Operations for the relief of deafness after suppuration has ceased have been devised by some authors. Their object is the separation of adhesions in the conducting mechanism. Their value and indications are as yet not fully established.

### **How are caries and necrosis produced?**

By the extension of the inflammation of the mucous membrane of the tympanum to the deeper layers, and thence to the bone itself. Caries and necrosis may attack any portion of the temporal bone, the most frequent points of attack being the mastoid and the meatus.

### **What are the symptoms of caries and necrosis?**

When the caries is circumscribed there are scarcely any *symptoms* present. If extensive, we have pain in the ear. If caries attacks the mastoid, antrum, or the anterior portion of the mastoid cells, there are swelling and infiltration of the skin in the upper and posterior portions of the meatus. At first it is firm and hard, but if pus forms it becomes soft and fluctuating. Caries of the tympanic roof presents no symptoms by which it can be recognized except by exploration with the probe. Paralysis of the facial nerve is often a symptom of caries of the tympanum.

### **What is the course of caries?**

It may progress slowly or a sequestrum may form rapidly. Portions of the bone may come away in the discharge after the diseased bone has been removed; granulations may form on the walls of the cavity. These become changed into connective tissue, which ossifies, and then we have a hyperostosis in place of the normal bone.

### **How is the diagnosis of caries and necrosis made?**

It can only be made with surety by means of the probe. Where this fails a combination of symptoms may lead us to suspect caries. The probe should be used with caution. Pain recurring at intervals or persistent, with an offensive discharge, aids in making a diagnosis.

### **What is the prognosis?**

The *prognosis* depends on the situation and the amount of surface involved. In healthy persons, where there is free exit for the discharge and sequestrum, prognosis is favorable. In tuberculous patients, where disease is not apt to limit itself, the prognosis must be guarded. In caries of the petrous bone, when extensive, the prognosis is doubtful, and when attacking the upper wall of the tympanum or antrum there

is danger of disease of the membranes of the brain and sinuses, which of course makes the prognosis serious.

### **What is the treatment?**

First, the removal of the diseased portions of bone. If the disease be where it can be reached, we can hasten the progress by removal of these diseased portions. This is done by means of a sharp curette, with which the bone is scraped. When the caries affects the promontory of the tympanum, only the most superficial scraping should be used; when on the edges of the promontory or within the niches of the fenestræ of the labyrinth, it should not be performed at all. The parts should be kept cleansed by carbolic syringing. After the softened bone has been scraped away insufflations of iodoform should be used. When there are exfoliations of bone, they should be removed, as also loose sequestra.

The general treatment should also receive consideration. Pain should be relieved by opiates. Tonics when necessary. Iron is indicated in anæmia, and iodide of potassium in tuberculous cases. Regulation of diet. Bathing and clothing should receive attention.

### **Describe polypi.**

They are connective-tissue new growths covered with epithelium. Politzer recognizes two varieties: (a) the round-celled polypi, and (b) the fibromata.

### **Where do they usually have their origin?**

The majority originate from the tympanic cavity. They may also originate from the drum-membrane, from the tissue covering the ossicles, or from the walls of the meatus, usually the posterior superior wall of the osseous meatus.

### **What are the symptoms of polypi?**

When large enough to press upon important parts of the ear or to interfere with the discharge of pus, there may be present pain, dizziness, weight and fulness in the head, and symptoms pointing to the cerebrum. On examination the growth is seen, and the use of the probe makes the diagnosis certain.

### **Give the diagnosis of polypi.**


*Diagnosis* is not always easy. Other tumors of the ear are rare. Enchondromata, warts, and encysted tumors must not be mistaken for polypi. Epithelioma begins like an eczema, followed by ulceration and pain. Sarcoma, in the early stages, can be mistaken for polypi. Microscopical examination will serve to clear up the diagnosis in both suspected epithelioma and sarcoma.

### **In what does the treatment of polypi consist?**

The *treatment* consists in their removal. This can be usually accom-

plished by Wilde's snare (Fig. 58). The loop of the snare is passed in and around the pedicle of the polypus, and the loop withdrawn, which

FIG. 58.



Wilde's Aural Polypus Snare.

cuts off the polypus. The ear is then syringed out, and the base of the polypus cauterized with nitrate of silver. If the polypus be of large size, a second introduction of the snare may be necessary. If bleeding be excessive, it can be usually checked by means of a tampon. The application of cocaine makes the operation comparatively painless.

Caustics are sometimes used for the destruction of polypi. It is a slower and more painful method. The use of alcohol by shrivelling up the polypus has also been found successful.

#### **Give the pathology of mastoid inflammation.**

The inflammation arises from an extension of the inflammation of the tympanum along the mucous membrane. When the tympanic inflammation subsides, this, as a rule, ceases also. Sometimes it extends through the foramina of the bone, thus setting up an external peritonsillitis. Through carious ulceration a fistula forms.

Politzer states that in every post-mortem examination he made of suppuration of the middle ear he found the mastoid likewise affected. When the inflammation continued until death the mucous membrane showed signs of inflammation, and the cells were filled with purulent or muco-purulent fluid or granulation tissue. When the suppuration had ceased before death the mucous membrane of the mastoid was sometimes thickened, sometimes filled with connective-tissue growths or layers resembling epidermis. In some cases the cells were obliterated by sclerosis of the bone; in others caries or necrosis was present. Hyperostosis of the mastoid may advance so far that the cancellated tissue is entirely obliterated, the mastoid being thus changed into a solid piece of bone. A mastoid inflammation may then exhibit all the phases of inflammation of bone—softening, caries, necrosis, and hyperostosis.

#### **In what directions may the mastoid inflammation extend itself?**

It may extend outward through the external cortex. Forward we may have a perforation into the meatus, with inflammation following.

Inward the lateral sinus may become involved, with phlebitis, thrombosis, emboli, and their consequences. Upward the inflammation may extend, invading the middle fossa of the skull. An abscess may be produced beneath the dura mater, or abscess of the brain and meningitis may result. The inflammation may extend downward through a perforation in the floor of the mastoid which opens into the digastric groove. Thus we can have suppuration in the deeper tissues of the neck.

#### **What are the symptoms of mastoid inflammation ?**

Pain in the mastoid region which shoots along the vertex, temple, and occiput. On deep pressure tenderness is found to be present. If the inflammation be acute, there is a certain amount of fever present. When the disease extends outward the tissues covering the bone become at first slightly swollen. Redness and heat then follow with increased œdema. As pus forms it can sometimes be detected by deep palpation. Swelling of the upper and posterior walls of the meatus is present in mastoid inflammation. Hyperostosis, when present in a slight degree, is difficult to recognize ; when extensive, it narrows the meatus by hypertrophy of the osseous walls.

#### **When the inflammation extends forward what symptoms are present ?**

There is inflammation of the lining of the posterior wall of the meatus, with the formation of an abscess, which is followed after rupture by the formation of granulations. We then, as a rule, have carious perforation, which can be diagnosed by means of a probe.

#### **When the inflammation extends downward what symptoms are present ?**

Swelling and tenderness below the point of the mastoid, accompanied with pain. The swelling is dense and hard and has defined edges. It may extend down the sterno-cleido-mastoid muscle forward to the retro-maxillary fossa, and along the large vessels of the neck. It may also extend backward and downward over the whole side of the neck to beneath the clavicle, or it may extend upward to the superior curved line of the occiput. Pain, as a rule, accompanies the swelling, and may also affect the occiput as the swelling extends backward.

#### **What is the differential diagnosis of secondary inflammation of the mastoid ?**

It is likely to be mistaken for primary inflammation of the mastoid. It is doubtful, however, if primary inflammation of the mastoid ever occurs.

Inflammation of the external meatus, when it is accompanied with swelling over the mastoid, is apt to be mistaken for a genuine inflammation of the mastoid.



**What is the prognosis?**

The *prognosis* must be guarded, because of the various complications which may arise. It depends also on the general condition of the patient and the intensity of the inflammation.

**What does the treatment consist in?**

Attention should first be given to the tympanic cavity. In acute cases, where bulging of the membrane is present, paracentesis should be performed. The cavity should be kept cleansed in both the acute and chronic forms of tympanic suppuration. Where the pain over the mastoid persists, the use of Leiter's coils has been recommended. The use of cold water by means of these has been found serviceable. Where the above means are unavailing, a resort to Wilde's incision should be made. This consists in making an incision through the periosteum down to the bone. The bleeding which results often gives relief, though no pus be evacuated. The periosteum should be raised and softening of the bone sought for. When found, it should be broken through, and the cells evacuated and washed out with an antiseptic solution. Some cases present no bone softening and remain unrelieved by these methods of treatment, and hence an artificial opening of the mastoid becomes necessary.

**Describe the operation of opening the mastoid.**

Two methods are in vogue: one consists in boring with drills, and the other in chiselling. The operation by means of the chisel is to be preferred. The landmarks in the operation are the linea temporalis and the posterior wall of the meatus. An incision should be made down to the bone close to the insertion of the auricle. The incision should begin about 1 cm. above the auricle, and extend nearly down to the tip of the mastoid. A second incision should be made backward and upward, about 2 cm. in length, opposite the middle of the meatus. The periosteum should then be turned back and the whole mastoid exposed. An examination should then be made for any softened portions of bone, and all such carefully removed. If there is no softened portion, then an artificial opening must be made. This should be made about 2 to 3 mm. below the line of the superior wall of the meatus, and about 5 mm. backward from the edge of the anterior surface of the mastoid. Sometimes hyperostosis is found to exist in a marked degree. The opening should not go deeper than 15 mm. When the interior of the mastoid has been exposed the cells should be broken down and all carious masses should be removed. Free communication with the tympanum should be established. After the operation is completed the wound should be syringed with an antiseptic solution, and if there be communication with the tympanic cavity, this is proven by the fluid appearing at the external meatus. A drainage-tube should then be inserted, and cleansing of the cavity daily should be performed. The opening should not be allowed to close until all suppuration has ceased.

The duration of the treatment will vary according to the conditions present. The chief danger attending this operation is wounding the lateral sinus. To avoid this a direction parallel with the wall of the ear-passage should be maintained. Sometimes there is a malformation present which renders this danger unavoidable.

**What are the diseases occurring within the cranium as a result of purulent inflammation of the tympanum?**

Meningitis affecting the convexity and base of the brain; phlebitis and thrombosis of the sinuses; abscesses of the cerebrum and cerebellum.

**What are the symptoms of otitic meningitis?**

The chief *symptom* of meningitis is headache, which may be at first intermittent, but soon becomes continuous and increases in severity. Accompanying this there are restlessness, wakefulness, and occasionally vomiting, followed by dulness of the intellect. In children coma may be present. It is often very difficult to make a diagnosis of an otitic meningitis in the early stages.

**What is the treatment of otitic meningitis?**

The *treatment* is the same as in meningitis from any other cause. The local treatment of the ear is the chief indication, however, in this form of meningitis. This consists in the removal of obstruction to the evacuation of pus, with thorough cleansing. Removal of granulations, polypi, sequestra, etc. is necessary. Inflation when indicated should be carried out.

**What are the symptoms of phlebitis and thrombosis?**

Chills, followed by high temperature. The chills increase in frequency, and soon the fever becomes continuous. Headache and dizziness are also present. The phlebitis of the sinus soon produces a thrombus, and as a result the circulation is checked. This is followed by œdema and suppuration in the supraorbital, orbital, or nasal tissues. The thrombus may extend downward into the internal jugular vein, so that it is felt as a firm, hard cord. The thrombus may likewise pass into the mastoid vein, thereby producing œdema and inflammation of the superficial structures of the neck on the posterior side. The thrombus also, in rare cases, extends backward to the torcular Herophili. The thrombus may undergo suppuration and rupture, setting up a meningitis.

The disease may extend over a period of weeks, and even months, death, as a rule, resulting from exhaustion. In very rare instances recovery may take place.

**In what does the treatment consist?**

Treat the symptoms as they appear, giving attention, especially in the early stages, to the local treatment of the ear.

**What are the symptoms of abscess of the brain?**

They are, as a rule, in the beginning obscure, and remain very often latent for a considerable period of time. Headache is present, which is slight at first, but increases. This is followed by fever, dizziness, vomiting, sometimes chills, and paralysis. After the earlier symptoms the disease may be acute or chronic. In the acute form the disease runs its course in from one to five weeks. The chronic form is marked by latency of the symptoms. This duration of latency varies from weeks to months, and when once broken the disease runs its course.

**What is the differential diagnosis?**

In meningitis there are high fever and pulse, headache continuous and severe, delirium, contractions of the pupils, vomiting, and convulsions. In abscess of the brain the *diagnosis* is rendered uncertain by the latency of the symptoms, and the symptoms often resemble those of meningitis. When the abscess is in certain positions affections of the sensory or motor nerves show themselves. Where we have symptoms of a high fever and pulse associated with purulent disease of the ear, followed by a falling of the pulse below normal, and headache which is circumscribed, a suspicion of abscess of the brain may be entertained.

**What is hemorrhage of the ear likely to be due to?**

It is usually the result of caries of the bone in the neighborhood of some of the large vessels. The most frequent source is from the carotid artery.

The *diagnosis* of hemorrhage from the ear is not always certain. If the blood is arterial and checked by compression of the carotid, it likely comes from that vessel. If the bleeding is slight, it may come from some of the tympanic arteries. When venous it may be from the sinuses or jugular vein.

**What is the treatment?**

If the bleeding is from the carotid, ligation of that vessel is necessary. If from the smaller vessels, the application of cold and styptics, with tamponing of the meatus; the same when the bleeding is from the jugular or venous sinuses.

**DISEASES AND AFFECTIONS OF THE INTERNAL EAR OR LABYRINTH.****Describe briefly the labyrinthine affections.**

Very little is known of the pathology of affections involving the labyrinth. Cases of total deafness are observed following cerebro-spinal meningitis. In these cases the lesions are supposed to exist in the labyrinth. Scarlet fever, typhoid fever, measles, may also be followed by complete deafness, also due to lesions of the labyrinth.

Acute primary inflammation of the labyrinth has been described. It is rare.

In Ménière's disease there is sudden loss of hearing, with vertigo, ringing in the ears, and an inability to maintain one's balance. The deafness may involve one or both ears, and may be complete or incomplete.

Anomalies of hearing have also been described. These are—

(a) **Diplacosis monauricularis.**—In this condition there is double hearing in one and the same ear.

(b) **Diplacosis binauricularis.**—Double hearing in both ears.

In those cases of deafness following epidemic cerebro-spinal meningitis, scarlet fever, etc., where no disease of the external auditory canal or middle ear exists, the *diagnosis* may be made of a lesion of the labyrinth. When the deafness exists in only one ear, the use of the tuning-fork aids in a diagnosis.

*Prognosis* is bad in all these cases, especially so in Ménière's disease.

The *treatment* recommended is iodide of potassium, iodide of sodium, strychnine, and the use of electricity. That the disease can be of syphilitic origin should not be ignored; hence an antisiphilitic treatment should not be neglected.



# DISEASES OF THE THROAT.

## THE PHARYNX.

### ANATOMY OF THE PHARYNX, PALATE, AND TONSILS.

**Briefly give the anatomy of the pharynx.**

The pharynx is a space which extends from the base of the occipital bone above to the anterior surface of the fifth cervical vertebra below. It communicates anteriorly with the nasal and oral cavities, laterally with the middle ear, and inferiorly with the œsophagus and larynx. It has a fibrous investment, the pharyngeal aponeurosis, a mucous lining, as well as a muscular coat. The mucous membrane is covered with columnar ciliated epithelium as low down as the level of the floor of the nares; the rest of it is covered with squamous epithelium.

The mucous membrane of the upper portion, or naso-pharyngeal space, is of importance, as on the upper posterior and lateral walls it is rich in cellular structures and abounds in follicles. This follicular mass bears the name of adenoid tissue, pharyngeal tonsil, or Luschka's tonsil.

**What is the chief function of the pharynx?**

It consists in carrying the food after mastication into the œsophagus. The muscles which effect this are the stylo-pharyngei and the pharyngeal constrictors. Besides this chief function it has duties in relation to nasal respiration, tone-production, and hearing.

**Describe the palate.**

The palate forms the roof of the mouth, and consists of two portions—the hard palate in front and the soft palate behind. The hard palate is bounded in front and at the sides by the alveolar processes; behind it is continuous with the soft palate. It is covered with mucous membrane, which is closely united with the periosteum. In the middle line is seen a ridge which terminates anteriorly in a small papilla. This papilla corresponds with the inferior opening of the anterior palatine fossa. The mucous membrane is corrugated, covered with squamous epithelium, and contains numerous glands which lie between it and the surface of the bone.

**Describe the soft palate.**

It is attached to the posterior border of the hard palate. It is made up of muscular fibres, aponeurosis, vessels, nerves, adenoid tissue, mucous glands, and is covered with mucous membrane. Hanging from its middle is a small process, the uvula, and running down from the uvula on each side are two folds of mucous membrane, called the pillars, anterior and posterior,

**What are the muscles of the palate ?**

They are the levator palati, tensor palati, palato-glossus, palato-pharyngeus, and zygous uvulæ.

**Describe the tonsils.**

The tonsils are two almond-shaped organs situated between the anterior and posterior pillars on each side of the fauces. The surfaces of the tonsils present a number of orifices leading into small recesses, from which numerous follicles branch out into the substance of the gland. In the healthy subject they do not project beyond the pillars of the fauces, and hence are not seen.

**INFLAMMATIONS OF THE PHARYNX.****Give the etiology of acute pharyngitis.**

Persons of a tuberculous or rheumatic diathesis and those of sedentary habits are predisposed to attacks of acute pharyngitis. It is said to be most frequent in children. Cold is, as a rule, the exciting *cause* of this condition. It often occurs as a complication of other affections, such as acute rhinitis, acute tonsillitis, etc.

**What is the pathology ?**

There is engorgement of the blood-vessels, with an infiltration of round cells in the mucous membrane; the glands become enlarged, and their action is interfered with by the dilated blood-vessels. As the disease advances the secretion of the glands becomes increased.

**What are the symptoms ?**

In a large number of cases the constitutional symptoms are slight, consisting of some headache, lassitude, with perhaps a slight febrile disturbance. In other cases these symptoms are more marked. The attack is often preceded by a chill, followed by considerable fever. The local symptoms are first a feeling of dryness in the throat, followed by pain, which may be very severe, especially on swallowing. The patient has the sensation of a foreign body in the throat, causing repeated acts of swallowing. There is a desire to hawk and clear the throat. The voice is muffled, and the secretion, which at first was arrested, becomes increased. On inspection the posterior pharyngeal wall is seen congested. The congestion may be present on the posterior pillars and the posterior portion of the soft palate. In other cases congestion of the anterior





PLATE I.

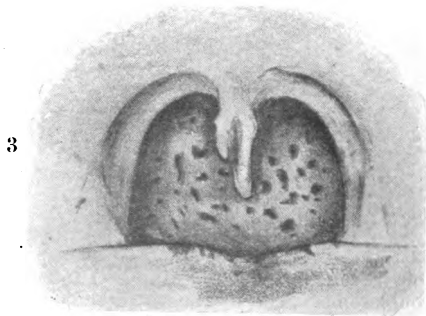
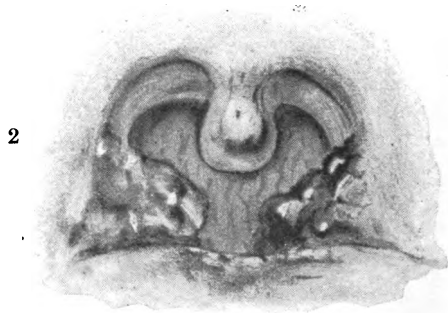
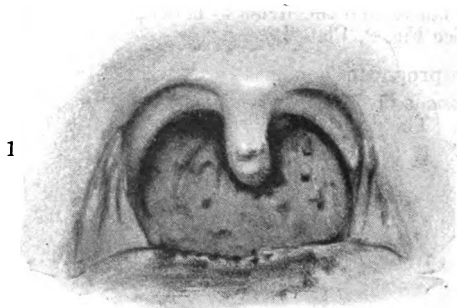


FIG. 1.—Fauces and Pharyngeal Wall in Phthisis.  
FIG. 2.—Acute Pharyngitis and Tonsillitis with Œdema of the Uvula.  
FIG. 3.—Chronic Pharyngitis with Bifid Uvula.

(Face page 161)

pillars of the fauces and the uvula is noticed. The tonsils may also be involved. (See Fig. 2, Plate I.)

### **What is the prognosis ?**

The *prognosis* is favorable, provided the inflammation does not spread to the larynx. The disease may become chronic.

### **What is the treatment of acute pharyngitis ?**

Opium and quinine may be given at the onset of the attack. A preparation of mercury, followed by a saline, is recommended by Lennox-Browne as a first step in the *treatment*. Where constitutional diatheses are present these should be treated by appropriate internal remedies.

Locally, the use of gargles is recommended by some and discounted by others. When given, one containing chlorate of potassium should be prescribed. Lozenges of guaiacum are often grateful, and should be given internally as well as locally, especially when a rheumatic diathesis is present. The sucking of ice often gives relief to some, while the taking of warm drinks gives relief to others. A 4 per cent. solution of cocaine gives temporary relief where there is much pain and congestion. Lennox-Browne especially advocates the use of menthol, employed in the form of a paint or spray. Seiler recommends the use of nitrate of silver in a strong solution, 60 grs. to ℥j.

### **What is the etiology of chronic pharyngitis ?**

It may be the result of repeated attacks of acute pharyngitis or the result of extension of an inflammation from one of the neighboring cavities, chiefly the nose. It is a common affection in those addicted to the use of alcohol and tobacco, and is frequently seen where disturbances of the digestive apparatus exist.

### **Give the pathology.**

There is dilatation of the blood-vessels, with serous infiltration of the tissues and thickening. The glands are found dilated, and after an acute exacerbation there is an increased secretion, due to over-stimulation of the glands.

### **What are the symptoms ?**

There is a feeling of dryness in the throat, which is generally relieved by a drink of some kind. The patient often experiences the sensation of a foreign body in the throat, and endeavors to relieve it by hawking and coughing. On examination the fauces appear swollen and relaxed. The uvula is, as a rule, seen to be more or less elongated. This elongation of the uvula produces a tickling sensation and cough, which may become very troublesome. The mucous membrane may or may not appear congested. A varicose condition of the smaller veins is noticeable in some cases. The examination not infrequently gives negative results. (See Fig. 3, Plate I.)

**What is the prognosis ?**

As regards life it is favorable. Persistent treatment often effects a cure.

**What is the treatment of chronic pharyngitis ?**

An avoidance of the causes that give rise to it must be enjoined. Where disturbances of digestion are present they should be remedied. Where irregularity of the bowels exists, calomel, Hunyadi water, etc. should be given. Where the symptoms are slight, the use of a gargle of chlorate of potassium often gives relief. Local applications should be made use of; nitrate of silver is one of the best. This should be applied daily by means of a cotton-applicator or brush. Sajous recommends it in the strength of 40 grains to the ounce. Chloride of zinc, 30 grains to the ounce, is also useful similarly applied. Where tonics are indicated they should be administered. Where extreme elongation of the uvula exists amputation often becomes necessary to remove some of the distressing symptoms.

**Give the etiology of granular pharyngitis.**

Mackenzie states that the chief cause of this condition is over-exertion of the voice, and that therefore it is found to exist chiefly among those who are compelled to make frequent use of the voice, such as lawyers, clergymen, etc. There is said to exist in some persons a predisposition to this disease, especially in those of a tuberculous diathesis. As an exciting cause "cold" is said to be the most common. Others attribute this condition of the throat to an excessive use of tobacco. It occurs most frequently in the young and middle-aged, and the male sex are more affected than the female. Those obliged to work in an atmosphere where the vapors of certain chemicals exist are liable to attacks of this disease.

**What is the pathology of this disease ?**

The chief pathological change in this condition, besides the changes present in chronic pharyngitis, is a blocking up of the follicles, and as a result swellings, so that small elevations appear on the wall of the pharynx.

**What are the symptoms ?**

Usually at the beginning of the disease the patient experiences a sensation of dryness in the throat, which may disappear only to return again. In those compelled to use their voice frequently hoarseness and loss of power are noticed upon the least exercise of the voice.

A sensation as if a foreign body were in the throat is often experienced, and as a result there is a constant desire to clear the throat. The discharge is usually muco-purulent. Cough is present in a large number of cases, and the larynx often becomes implicated. On inspection the mucous membrane is seen to be covered with small elevations,

varying in size and number. As the disease advances these elevations increase and coalesce with each other. In color they are reddish. When the patient gets an acute attack, they become greatly congested and inflamed.

#### **What is the prognosis ?**

This affection presents no danger to life. Under appropriate treatment, conducted over a long period of time, a cure is often effected.

#### **What is the treatment of granular pharyngitis ?**

The *treatment* should be both constitutional and local. Where any disorder of the general system exists, internal treatment should be combined with the local. Where constipation or disturbances of the digestion exist, appropriate remedies should be given.

The local treatment consists in the destruction of the granulations. For this purpose the galvano-cautery, carefully used, is one of the best methods. Cocaine may be applied before using the cautery to alleviate the pain. Nitrate of silver in solution, beginning with a weak solution and gradually increasing the strength, persistently applied for a long period of time, is said to often effect their removal. It may be also used in the form of the solid stick. Morell Mackenzie recommends the use of the London paste for their removal.

#### **Give the etiology of atrophic pharyngitis.**

It is a form of chronic pharyngitis, and may be a sequel of the hypertrophic condition. It may be also due to irritation from post-nasal discharges : it is frequently observed in atrophic rhinitis and in those exposed to the vapors of smoke, dust, etc. Breathing and sleeping with the mouth open may cause this condition.

#### **What are the symptoms ?**

Dryness, a tendency to swallow in order to moisten the parts. On examination the pharynx is seen to be glazed, dry, and shining, and is sometimes covered with masses of discharge of a muco-purulent nature.

#### **What is the treatment of atrophic pharyngitis ?**

Any constitutional disorder must be remedied by proper treatment. If nasal trouble, this should also receive attention. Locally, the parts must be kept cleansed, and applications of nitrate of silver, chloride of zinc, or a solution of iodine and glycerin applied. Gargles of chlorate of potassium are also serviceable. In children the administration of tonics, such as cod-liver oil, syrup of iodide, iron, etc., should not be neglected.

#### **Give the etiology of retropharyngeal abscess.**

Retropharyngeal abscess occurs most frequently in children. The majority of cases are idiopathic in their origin. Tuberculous and syphilitic patients seem especially predisposed to it. It occasionally occurs as

the result of scarlet fever. It is sometimes caused by traumatism. Necrosis of the vertebræ is present in a few cases, though this condition is rare.

### **What are the symptoms?**

In most cases the symptoms are inappreciable until swelling takes place. In some cases slight systemic disturbances may be present, such as chill, headache, etc. When the disease has advanced and there is considerable swelling, dysphagia is present, and possibly dyspnoea. The voice is thick and nasal resonance is absent. When the abscess is situated laterally, the patient holds his head toward the healthy side. There is often present an effort to clear the throat, as if endeavoring to get rid of a foreign body. On inspection, when the swelling becomes sufficiently advanced redness with bulging of the mucous membrane is recognized. By means of the index finger fluctuation can be detected if pus is present.

### **What is the prognosis?**

The *prognosis* in cases occurring idiopathically is favorable. In those occurring as the result of caries of the vertebræ the prognosis is less hopeful. Where there is a considerable quantity of pus present and spontaneous evacuation occurs, suffocation may result.

### **What is the treatment of retropharyngeal abscess?**

Where pus has formed evacuation by means of an incision at the most dependent portion of the abscess is indicated. This can be done by means of the laryngeal knife. As soon as the incision is made the head should be promptly bent forward to prevent the pus from entering the larynx. To avoid this danger some advocate the use of the trocar. Where suppuration has not taken place, ice should be applied externally and internally. In children with a tubercular diathesis internal treatment by the administration of cod-liver oil, syrup of the iodide of iron, etc. should not be neglected.

## **SYPHILIS OF THE PHARYNX.**

### **Give the etiology.**

Primary syphilis of the pharynx (chancre) is rare, though a number of cases are reported. It is usually the result of direct inoculation through kissing, through the use of improperly cleansed eating utensils which have been used by a syphilitic individual, or it may be the result of certain unnatural practices. Secondary and tertiary syphilis of the pharynx are more common than the primary.

### **What are the symptoms?**

In the primary form the *symptoms* are, as a rule, very slight. The glands under the angle of the jaw are often found painful and swollen. On inspection there is seen ulceration, which is superficial. The mucous

membrane may be slightly swollen, and on touching the ulceration the base is found to be indurated. In the secondary form there is a slight dryness of the throat, with some pain on swallowing. On inspection an erythema of the pharynx may be noticed, which is usually well defined. Mucous patches are present in a large number of cases. These are usually seen on the anterior pillars and the fauces, though they may show themselves in any portion of the mouth. At first they are elevated, but later become slightly ulcerated, changing in color to a grayish-white. They cause considerable pain on swallowing.

In the tertiary form a gummatous tumor is first noticed, which soon breaks down and ulcerates. The ulceration may be situated on one of the pillars of the fauces, on the tonsils, or on the soft palate. The ulcerations have sharply-cut edges and are covered with an ichorous-looking pus. Ulceration of the soft palate is liable to lead to perforation. When ulceration occurs on the posterior wall of the pharynx, adhesion with the soft palate may result, the parts healing together. The subjective symptoms are, as a rule, not well marked in the tertiary form. Pain is not usually present. Where there is destruction of the soft palate the voice becomes impaired.

#### **What is the prognosis?**

The *prognosis* as regards life is favorable, except where there are extensive destruction and ulceration in the tertiary forms and the process spreads to the base of the skull or vertebral column.

#### **What is the treatment of syphilis of the pharynx?**

In the secondary form, where mucous patches are present, iodine or the solid nitrate-of-silver stick should be applied. Internally mercury should be given. In the tertiary form the ulcerations should be touched with the nitrate of silver applied in the form of the solid stick. Insufflations of iodoform are often useful. Internally, iodide of potassium, beginning with small doses and gradually increasing the dose, should be administered.

### **TUBERCULOSIS OF THE PHARYNX.**

#### **Give the etiology.**

Whether tuberculosis of the pharynx ever occurs as a primary affection is still an open question. It is generally admitted to be a secondary manifestation of tuberculosis occurring in some other organ of the body.

#### **Describe the objective symptoms.**

Tuberculosis of the pharynx is seldom seen in the stage of infiltration. Usually the process has already advanced to the stage of ulceration. The ulcerations are lenticular in shape, and their extension is more superficial than deep. They have slightly raised edges, and their floor is studded with granulations covered with unhealthy pus. (See Fig. 1,

Plate I.) In the neighborhood of the margins of the ulcers are often seen miliary nodules. The glands of the neck are, as a rule, swollen.

### What are the subjective symptoms ?

Pain is the chief *symptom* present. It is most intense on swallowing. The pain may extend to the ear through Jacobson's nerve. The other symptoms are loss of appetite, emaciation, loss of strength, night-sweats, cough, and hoarseness.

### Give the diagnosis of tuberculosis of the pharynx.

The only disease the physician is apt to mistake it for is syphilis. The differential *diagnosis* between syphilitic and tuberculous ulcerations is given below. (It is Bosworth's classification somewhat modified by Lennox-Browne.)

#### *Syphilitic Ulcers.*

Deeply excavated.  
Few granulations, and those highly inflammatory.  
Deep-red areola.  
Sharply-cut edges.  
Distinct demarcation.  
Yellow purulent secretion.  
Discharge profuse.  
Penetrating to deeper tissues.  
  
No fever.

#### *Tuberculous Ulcers.*

No apparent excavation.  
Much indolent granulation.  
  
Faint areola.  
Irregular and ill-defined edges.  
Demarcation indistinct.  
Grayish, ropy mucous secretion.  
Discharge scanty.  
Superficial, with lateral in place of deep extension.  
  
Fever.

### What is the prognosis ?

The *prognosis* is unfavorable.

### What is the treatment of tuberculosis of the pharynx ?

In the local *treatment* the main object to be sought for is the alleviation of pain. This is best accomplished by the application of a 10 per cent. solution of cocaine. Insufflations of morphine are also useful. For the destruction of the ulceration Krause of Berlin recommends the application of lactic acid, first scraping away the granulations by means of a curette. Lennox-Browne recommends the use of the galvano-cautery. Steam inhalations are grateful, especially those containing menthol. Sucking of ice often alleviates the pain. The food should be soft in quality, such as thick soups, broths, etc. Where the dysphagia is extreme the patient should be fed by means of Delavan's tube or per rectum. Constitutional treatment should receive special attention, and consists chiefly in the administration of cod-liver oil, the hypophosphites, etc.

**NEUROSES OF THE PHARYNX.****Give a short description of anæsthesia of the pharynx.**

Anæsthesia of the mucous membrane of the pharynx can either be central or peripheral in its origin. Among the central lesions with which it occurs may be mentioned tumors of the brain, lateral sclerosis, bulbar paralysis, etc. It occurs in epileptic seizures, in cholera, typhus, and in hysteria. It is most frequently observed, peripherally, as a sequel of diphtheria. Certain drugs, such as cocaine, morphine, chloral, the bromides, may induce anæsthesia.

The *diagnosis* is made by objective examination. The affected portion is insensible to chemical or mechanical irritation. As a rule, the reflexes are reduced or completely lost.

The *treatment* consists in the local application of electricity and the administration of strychnine.

**Describe hyperæsthesia of the pharynx.**

Hyperæsthesia is an increased sensitiveness of the mucous membrane, especially when an attempt at a laryngoscopic or rhinoscopic examination is made. It may be due to an elongated uvula or chronic pharyngitis, and is seen in excessive drinkers, smokers, and nervous individuals.

The *treatment* consists in the application of cocaine when a laryngoscopic or rhinoscopic examination is desirable. Chloral hydrate and bromide of potassium are recommended.

**What is paræsthesia of the pharynx ?**

Paræsthesia consists in abnormal sensations in the pharynx. These may be a pricking or burning, a feeling of soreness, but most commonly as if a foreign body, such as a hair, a needle, a piece of bread, etc., were present. It occurs in chronic catarrh, chiefly in granular pharyngitis. It is seen in anæmia, chlorosis, phthisis, neurasthenia, and in hypochondriacs. Lennox-Browne is of the opinion that these sensations are symptomatic of some objective, but not always discovered, cause. Among the causes he mentions are—1, varicose veins at the base of the tongue; 2, hypertrophy of the pharyngeal tonsil; 3, slight enlargement of the thyroid gland.

**What is the treatment of paræsthesia of the pharynx ?**

It consists in the removal of hypertrophied tissue by means of the galvano-cautery, the internal administration of bromides, and the local treatment of any catarrhal conditions present in the nose or pharynx.

**To what are motor paralyses due ?**

They may be of cerebral origin. When they are, they are the result of injury or disease of the brain and pneumogastric; if of peripheral origin, they are the sequel of various local diseases.



**What is the treatment?**

The *treatment* consists in the application of electricity and the administration of strychnine and tonics.

**TUMORS OF THE PHARYNX.****What tumors are occasionally met with in the pharynx?**

Carcinoma, sarcoma, cysts, fibroma, lipoma, papilloma, and angioma.

**Give the symptoms and treatment.**

The *symptoms* vary according to the size and situation of the tumor. When sufficiently large it gives rise to disturbances of speech, difficulty in swallowing, and difficulty in respiration.

The *treatment* consists in extirpation where this is possible. This can be effected by means of the galvano-cautery, snare, or knife.

**FOREIGN BODIES IN THE PHARYNX.****What foreign bodies may lodge in the pharynx?**

Fish-bones, chicken-bones, needles, pins, tacks, bread, false teeth, etc.

**What are the symptoms?**

The *symptoms* vary according to the size, situation, and character of the foreign body. Pointed articles cause sharp pain when swallowing or speaking. They may cause inflammation, oedema, and ulceration, and, through piercing a blood-vessel, serious hemorrhage. Large foreign bodies in the lower portion of the pharynx may give rise to difficulties of breathing, and even to suffocation by pressure on the epiglottis. Foreign bodies may also lodge in the sinus pyriformis. Patients may swallow a foreign body and eject it again. This fact should not be lost sight of during the examination.

**What is the prognosis?**

The *prognosis* is, as a rule, favorable, but serious consequences may ensue, even leading to death by asphyxia, or by hemorrhage when a blood-vessel has been perforated.

**What is the treatment for foreign bodies in the pharynx?**

The foreign body should be first located by examination, the laryngeal mirror serving as an aid. Where this is impossible the finger should be used, and the foreign body often can be removed by its means. When seen it should be extracted by means of forceps.

**DISEASES OF THE TONSIL.****What are the causes of acute tonsillitis?**

Among the predisposing causes of this affection may be mentioned a rheumatic or tuberculous diathesis, hereditary influences, and sudden

changes of temperature. It is most prevalent between the ages of twelve and thirty. The usual exciting cause is exposure to cold and dampness. Lennox-Browne mentions as other causes those which are septic in their nature, such as the drinking of impure water and the exhalations of sewage gas.

### **What are the symptoms?**

The disease may involve the parenchyma of the organ, *parenchymatous tonsillitis*, usually leading to the formation of an abscess when deep seated. When the crypts of the tonsils are involved, with the exudation of a cheesy matter from the follicles, it is called *follicular tonsillitis*.

Subjective symptoms are, as a rule, present, a chill marking the onset of the disease. This is followed by fever, headache, pains in the back and limbs, and loss of appetite. A feeling of dryness is experienced, soon followed by pain which is severe in character, especially on swallowing, and often extends to the ear. The speech becomes thick and unintelligible. Hearing may be impaired, as also the senses of taste and smell.

Some difficulty is experienced in making an examination, owing to the pain caused by movements of the jaw. The tongue is heavily coated, and the affected tonsil or tonsils will be seen swollen and inflamed. In some cases there is considerable peritonsillar swelling, especially if there be formation of pus. In the follicular form the mouths of the follicles are covered with a creamy, cheesy exudation. With the finger one may be able to detect whether suppuration has taken place.

### **What is the prognosis?**

The *prognosis* is, as a rule, favorable, a fatal termination being the exception.

### **What is the treatment of acute tonsillitis?**

A cathartic should be administered at the beginning of the attack. Guaiacum, given early, is regarded as a specific. It may be given in the form of lozenges, powder, or the ammoniated tincture. A teaspoonful of the latter should be given at a dose, and can be taken in a half glass of milk. After two or three days, scarification, when much inflammation exists, has been recommended. This practice is condemned by some authors. The application of warm poultices is beneficial. German authors recommend the application of cold. This can be applied by taking a cloth, wringing it out in cold water, and applying over this a perfectly dry cloth. Gargles, steam inhalations, sucking of ice, warm drinks, have all proved serviceable.

In the follicular form Bosworth recommends 2 drachms of the tincture of chloride of iron to 2 ounces of glycerin. Of this a teaspoonful should be administered every two hours without water. Where suppuration has taken place incision with a bistoury is indicated.

**Give the etiology of hypertrophy of the tonsils.**

Hypertrophy of the tonsils is usually a disease of early life, rarely occurring after thirty. It may occur as a sequel of scarlet fever, measles, or small-pox. Repeated attacks of catarrh in tuberculous children are said to lead to this condition.

**What are the symptoms?**

Where there is considerable enlargement nasal respiration is interfered with, and, as the condition is usually associated with adenoid vegetations in children, the patient sleeps with the mouth open and snores loudly. Speech is thick and full, and hearing is often impaired. The face where there is considerable enlargement assumes the expression so pathognomonic of adenoid vegetations. On inspection the condition is easily recognized.

**What is the treatment of hypertrophy of the tonsils?**

Where there is but slight enlargement astringents may be used, such as the perchloride of iron (3j to ʒj), alum, or tannin. Where sufficiently large the tonsils should be removed. This can be effected by means of the tonsillotome. The tonsillotomes chiefly used are those of Matthieu and Morell Mackenzie. Each of these has its advocates. When the tonsil is so large that the application of the tonsillotome is impossible, then the wire-loop *écraseur* may be used. Serious hemorrhage is rare, and can usually be checked by ice-water or the gargle of tanno-gallic acid recommended by Mackenzie. It is composed of 6 drachms of tannic acid and 2 drachms of gallic acid in an ounce of water. Half a teaspoonful of this should be sipped at short intervals. Lefferts recommends in severe cases of hemorrhage pressure within the mouth and counter-pressure outside. The galvano-cautery is highly praised by some, and is advocated by Knight in patients with a hemorrhagic tendency.

**DISEASES OF THE UVULA.****What are the causes of relaxed throat or elongated uvula?**

This condition is frequently met with in those affected with chronic catarrh or those addicted to excessive smoking, overuse of the voice, and drinking. Also gastric disturbances are mentioned as causes.

**What are the symptoms?**

These vary. A desire to clear the throat is present on rising in the morning: cough as a result of irritation; and when lying down at night the relaxed uvula causes considerable trouble, and may even occasion spasm of the glottis. The voice is easily fatigued, and there is often pain after using it. On inspection, the patient holding his tongue, the uvula is seen lying on the tongue.

**What is the treatment of relaxed throat?**

First is the use of astringents, and of these alum in the proportion of gr. xx to ʒj may be used every two or three hours as a gargle. (Gargle of chlorate of potassium is often useful.) The application of chloride of zinc gr. xxx to ʒj, combined with internal *treatment*, often effects a cure. Where these fail and the symptoms continue troublesome, ablation of the uvula should be performed. In this operation the uvula is well drawn out with forceps, and removed just above the point of junction of the mucous membrane with the body of the uvula by means of scissors. Uvulotomes have been devised, and are used by some. The bleeding may be excessive, but is easily checked. The diet after the operation should be liquid or soft. Soothing gargles should also be given.

**ADENOID VEGETATIONS (HYPERTROPHY OF THE PHARYNGEAL TONSIL).****What is the etiology?**

This condition occurs chiefly in childhood and adolescence, and is rarely seen after the age of twenty. A "lymphatic temperament," according to Loewenberg, predisposes to it. Acute and chronic inflammations of the nose and pharynx, occurring as sequels to scarlet fever, measles, and whooping cough, may give rise to it.

**What are the symptoms?**

These consist in change in voice, with loss of resonance, the words sounding dull and muffled; inability to breathe through the nose, thereby compelling the patient to breathe through the mouth. The patient, as a rule, sleeps with the mouth open and snores loudly. As a result there is drooping of the lower lip, and the face assumes that heavy, stupid expression so pathognomonic of this condition. Sense of hearing may be affected, varying from slight ringing in the ears to a high degree of deafness. The senses of taste and smell also suffer. The patient may complain of pain in the occipital or a sensation of pressure in the frontal region. In children, if the condition be allowed to progress, the patient becomes anæmic; chest remains flat, undeveloped, and sunken in.

The *diagnosis* is, as a rule, easily made. The history of the case, with the characteristic facial expression, aids greatly in making a diagnosis. Where examination is possible the growths are readily seen. Where this is impossible, the index finger passed into the naso-pharynx will confirm the diagnosis.

**What is the treatment of this condition?**

The *treatment* consists in its removal. For this purpose the cautery has been recommended where the growths are not large. Guyé of Am-

sterdam uses his finger-nail to scrape away the growth. Lennox-Browne of London uses a curette connected to the finger by means of a cylinder, which also acts as a finger-shield. Chiari of Vienna uses a cold snare, introduced through the anterior nares. This method is effective, and has the advantage of causing but little bleeding. Probably in the majority of operations the post-nasal cutting forceps are used. They consist of a pair of curved forceps with sharp cup-shaped blades at their ends. These require to be introduced several times before the growths

FIG. 59.

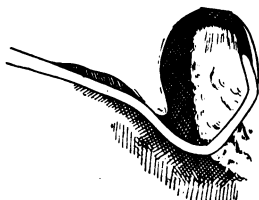


FIG. 60.



are completely removed, and also the use of an anæsthetic. An instrument which of late has proved highly effective for the removal of these growths is Gottstein's newly-improved curette. This instrument has a

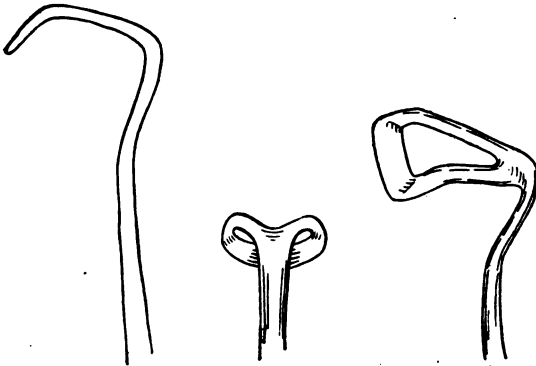
FIG. 61.



curvature specially adapted to the anatomy of the naso-pharynx, so that there is no danger of removing or injuring any of the structures other than the hypertrophied pharyngeal tonsil. In performing the operation the instrument is introduced sideways into the patient's mouth, passed beneath the soft palate and up along the anterior wall of the naso-pharyngeal space, with the cutting edge directed toward the posterior wall, until the vault of the pharynx is reached. The physician then places his left hand behind

the patient's head in order to hold it securely, depresses the handle of the instrument so that the cutting edge is brought directly in front of the growth, and with a backward and downward movement of the instrument removes it. The advantages are—quickness, no necessity for an anæsthetic, and thoroughness, provided the instrument be properly introduced. By reference to Figs. 59, 60, 61, and 62 the instrument and its method of introduction can be seen.

FIG. 62.



Gottstein's Curette.

## THE LARYNX.

### ANATOMY OF THE LARYNX.

#### Give the anatomy of the larynx.

The larynx is situated between the trachea and base of the tongue. It is composed of cartilages connected by ligaments and membranes and acted upon by muscles. The cartilages are nine in number—three single and three pairs. The single are the thyroid, cricoid, and epiglottis; the pairs are two arytenoid, two cartilages of Santorini, and the two cartilages of Wrisberg (Fig. 63).

The thyroid cartilage consists of two plates united at an acute angle, forming a projection known as the pomum Adami. To the angle are attached the vocal cords and the thyro-arytenoid muscles. The superior horns are connected with the hyoid bone by the thyro-hyoid ligaments and the thyro-hyoid membrane.

The epiglottis is attached to the upper margin of the thyroid by the thyro-epiglottic ligament; below the thyroid is connected with the cricoid cartilage by the crico-thyroid membrane, and to the arytenoids it is united by the vocal cords and the thyro-arytenoid muscles.

The cricoid cartilage, receiving its name from its resemblance to a ring, is connected with the thyroid, as seen above, and on it rotate the arytenoids; it also serves for the attachment of muscles.

The arytenoid cartilages are situated at the back of the larynx, and articulate by their bases with facets on the upper and posterior part of the cricoid. Each has two processes—one, external, the processus mus-

cularis; the other anterior, the processus vocalis, which is visible through the laryngoscope.

The arytenoid cartilages are connected with the epiglottis by the ary-epiglottic folds, and with the thyroid by the thyro-arytenoid ligaments.

FIG. 63.

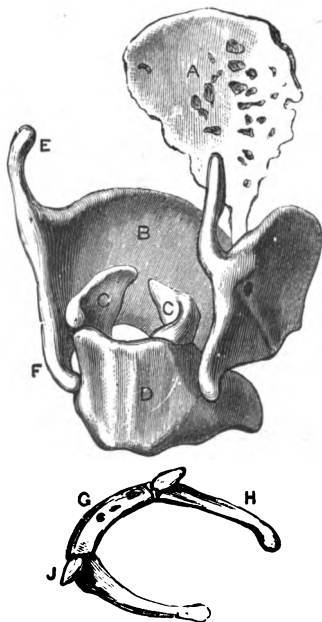


FIG. 64.

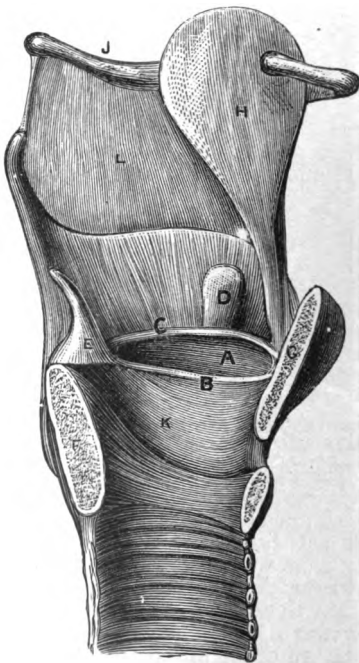


Fig. 63.—Hyoid Bone and the Laryngeal Cartilages (Ellis): G, body of the hyoid bone; H, large cornu; J, small cornu; A, epiglottis; B, thyroid cartilage; C, arytenoid cartilage; D, cricoid cartilage; E, upper cornu, and F, lower cornu of the thyroid cartilage.

Fig. 64.—Vocal Apparatus, on a Vertical Section of the Larynx (Ellis): A, ventricle of the larynx; B, vocal cord; C, ventricular band; D, sacculus laryngis; E, arytenoid cartilage; F, cricoid cartilage; G, thyrod cartilage; H, epiglottis; K, crico-thyroid ligament; L, thyro-hyoid membrane.

The cartilages of Santorini are two small cartilages situated above the apices of the arytenoids.

The cartilages of Wisberg are imbedded in the ary-epiglottic folds. They terminate in two rounded projections above the cartilages of Santorini.

The ventricular bands, or false vocal cords, are attached in front to the thyroid and posteriorly to the arytenoid cartilages (Fig. 64).

The vocal cords are attached to the thyroid and arytenoid cartilages.

FIG. 65.

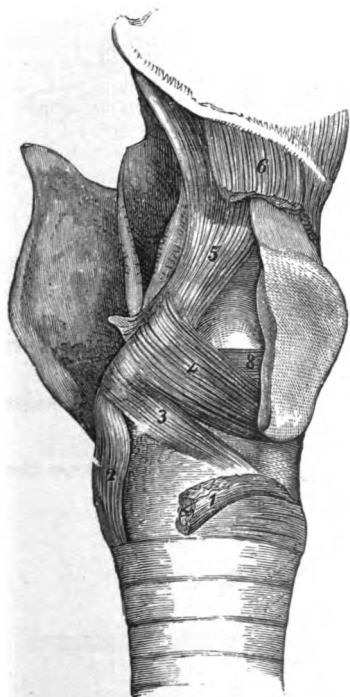

FIG. 66.

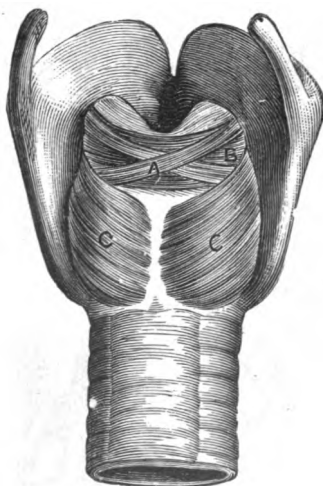


Fig. 65.—View of the Internal Muscles of the Larynx (Ellis): 1, Crico-thyroides detached; 2, crico-arytenoideus posticus; 3, crico-arytenoideus lateralis; 4, thyro-arytenoideus, superficial part; 5, depressor of the epiglottis; 6, thyro-hyoideus, cut; 8, deeper part of thyro-arytenoideus.

Fig. 66.—Posterior View of the Larynx (Ellis): A, Superficial part of the arytenoideus muscle; B, deep part of the arytenoideus; C, crico-arytenoideus posticus.

They are composed of yellow elastic tissue covered with mucous membrane.

The ventricles of Morgagni are two pockets situated in the side walls of the larynx between the true and false vocal cords.

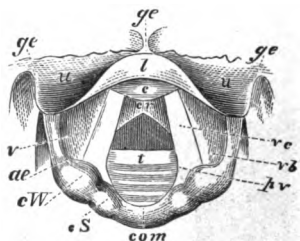


The sacculus laryngis is a sac placed between the false vocal cord and the inner surface of the thyroid cartilage.

The muscles are—

I. The crico-arytenoidei postici, the abductors of the vocal cords.

FIG. 67.



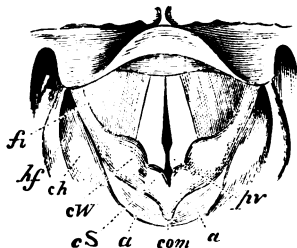
Laryngoscopic Diagram, showing the vocal cords widely drawn apart, and the position of the various parts above and below the glottis, during quiet breathing (from Mackenzie): *ge*, glosso-epiglottic folds; *u*, upper surface of epiglottis; *l*, lip or arch of epiglottis; *c*, protuberance of epiglottis; *v*, ventricle of the larynx; *ae*, ary-epiglottic fold; *cW*, cartilage of Wrisberg; *cS*, cartilage of Santorini; *com*, arytenoid commissure; *ec*, vocal cord; *vb*, ventricular band; *pv*, processus vocalis; *t*, rings of trachea (Seiler).

II. The crico-arytenoidei laterales. These rotate the processus vocales inward.

III. The arytenoideus approximates the arytenoid cartilages.

IV. The thyro-arytenoidei, external and internal. They draw the

FIG. 68.



Laryngoscopic Diagram, showing the approximation of the vocal cords and arytenoid cartilages, and the position of the various parts, during vocalization (from Mackenzie): *fi*, fossa innominata; *hf*, hyoid fossa; *ch*, cornu of hyoid bone; *cW*, cartilage of Wrisberg; *cS*, cartilage of Santorini; *a*, arytenoid cartilages; *com*, arytenoid commissure; *pv*, processus vocalis and cartilages of Seiler (Seiler).

arytenoid cartilages, together with the back part of the cricoid, forward toward the thyroid, and thus shorten and relax the vocal cords.

V. The crico-thyroides draw the cricoid upward (its anterior part), thus producing tension of the cords.

VI. The ary-epiglottici tend to bring the tips of the arytenoid cartilages together and make the epiglottis curve inward at its edges.

The arteries are the laryngeal branches from the superior and inferior thyroid.

The nerves are the superior laryngeal and the inferior or recurrent laryngeal, both branches of the pneumogastric, with a few filaments from the sympathetic.

The mucous membrane is continuous with that lining the mouth and the pharynx, and the epithelium is of the ciliated variety.

The chief physiological formation is the production of voice; it also has duties in reference to deglutition and respiration.


By reference to Figs. 67 and 68 the larynx is seen during respiration and phonation.

### LARYNGOSCOPY.

**What is understood by laryngoscopy? and when is a laryngoscopic examination made?**

Laryngoscopy is the art of examining the larynx. For this purpose

FIG. 69.



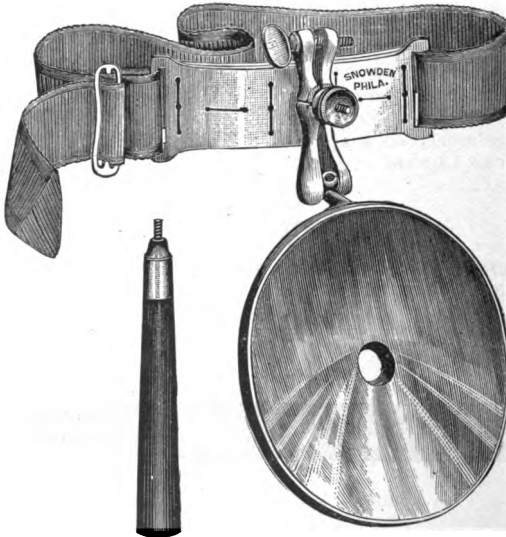
Laryngeal Mirror.

are required—1st, a laryngeal mirror (Fig. 69); 2d, a head reflector (Fig. 70); 3d, light.

In making a laryngeal examination the patient is directed to hold out his tongue, which is grasped by means of a towel or handkerchief between the thumb and index fingers. The laryngeal mirror is then held over the light and warmed, so as to prevent the condensation of moisture upon its reflecting surface. It is then introduced into the mouth, and as soon as the uvula is reached the back of the mirror is placed against it, and it is pushed upward and backward, and the handle of the mirror

gently depressed. By directing the patient to say "ah" or "eh" the epiglottis is raised, and a view of the larynx with the vocal cords is obtained. By reference to Fig. 71 the laryngeal mirror is seen held in the correct position, whilst Fig. 72 shows the mirror incorrectly held.

FIG. 70.



Head Reflector.

### What are the obstacles to a laryngoscopic examination?

1, a short frænum linguæ; 2, an unmanageable tongue; 3, hypertrophy of the tonsils; 4, elongation of the uvula; 5, a faulty introduction of the mirror on the part of the physician; 6, an overhanging epiglottis; and 7, an irritable or sensitive pharynx. The latter can be overcome by painting the parts with a 4 per cent. solution of cocaine, administration of bromide of potassium, or gargling with ice-water.

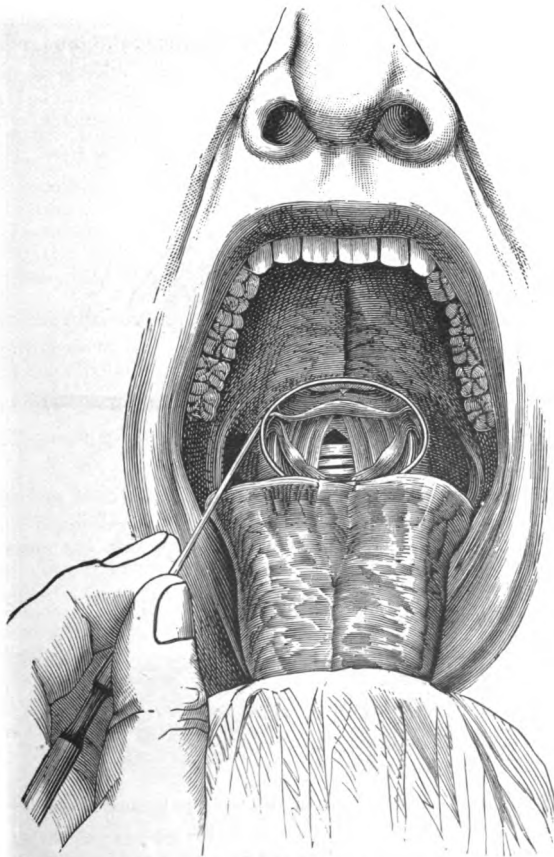
### INFLAMMATIONS OF THE LARYNX.

#### Give the etiology of acute laryngitis.

Cold, sudden changes of temperature, inhalation of damp air, wet feet, etc., may all give rise to an attack of acute laryngitis. It occurs not infrequently in clergymen, teachers, and singers after over-exertion

of the voice. Hot drinks, the inhalation of hot dry air and the vapors of various chemicals, as well as the excessive use of tobacco and alcohol,

FIG. 71.



Laryngeal Mirror in position, displaying the laryngeal image (Cohen).

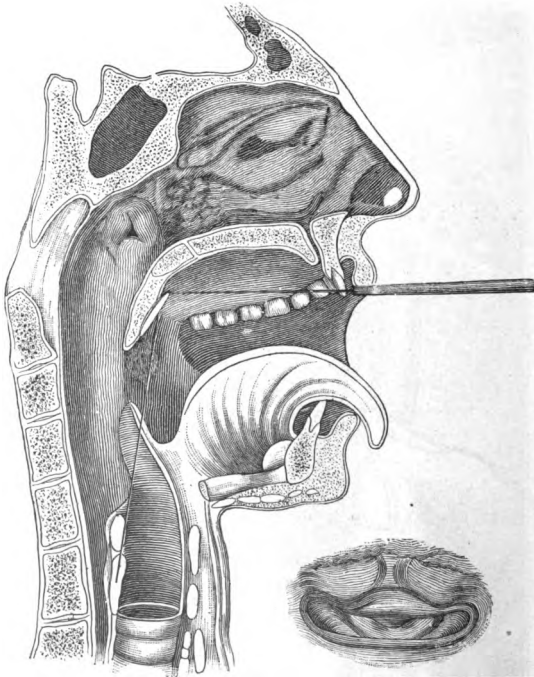
may cause an attack. It is often seen as a complication of measles, variola, typhoid and scarlet fever. Tubercular and syphilitic individ-

uals are predisposed to it. It occurs in men more often than women, and in adults more than children.

**What is the pathology?**

There are hyperæmia, swelling, and an increased and changed secretion. These vary in their intensity as well as in their extent. The catarrh may

FIG. 72.



Faulty Position of Laryngeal Mirror, with resultant laryngeal image (Seiler).

confine itself to different portions, such as the entrance of the larynx, the interarytenoid space, etc., or it may affect the entire larynx. There may be loss of epithelium, which rarely advances to true ulceration. The secretion is at first slight; later it becomes increased in quantity and gelatinous, transparent, or grayish-yellow in color.

**What are the symptoms?**

Acute laryngitis may occur without any prodromal symptoms, or be preceded by a slight chill, followed by some febrile disturbances. The first *symptoms* experienced by the patient are a sensation of pressure and dryness and a feeling of soreness. Cough is at first slight and dry, but becomes troublesome, owing to the exertions to clear the throat. When exudation occurs, it becomes loose. In children cough is more severe. The voice may be but slightly changed, but in most cases is usually rough and deep in quality. Difficulty of breathing is rare in adults, but in children it is marked and often assumes a serious nature. Pain is, as a rule, never severe, but there is a feeling of soreness. Expectoration is at first slight, of a mucous nature, and clear; later it becomes more profuse and yellowish. Swallowing is not painful unless the epiglottis or pharynx becomes involved. The laryngoscopic appearances vary according to the severity and extent of the inflammation. When this is slight, hyperæmia of the mucous membrane is seen, involving different portions of the larynx or the entire larynx. Swelling is present in some cases, and slight erosions may be seen, though true ulceration is rare.

**What is the diagnosis?**

The *diagnosis* is easy, except perhaps in the case of young children, when the use of the laryngoscopic mirror is difficult.

**What is the prognosis?**

The *prognosis* is generally favorable; when neglected it may become chronic.

**What is the treatment of acute laryngitis?**

At the beginning of the attack a dose of calomel may be given; expectorants are also recommended. Locally steam inhalations are serviceable. The following has been found useful:

R. Menthol,                    ʒss;  
Tinct. benz. co., ʒj.—M.

Sig. A teaspoonful to a pint of boiling water, and inhale.

In children the inhalation of steam from a kettle is recommended. Applications to the larynx should be avoided and children should be kept in-doors. Cold applied to the neck, or poultices, may be advised.

**Give the etiology of acute œdema of the larynx.**

Acute œdema of the larynx may be primary or secondary. It occurs frequently during the course of an acute laryngeal catarrh. It may occur as a secondary affection in other forms of inflammation of the larynx, such as syphilis, tuberculosis, perichondritis, in the laryngeal affections of diphtheria and the various exanthemata, in parotitis, in inflammations of the thyroid and cervical glands, and even the tonsils. It is seen in

the acute inflammation of the larynx resulting from burns, wounds, scalds, and other injuries. By some it is said to occur as a complication of Bright's disease. Among predisposing causes may be mentioned a low state of health and bodily fatigue.

### **Give its pathology.**

Œdema of the larynx shows itself anatomically as a yellowish-white swelling (occasionally reddish). It occurs most frequently in the upper portions of the larynx; the epiglottis, the ary-epiglottic folds, in the false vocal cords, in the mucous membrane of the arytenoid cartilages (seldom on the vocal cords); and consists of a transudation into the submucosa, which is usually serous, sero-purulent, or sanguineous. The histological appearances show distension of the muscles and the areolar tissue by the exudation.

### **What are the symptoms?**

The chief symptom is dyspnoea, which at first is paroxysmal. As the œdema advances both expiration and inspiration are interfered with; the dyspnoea becomes extreme, cyanosis develops, the eyeballs protrude, and the pulse becomes small and feeble. The voice is not affected to a marked degree. Cough may be present, but is usually due to efforts to clear the throat. Deglutition is painful, especially when the epiglottis is involved. With the laryngoscope the œdema is easily recognized. The epiglottis has the appearance of a semi-transparent body or shows swellings pressed against each other. Where acute inflammation is present capillary injection is seen. The swellings of the ary-epiglottic folds are egg-shaped. They often prevent a view of the lower portion of the larynx. When the œdema is subglottic, two transparent swellings are seen apparently springing from the under surface of the vocal cords.

### **What is the prognosis?**

The *prognosis* is, as a rule, bad, except, perhaps, where the œdema is partial.

### **What is the treatment of acute œdema of the larynx?**

Ice administered externally and internally, application of leeches, are measures which should be tried. When these fail, scarification should be performed by aid of the laryngoscope. Where this fails to give relief, tracheotomy then become necessary.

### **Give the etiology of chronic laryngitis.**

It is often the sequel of an acute laryngitis. It occurs in teachers, clergymen, singers, etc., and especially in those who do not know how to use the voice. Those who live in an impure atmosphere are subject to this affection. The excessive use of tobacco and alcohol is a frequent cause of chronic laryngitis. In the case of alcoholic individuals who are suffering from chronic pharyngitis it is doubtless the result of accumulation of mucus, which, dropping during sleep from the pharynx into the

larynx, sets up irritation. An elongated uvula, by irritating the entrance of the larynx and epiglottis, is said to be a frequent cause. In boys continued use of the voice when it is changing often results in a chronic laryngitis. It is a frequent complication of the various exanthemata, and is present in syphilis and tuberculosis. It is most frequent among adults, and more common in males than females.

#### **Give its pathology.**

There is dilatation of the vessels, hypertrophy of the mucous membrane, and a changed secretion. The mucous membrane is thickened, uneven, rough, and often covered with granulations. In some cases, where the affection has existed for some time, there is hyperplasia of connective tissue. The secretion is transparent, grayish, or muco-purulent; sometimes it is dried in crusts. Erosions are often present, but true ulceration is rare.

#### **What are the symptoms?**

The subjective symptoms are often slight. Pain is, as a rule, rare, except after vocal exertion. Instead, there is often a sense of constriction present, or the sensation as if a foreign body were in the throat. The voice is changed. Hoarseness is present, varying with the degree of inflammation. Aphonia not infrequently occurs after continued use of the voice. Cough may be absent, unless there is bronchial catarrh. Respiration is, as a rule, not affected. The secretion is scanty, grayish-white, and is often expectorated in the form of hard crusts.

#### **What is seen on laryngoscopic examination?**

The laryngoscopic examination shows hyperæmia and swelling, which vary according to the intensity and extent of the inflammation. The hyperæmia may affect the mucous membrane of the larynx in its entirety or be confined to individual portions. The same can be said of the swelling. It seldom affects the whole larynx. The epiglottis is often thickened, especially in toppers. Sometimes the false vocal cords are swollen to such a degree that very little can be seen of the true cords, and often the false cords meet during phonation, so that the voice has a hoarse sound. When swelling exists in the interarytenoid space it often prevents the complete closure of the glottis, and thereby also the movement of the cords. Lewin states that a thickening of the ary-epiglottic folds is often observed in preachers. Turck describes a roughened appearance of the cords, which he designates as chorditis tuberosa. Secretion is seen in the form of small pellets or forming small bridges which extend from one cord to the other, and motility may be disturbed. Erosions are often seen, especially in the vocal cords and in the arytenoid space.

#### **Give the diagnosis.**

A thorough laryngoscopic examination is the only method by which an accurate *diagnosis* can be made. Where chronic laryngitis has been



present for some time there should be a careful examination of the lungs, as well as an inquiry concerning the family history and the general condition of the patient.

### **What is the prognosis?**

Chronic laryngitis rarely terminates fatally. A cure may be often effected by persistent treatment and an avoidance of those causes which tend to keep up the condition.

### **What is the treatment of chronic laryngitis?**

The *treatment* consists chiefly in local applications to the larynx in the form of spray, powder, or applied by means of a brush or cotton-applicator. One of the best solutions is that of the chloride of zinc, in the strength of from 10–30 grs. to the ounce. Mackenzie recommends its application in the following manner: It should be made daily for the first seven days, on alternate days during the second and third weeks, twice in the fourth week, and so on at gradually increasing intervals until a cure is effected. Nitrate of silver, applied by means of a brush or cotton-applicator, is also recommended in solution from 4 to 10 per cent. Besides these are recommended iron, alum, zinc sulph., etc. Spray inhalations of tannin, 1–5 gr., chloride of zinc, 2–10 gr., are often useful. Steam inhalations of benzoïn, pine oil, creasote, are beneficial. The general health of the patient should also receive attention. Where the disease is the result of a pharyngitis or nasal trouble, these should first receive treatment. Enlarged tonsils and obstructions in the nasal passages should all be removed. Over-exertion in those compelled to use the voice should be avoided, and as much rest as possible given to the voice during treatment. Application of wet compresses and the painting of the thyroid cartilage with tincture of iodine are recommended by Lennox-Browne.

## **TUBERCULAR LARYNGITIS.**

### **Give the etiology of tuberculous laryngitis.**

It is usually a secondary manifestation of tuberculosis of the lungs. Whether it ever occurs as a primary affection is still a disputed question. A low state of vitality is a predisposing cause. It occurs more frequently in men than in women, and usually between the ages of twenty and forty.

### **Give, briefly, the pathology.**

The first stage in the process is that of infiltration and swelling. This is, as a rule, situated in the interarytenoid space, on the coverings of one or both of the arytenoid cartilages and on the corresponding ary-epiglottic fold, less frequently on the epiglottis. The swelling is seen to consist microscopically of a cellular infiltration into the subepithelial or submucous cellular tissue, which is found to be made up of more or less



PLATE II.

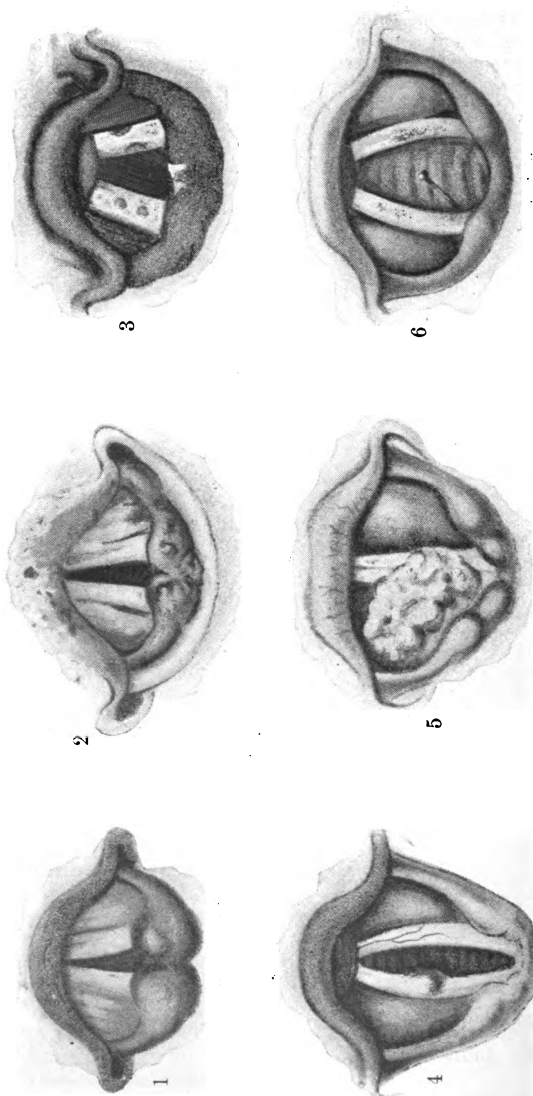


FIG. 1.—Laryngeal Image from a Case of Phthisis, showing the pyriform swelling of the arytenoid cartilages.  
 FIG. 2.—Tubercular Ulceration of the Epiglottis and Tubercular Nodules on the Ary-epiglottic Folds.  
 FIG. 3.—Syphilitic Ulceration of the Vocal Cords and of the Interarytenoid Space.  
 FIG. 4.—Fibro-cellular Tumor on the Right Vocal Cord.  
 FIG. 5.—A large Papillomatous Tumor springing from the Right Ventricular Band.  
 FIG. 6.—A Pin imbedded in the Posterior Portion of the Right Vocal Cord.  
 (Face page 185.)

circumscribed tubercles, consisting each of nuclei, detritus, giant-cells, and leucocytes. The glands become changed, either through an extension to them of the tubercular process or primarily through inflammation. A section of a blood-vessel shows an accumulation of round cells. As soon as the tubercular infiltration has reached the lowest boundary of the epithelial layer, this becomes lifted off from the basal membrane: perforation ensues, which soon advances to ulceration, forming the typical tuberculous ulcer. Caries and necrosis of the cartilages not infrequently take place, and new growths have been observed accompanying tuberculous laryngitis.

### **What are the symptoms ?**

The patient, as a rule, in the beginning complains of peculiar sensations in the throat; the voice is easily tired and there is a tendency to hoarseness, or aphonia may be present. Difficulty of swallowing is not always present, but where the epiglottis becomes involved or the arytenoids, then swallowing becomes very painful. Cough is usually a constant symptom, and is often very distressing. Shortness of breathing is occasioned by the lung affection, but where swelling leads to loss of mobility and the cords become thickened and ulcerated, then dyspnoea may ensue.

### **What are the laryngoscopic appearances ?**

The laryngoscopic appearances show in the early stage anæmia of the mucous membrane. When the process has farther advanced, infiltration is seen, which is most frequently situated in the interarytenoid space, next to this on the false vocal cords and arytenoid cartilages, and less frequently on the vocal cords, the ary-epiglottic ligament, and the epiglottis. When the arytenoid cartilages are affected, they appear as pyriform swellings (see Fig. 1, Plate II.), and when infiltration of the epiglottis is present, it loses its form, assuming a turban-like shape. When ulceration is seen it presents a worm-eaten, carious appearance. Paralysis of one or both vocal cords is often seen, and secretion is present, which is altered, being muco-purulent in character. (See Fig. 2, Plate II.)

### **What is the prognosis ?**

The *prognosis* is unfavorable, though cures have been reported. The most that can be hoped for is to check the progress of the disease and alleviate the symptoms.

### **Give the treatment of tubercular laryngitis.**

The *treatment* should be both constitutional and local. Appropriate internal remedies, such as the hypophosphites, cod-liver oil, creasote, etc., should be administered. The food should be nourishing, bland in quality, and non-irritating. Locally, steam inhalations of creasote, pine oil, and the compound tincture of benzoin are of service. - Scarifi-

cation is recommended by some and condemned by others. The insufflation of iodoform is advocated by Schnitzler-Krause of Berlin, who also advises the use of applications of lactic acid to ulcerations situated on the posterior portion of the larynx. A 20 per cent. solution of menthol in olive oil is recommended by Rosenberg. The use of sprays has also been found useful. Cocaine in a 2 per cent. solution, applied before eating, is useful for alleviation of the pain. When deglutition becomes impossible, Delavan's alimentation-bottle may be employed. When the dyspnoea becomes extreme, tracheotomy can be performed.

### SYPHILITIC LARYNGITIS.

#### Give the etiology.

It may occur as a secondary manifestation of syphilis in from a few weeks or months to two years after the primary infection. As a tertiary manifestation it may occur in from three to thirty years after. It is said to be more frequent in men than in women.

#### Give the pathology.

In the secondary form hyperæmia may be present, complicated with ulcerations or condylomata. In the tertiary form hyperæmia is the first manifestation, followed by progressive ulceration. The cartilages may become involved, and stenosis is not of infrequent occurrence as the result of cicatricial contraction.

#### What are the symptoms?

In secondary syphilis hyperæmia with ulcerations or mucous patches is frequently observed. The voice is usually impaired, and may be completely lost, but soon returns. Difficulties of breathing are not, as a rule, present. Cough is not a prominent symptom, and is usually due to an effort to clear away the expectoration.

On inspection with the laryngoscope congestion is noticed, and more especially the ulcerations of the vocal cords. (See Fig. 3, Plate II.) When mucous patches exist, they are seen most frequently on the ventricular bands, the interarytenoid space, and the epiglottis. Condylomata are sometimes seen. The secretion is scanty.

In the tertiary form ulcerations, as a rule, begin in the epiglottis, and differ from the secondary ulcerations in that they are deep, covered with a whitish-yellow coating with elevated margins, and surrounded by an inflammatory areola. When the ulcerative process involves the cartilages, necrosis is the result. If the blood-vessels become affected, hemorrhage may ensue.

#### What is the prognosis?

In secondary stages the *prognosis* is favorable. In the tertiary stage the prognosis is also favorable if seen early, though death may result from œdema of the larynx or hemorrhage.

**What is the treatment ?**

In the secondary form internal administration of mercury is indicated. Locally, astringents of nitrate of silver and chloride of zinc are serviceable. Where there is ulceration or when condylomata are present, iodide of potassium, with or without mercury, may be given.

In the tertiary stage mercurial inunction is recommended, followed by the administration of iodide of potassium. Local applications should not be neglected. Where ulceration exists, nitrate of silver should be applied. Iodoform is also recommended. When œdema is imminent tracheotomy is necessary. Where stenosis occurs as the result of cicatrization, dilatation by means of Schoetter's tubes or those of O'Dwyer should be resorted to. Tracheotomy, however, often becomes necessary.

**NEUROSES OF THE LARYNX.****Describe, briefly, the effects of lesions of the superior and recurrent laryngeal nerves, and give some of the causes.**

When a lesion of the superior laryngeal nerve exists, there is some loss of sensation, the epiglottis can only be partially closed, the voice is hoarse and easily fatigued. Lesions of both nerves cause paralysis of the thyro-cricoid, thyro-epiglottic, and ary-epiglottic muscles in the lateral half of the larynx. Aneurism, tumors of the pharynx, or enlarged glands may cause impairment of the function of the superior laryngeal nerve. It also occurs as a sequel of diphtheria. Lesions of the recurrent laryngeal nerve are the most frequent causes of paralysis of the larynx. Aneurisms, pressure from bronchial glands, and mediastinal growths may cause impairment of the recurrent laryngeal nerve, as may also enlargement of the thyroid gland. The effects are paralysis of all the muscles supplied by this nerve.

**Mention other causes which may bring about paralysis of the laryngeal muscles.**

An inflammatory condition of the muscular substance resulting from an inflammation of the larynx, atrophy or degeneration of the muscles, and various other conditions, such as anæmia, syphilis, rheumatism, and general poisoning by means of various drugs, may be mentioned as factors in the causation of motor paralysis.

*Treatment* of these forms consists in treating any catarrhal condition of the nose, pharynx, or larynx which may exist, and in the administration of tonics and faradization.

**Give a brief account of the paralysis of abduction.**

This consists in paralysis of one or both of the posterior crico-arytenoid muscles. *Bilateral* paralysis is a serious affection, but is rare. As to its causation, cases have been reported occurring after typhoid fever, pneumonia, and erysipelas. New growths, aneurisms, by pressure upon both recurrents, may produce bilateral paralysis. The voice usually re-

mains unimpaired, but may be slightly hoarse. Respiration is seriously interfered with, being noisy during inspiration, and suffocation is liable to take place. Expiration is normal. In *unilateral* paralysis the vocal cord is seen by aid of the laryngoscope to remain in the median line. The subjective symptoms are, as a rule, slight. The voice is rough and harsh in tone. Difficulty of breathing is not so marked in this as in the bilateral form on exertion; however, dyspnoea is often experienced. Unilateral paralysis may be due to a lesion of the pneumogastric, to aneurism, enlarged bronchial glands, and hypertrophy of the thyroid gland.

In the bilateral form, to relieve the extreme dyspnoea, tracheotomy often becomes necessary. In the unilateral form, where there exists any pathological conditions, such as enlarged glands, etc., appropriate *treatment* should be given. Faradization may be tried.

### Describe paralysis of adduction.

This consists in paralysis of the lateral crico-arytenoid muscles. It may be bilateral or unilateral. The *bilateral* form is due to anæmia, and often occurs where there are great bodily weakness and hysteria.

It may occur in women suffering from amenorrhœa or dysmenorrhœa. In this condition the voice is lost and the vocal cords in phonation do not approach the median line.

*Prognosis* is favorable.

The *unilateral* paralysis may be due to chronic poisoning from lead and diphtheria: it may be the result of cerebral disease, cold, or muscular strain. It is met with after small-pox, constitutional syphilis, and in phthisis.

The *symptoms* present are loss of voice or hoarseness. With the laryngoscope the cord affected is seen to remain in the cadaveric position, and does not move.

*Prognosis* is favorable when the cause is local in its origin.

*Treatment* of both forms consists in faradization, general tonics, and the administration of strychnine.

### Describe paralysis of the sphincters or tensors.

This consists in paralysis of the thyro-arytenoidei, caused by over-exertion of the voice, improper use of the voice, or hysteria. By the laryngoscope decreased approximation is seen to exist, and the cords appear thinner than normal.


### What other forms of paralysis may exist?

Paralysis proper of the arytenoideus or as the result of catarrh.

The *prognosis* as regards life is good.

*Treatment* is the same as in the preceding forms.

FIG. 73.



Paralysis of Left Vocal Cord (Cohen).

## BENIGN TUMORS OF THE LARYNX.

**Give the etiology.**

Hyperæmia, catarrh, and the inhalation of certain irritating vapors may give rise to the formation of a new-growth in the larynx. Constant use of the voice, as also syphilis, may be mentioned as predisposing causes. These tumors occur usually in adults, and are more frequent in males than in females.

**What are the symptoms?**

The *symptoms* vary with the size, situation, and consistency of the growth. The voice is, as a rule, impaired. Double voice is said to occur in a certain proportion of cases, especially if the growth be small. Dyspnœa is only present when the growth is of so large a size that it interferes with respiration. Cough may be present, and is usually due to a desire to clear the throat. Pain, as a rule, is absent, nor is there any difficulty in swallowing unless the growth be situated on the epiglottis.

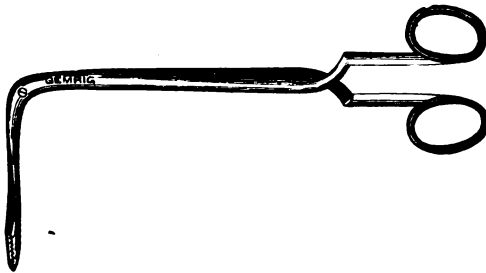
**What are the growths usually met with?**

Papillomata, fibromata, angiomata, myxomata, and cysts. (See Figs. 4 and 5, Plate II.)

**What is the treatment of benign growths in the larynx?**

They should be either destroyed by means of caustics or removed. Caustics should only be employed where the growth is of small size. Of these, nitrate of silver, chromic acid, and the galvano-cautery are the ones chiefly recommended. For their removal forceps are generally used. Mackenzie's forceps (Fig. 74) and Schroetter's are effective for

FIG. 74.



Mackenzie's Laryngeal Forceps.

this purpose. Where the growth is situated on the epiglottis, Jarvis's snare may be employed.



**MALIGNANT GROWTHS IN THE LARYNX.**

**What are the malignant growths which occur in the larynx ?**

Sarcoma and carcinoma.

**What are the symptoms ?**

Hoarseness with severe pain, difficulty in swallowing, and disturbances in respiration as the growth increases in size. When ulceration occurs, pain becomes more intense and hemorrhage may occur. The breath has a foetid odor. The laryngoscopic appearances vary. Sarcoma often resembles a papilloma or fibroma. In carcinoma when the growth is an epithelioma it has a grayish-red color; ulceration is present, surrounded by vegetations, which soon break down to become in turn ulcerated. In encephaloid cancer vegetations are seen on the surface of the ulcer. Scirrhus is hard to the touch at first, but soon becomes inflamed and ulcerates.

**What is the treatment of malignant growths of the larynx ?**

Attempts at endolaryngeal removal are recommended by some, condemned by others. Excision of the larynx, total or partial, has met with some success, as has also thyrotomy, followed by removal of the growth. Tracheotomy often prolongs the life of the patient. Cocaine, 4 per cent. solution, and insufflations of morphia, gr.  $\frac{1}{4}$ - $\frac{1}{2}$ , for the relief of pain are often useful.

**SUCCESSFUL CASES ALIVE AFTER THREE YEARS.****THYROTOMY.**

Case No.

1. Died 4 years after operation, of cerebral apoplexy.
2. Well 8 " " "
3. " 20 " "

**PARTIAL EXCISION.**

1. Well 3½ years after operation.
2. " 4 " "
3. " 4 " "
4. Died 5 " " of cerebral apoplexy.

**TOTAL EXCISION.**

1. Well 3½ years after operation.
2. " 4 " "
3. " 4 " "
4. " 4½ " "
5. Died 4½ " "
6. Well 5 " "
7. " 5½ " "
8. " 9 " "

Total, 15 cases.

DEATHS DUE TO OPERATIONS FOR INTRINSIC CARCINOMA  
(IMMEDIATE).

	Cases.	Deaths.
Thyrotomy . . . . .	28	3
Partial excision . . . . .	23	7
Total excision . . . . .	51	16
	102 operations.	26 deaths.

## CAUSES OF DEATH.

Accident . . . . .	1
Hemorrhage . . . . .	1
Paralysis of heart . . . . .	2
Exhaustion . . . . .	3
Pleurisy . . . . .	1
Pneumonia, broncho-pneumonia, pleuro-pneumonia.	6
Sepsis . . . . .	9
Not ascertained . . . . .	3
Total . . . . .	26

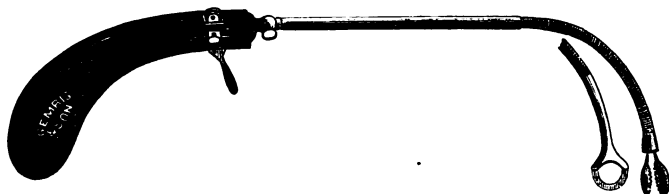
## FOREIGN BODIES IN THE LARYNX.

**What are the foreign bodies found in the larynx? Give the treatment.**

Various articles of food, such as fish-bones, pieces of meat and bread; also buttons, pins, etc. often find their way into the larynx.

The *symptoms* they give rise to are violent attacks of coughing, and when not dislodged, and the body is of large size, the face becomes livid, with protrusion of the eyeballs, and even unconsciousness may ensue. When the body is of such size as to prevent the entrance of air into the lungs, suffocation ensues, and the patient dies in a very short space of time. When the foreign body is small, the above symptoms do not show themselves, but instead fits of coughing.

FIG. 75.



Seller's Universal Tube-forceps and Guillotine.


The *treatment* consists in their removal by Mackenzie's, Seiler's, or Schroetter's forceps, cocaine having been first applied. (Fig. 6, Plate II., shows pin imbedded in posterior portion of the right cord.)

**A DIFFERENTIAL TABLE OF THE SIGNS AND SYMPTOMS OF THE PRINCIPAL LARYNGEAL DISEASES.**

	Acute Laryngitis.	Chronic Laryngitis.	Syphilitic Laryngitis.	Tubercular Laryngitis.	Perichondritis.	Benign Growths.	Malignant Growths.	Neuroses.
<b>Functional or Subjective Symptoms:</b> <b>Voice.</b>	Hoarse, becoming aphonic.	Hoarse, uncertain, easily fatigued.	<i>Secondary, Tertiary.</i> Characteristically raucons; seldom aphonic.	Some times aphonic in earlier stages; completely lost in advanced disease.	Painful, easily fatigued, but not necessarily impaired.	Very variable, from slight hoarseness to complete aphonia, even in same case.	Impaired by mechanical causes when invasion is from pharynx; may be early lost in primary disease. Only quickened on exertion; later paroxysmal dyspnoea from stenosis or compression.	Lost in bilateral paralysis of adductors; impaired in other forms of paralysis; not necessarily in spasm.
<b>Respiration.</b>	Not embarrassed prior to oedema; then stridor, dyspnoea, and even apnoea.	Seldom embarrassed.	<i>Secondary, Tertiary.</i> Increasing embarrassment according to amount of stenosis.	Early hurried; greatly embarrassed with advance of disease.	Variable, according to cartilage attacked and degree of stenosis.	Seriously embarrassed in one-sixth of cases depends on situation of the growth.	Generally quickened on exertion; later paroxysmal dyspnoea from stenosis or compression.	Only embarrassed in paralysis of adductors and in spasmodic affections.
<b>Cough.</b>	Dry, hard, shrill, metallic; aphonic; when exudation, moist.	Occasional, with slight expectoration of glutinous pellets.	<i>Secondary.</i> Slight hacking. <i>Tertiary.</i> Infrequent, with but slight expectoration.	Greatly influenced by amount of lung disease: painful. Expectoration variable.	Generally early spasmodic.	Generally limited to effort to dislodge foreign body; may be expectoration of atoms of growth.	Not necessarily present; expectoration scanty; occasionally blood and portions of neoplasm.	Paroxysmal, especially in spasmodic affections.
<b>Deglutition.</b>	Painful when oedema has taken place or from associated pharyngeal inflammation.	Rarely affected.	<i>Secondary.</i> Normal, unless mucous patches on epiglottis or arytenoids. <i>Tertiary.</i> Often difficult, very rarely painful.	Extremely difficult and painful, from early period to termination.	Varying from dysphagia to aphagia, according to pressure on gullet.	Only impaired in rare cases, in which epiglottis or aryepiglottic fold is involved.	Always difficult and painful; often the earliest symptom.	But slightly impaired, or unaffected.
<b>Pain and altered sensation.</b>	Sensation of tightness and constriction; tender to external pressure.	Painless; sense of fatigue after exercise.	Characteristic absence of pain.	Pain only experienced in functional acts.	Pain variable with cause; most severe in gouty form, but not then constant.	Characteristically absent, occasionally slight tickling or sense of irritation.	Ever present and severe, extending upward to ears.	Only experienced and sensory system is affected. Diminished sensation in motor paralysis and in anaesthesia.

Physical or Objective Symptoms: Color.	Intense, uniformly increasing, superficial pharyngitis; translucent on edema.	Partial and modified hyperemia. General color a yellowish red.	<i>Secondary.</i> Mottled, more or less symmetrical hyperemia. <i>Tertiary.</i> Hyperemia of portion attacked prior to ulceration; permanent infiltrated appearance.	Anæmia, followed by opaque grayish color; margins of ulcers hyperæmic.	<i>Hypæremia</i> generally limited to portio- tion attacked, sometimes extending to contiguous parts.	Variable with nature of neoplasm; slightly increased by increased vascularity of mucous membrane generally.	Increased local- ity, tend- ing to lividity; neoplasm is whitish-gray, pale rose, or deep red.	In paralysis of abductors oc- casional vas- cularity of vo- cal cords.
Form and texture; ulceration.	Thickening and stenosis from œdema; loss of tissue rare, except in phlegmonous form.	Occasionally slight erosion, never ulcera- tion; slight thickening, sometimes leading to narrowing.	<i>Secondary.</i> Occa- sional superficial ulceration, slight general submu- cosal infiltration. <i>Tertiary.</i> Deep, cir- cumscribed, de- structive ulcers of angry color and with yellowish base, followed by cicatricial narrow- ing and quasi-new formations. <i>Secondary.</i> Unal- tered. <i>Tertiary.</i> Deformity from intrinsic and pharyngeal cicatrices.	Solid submu- cosous thick- ening of epiglott- tis and aryte- noids; eleva- tion and ul- ceration of raceme of glands, giving worm-eaten ulcers, which combine and attack deeper tissues. No displace- ment; tenden- cy for thick- ened parts to transgress boundaries of pharynx.	Ulceration of- ten absent, substituted by encysted ab- scesses, causing narrowing, compression, and paralysis, the larynx.	Varies with sit- uation, size, and nature of growth; never ulceration. May cause narrowing of the cavity of the larynx.	May cause com- pression, nar- rowing, and nature of pa- ralysis be- fore ulcera- tion, which is always accom- panied by thickening. Extensive in- dolent gray, greenish, or almost black ulcers.	Form of glottis varies with nature of pa- ralysis, with- out extrinsic thickening.
Position of the laryngeal parts.	Unaltered.	Unaltered.	<i>Secondary.</i> Unal- tered. <i>Tertiary.</i> Deformity from intrinsic and pharyngeal cicatrices.	May be consid- erable altera- tion of supra- and infraglot- tic space.	Position of nor- mal parts sel- dom changed.	Early displace- ment, espe- cially when invasion is from phar- ynx.	Position of the paralyzed cord varies accord- ing to the form of paralysis.	Position of the paralyzed cord varies accord- ing to the form of paralysis.
Miscellaneous:	Pharynx usu- ally synchro- nously impli- cated.	Pharynx usu- ally synchro- nously impli- cated.	<i>Secondary.</i> Pharynx generally recently or concomitantly implicated. <i>Tertiary.</i> Seldom synchronous im- plication, but usually scars of previous similar pharyngeal ul- ceration, and pos- sibly adhesions of the velum.	Lungs either primarily, synchronously, or subse- quently in- volved. Gen- erally anæ- mic. Rarely ulceration of pharynx. Gen- eral emacia- tion.	Constitutional manifestations.	Glandular in- filtration, but complete im- munity of other organs of body from similar dis- ease, both prior and sub- sequent to ap- pearance in laryngo-phar- ynx. General emaciation.	Glandular in- filtration, but complete im- munity of other organs of body from case of cardiac or lymphatic system, or as- sociated cere- bral disease or appearance in chronic tox- icæmia.	Glandular in- filtration, but complete im- munity of other organs of body from case of cardiac or lymphatic system, or as- sociated cere- bral disease or appearance in chronic tox- icæmia.

Clinique for Diseases of the Throat, College of Physicians and Surgeons, New York.  
By permission of G. M. Lefferts, M. D., Professor of Throat Diseases, College of Physicians and Surgeons, New York.



# THE NOSE AND ITS DISEASES.

---

## ANATOMY OF THE NOSE.

### **Describe the external nose.**

The external nose is made up of two portions—a bony and a cartilaginous portion. It is covered externally by integument, internally by mucous membrane, and is supplied with muscles, blood-vessels, and nerves.

### **Name the bones entering into its formation.**

The bones are the two nasal bones and the nasal processes of the superior maxillary.

### **Name the cartilages.**

The cartilages are five in number: two upper, two lower lateral cartilages, and the cartilage of the septum. These are held together by means of strong connective tissue, and by the action of muscles upon them the openings of the nose can be dilated or narrowed. Besides these, are also found smaller sesamoid cartilages. These are usually imbedded in a fibrous mass.

### **Describe the integument of the external nose.**

The integument is rich in sebaceous glands, the contents of which form the well-known comedones. It extends inside the nose as far as the anterior end of the inferior turbinated bones, and at the entrances of the nares is covered, chiefly in men, with short, thick hairs.

### **Describe the mucous membrane.**

The mucous membrane is continuous with the integument externally, and with that which lines the nasal fossæ within.

### **Name the muscles of the external nose.**

The muscles are the levator alæ nasi, depressor alæ nasi, levator alæ nasi propr., and the m. apicis. These by their action dilate or make narrow the openings of the nose.

### **Give the blood-supply.**

The blood-supply is furnished by the lateralis nasi from the facial, and

the nasal artery of the septum from the superior coronary, which supplies the alæ and septum, the sides and dorsum being supplied also from the nasal branch of the ophthalmic and the infraorbital.

#### **What are the nerves ?**

The nerves are branches from the facial, infraorbital, and infratrochlear, and from the nasal branch of the ophthalmic.

#### **How are the nasal cavities formed ?**

By means of various bones which form an upper wall or roof, a lower wall or floor, and an internal and an external wall.

#### **How is the upper wall or roof formed ?**

It is formed anteriorly by both nasal bones (Fig. 76), in the middle by the ethmoidal cribriform plate, and posteriorly by the anterior wall of the sphenoidal sinus.

#### **How is the lower wall or floor formed ?**

It is formed by the palatal processes of the superior maxillary, and by the horizontal plates of the palate-bones. The floor is smooth and somewhat sloping posteriorly.

#### **How is the inner wall formed ?**

The inner wall is formed by the septum. Its osseous portion is formed by the vomer, by the vertical plate of the ethmoid, by the crista palatina and crista nasalis anter.; the cartilaginous portion is formed by the cartilago septi, which shows much variation in form.

#### **How is the external wall formed ?**

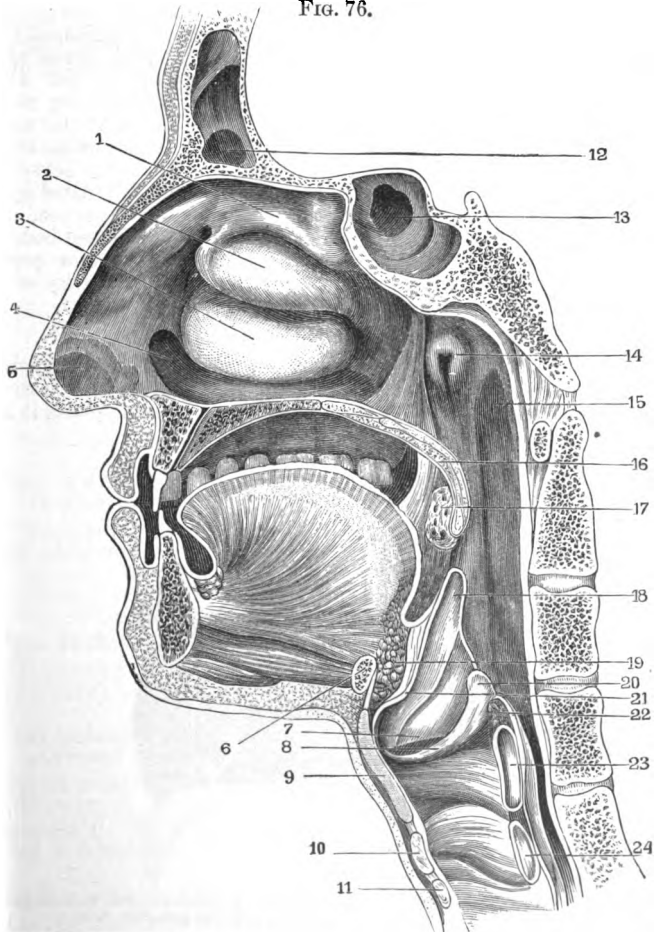
The external wall is formed by the superior maxillary, the perpendicular portion of the palate-bone, and the pterygoid process of the sphenoid.

On the external wall are seen several openings which vary in size and form. The most important of these is called the hiatus semilunaris or bulla ethmoidalis. This leads into a funnel-shaped cavity, the infundibulum. The infundibulum in its anterior and upper part stands in connection with the frontal sinus, and in its lower and posterior portion with the maxillary sinus by means of the middle meatus and ostium maxillare.

#### **What structures are found on the lateral wall ? Describe them.**

The most important structures are the turbinated bodies. These are three in number—an inferior, a middle, and a superior. The inferior turbinated lies on the inner surface of the upper jaw. It is irregularly curved, and is covered with mucous membrane. On its surface are sometimes seen depressions and grooves. The space lying between it and the floor of the nose and the septum is called the inferior turbinated space or meatus. Under the roof of this space—viz. the inferior turbinated body—is situated outwardly and anteriorly a small opening, the excretory opening of the tear-duct. The middle turbinated is a portion of the

FIG. 76.



Vertical Section of Head, slightly diagrammatic: 1, superior turbinated bone; 2, middle turbinated bone; 3, lower turbinated bone; 4, floor of nasal cavity; 5, vestibule; 6, section of hyoid bone; 7, ventricular band; 8, vocal cord; 9 and 23, section of thyroid cartilage; 10 and 24, section of cricoid cartilage; 11, section of first tracheal ring; 12, frontal sinus; 13, sphenoidal cells; 14, pharyngeal opening of Eustachian tube; 15, Rosenmüller's groove; 16, velum palati; 17, tonsil; 18, epiglottis; 19, adipose tissue behind tongue; 20, arytenoid cartilage; 21, tubercle of epiglottis; 22, section of arytenoid muscle (Seiler).

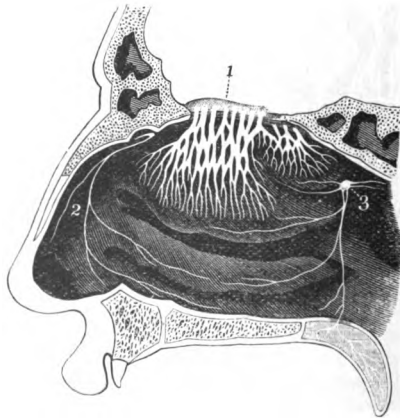


ethmoid, and is situated higher and farther back than the inferior turbinated. The space lying between it and the inferior turbinated body is called the middle turbinated space or meatus. The narrow space lying between it and the septum is called the rima olfactoria, which contains in its mucous membrane the endings of the olfactory nerve. In the middle turbinated space are situated the openings of the maxillary and frontal sinuses. The superior turbinated, also a portion of the ethmoid, is the smallest of the turbinated bones. The space between it and the middle turbinated is known as the superior turbinated space. The several openings of the ethmoidal cells are seen in this space. Between the posterior ends of the middle and superior turbinated bodies is situated the foramen sphenopalatinum. Above the posterior portion of the superior turbinated is seen the entrance into the cavity of the sphenoid.

**Describe the mucous membrane of the nasal cavity.**

The mucous membrane is continuous anteriorly with the integument and posteriorly with the mucous membrane of the pharynx. It covers the septum, the turbinated bodies, and sinuses. In some places it is so

FIG. 77.



Distribution of Nerves in the Nasal Passages (Dalton): 1, olfactory bulb, with its nerves; 2, nasal branch of the fifth pair; 3, sphenopalatine ganglion (Seiler).

intimately connected with the periosteum that it is difficult to separate them. The mucous membrane in the upper portion, the regio olfactoria, has columnar epithelium. The lower portion, the regio respiratoria, has ciliated and columnar epithelium. It is rich in nerves, blood-vessels, and glands.

**Name the nerves of the nasal cavity.**

The nerves are divided into three sets: the nerves of sensibility, nerves of secretion, and the nerve of smell (Fig. 77). The nerves of sensibility arise chiefly from the first and second branches of the trigeminus. The secretory nerves arise from the sphenopalatine ganglion. The nerve of smell is the olfactory nerve.

**Name the arteries of the nasal cavity.**

The arteries are the anterior and posterior ethmoidal, from the ophthalmic, which supply the ethmoidal cells, frontal sinuses, and roof of the nose; the sphenopalatine, from the internal maxillary, which supplies the mucous membrane covering the turbinated bones, the meatuses, and the septum; and the alveolar branch of the internal maxillary, which supplies the lining membrane of the antrum.

**What are the veins?**

The veins accompany the arteries, and communicate with the facial and ophthalmic veins. One of these passes through the plate of the ethmoid and the foramen cæcum into the longitudinal sinus.

**What are the physiological functions of the nose as an organ of respiration?**

The inspired air is freed to some extent from dust, there is a certain proportion of moisture added to it, and it is also made warmer.

**RHINOSCOPY.****What is rhinoscopy?**

Rhinoscopy is the examination of the nasal cavities, and is divided into anterior and posterior rhinoscopy.

**What instruments are necessary for an examination of the nasal cavities?**

(1) A nasal speculum. Various specula have been recommended; those chiefly in use are Fränkel's, Duplay's, Charrière's, Kramer's, and Bosworth's. (2) A head mirror. (3) Tongue-depressor (Türck). (4) A small rhinoscopic mirror.

**What is seen on an examination of the anterior nares?**

On the inner side is seen the septum, which is red in color and which may be straight or deviated. On the outer side is seen a rod-like prominence, which is the inferior turbinated body. Between this, the floor of the nose, and the septum is a space, the inferior turbinated space. Above the inferior turbinated is seen the middle turbinated space. Then comes into view the middle turbinated, with the rima olfactoria lying between it and the septum. Sometimes the superior turbinated can be

seen through the rima olfactoria. The head, of course, must be tilted in different directions to bring into view the various structures.

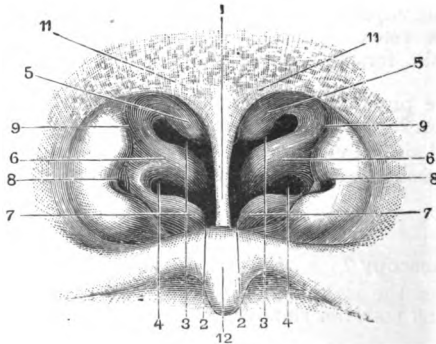
### How is a posterior rhinoscopic examination made?

The tongue-depressor, held in the left hand, is introduced into the mouth and placed upon the dorsum of the tongue, depressing it as gently as possible. The small rhinoscopic mirror is then heated, and introduced with its reflecting surface upward, beneath and beyond the soft palate. If there be no obstacles present, a view of the posterior nares is then obtained.

### What is seen in a posterior rhinoscopic examination?

The parts visible are the posterior margins of the turbinated bodies (Fig. 78), the septum, the orifices of the Eustachian tubes, the grooves of

FIG. 78.



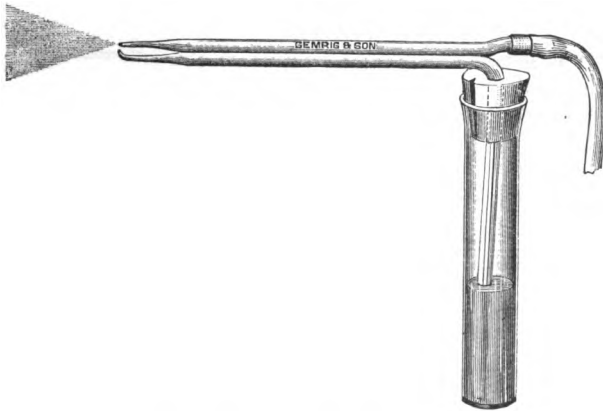
Rhinoscopic Image: 1, vomer or nasal septum; 2, floor of nose; 3, superior meatus; 4, middle meatus; 5, superior turbinated bone; 6, middle turbinated bone; 7, inferior turbinated bone; 8, pharyngeal orifice of Eustachian tube; 9, upper portion of Rosenmüller's groove; 11, glandular tissue at the anterior portion of vault of pharynx; 12, posterior surface of velum (Seiler).

Rosenmüller, the Eustachian prominences, and the vault of the pharynx, on which is seen Luschka's tonsil.

### What are the obstacles which prevent an examination of the posterior nares? How are they overcome?

An irritable throat or irritability of the fauces. The palate often contracts on introduction of the mirror. To overcome this the patient should be directed to breathe quietly through his nose. The irritability of the parts may be overcome by brushing or spraying them with a 10 per cent. solution of cocaine.

FIG. 79.

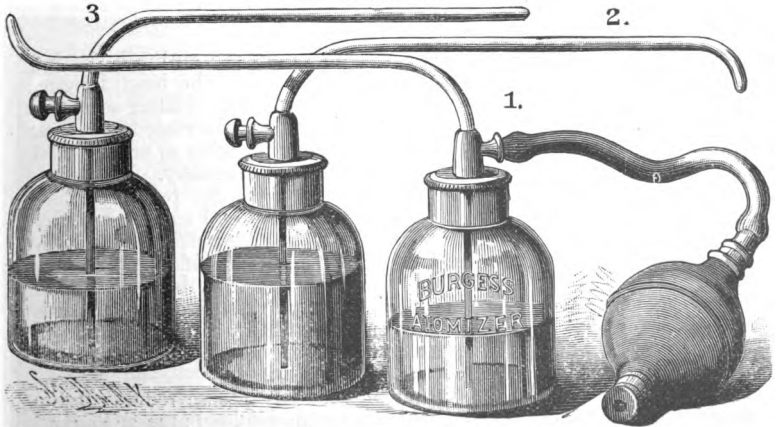


Sass's Atomizing Tubes.

**What other instruments are necessary for examination and treatment?**

A sound made of silver to detect the consistency of the parts, as well as new growths and foreign bodies; a cotton-applicator for the appli-

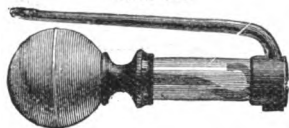
FIG. 80.



The Burgess Atomizer.

cation of the various solutions used in the treatment of nasal diseases; a brush for application to the posterior nares and vault of the pharynx; atomizer, of which there are a number in use, for the application of medicaments in the form of spray: a hand-atomizer can be used or the condensed-spray apparatus; powder-insufflators for the insufflation of powders. (Figs. 79 and 80 show forms of atomizers, while Fig. 81 shows a powder-insufflator.)

FIG. 81.



Reservoir Insufflator.

## INFLAMMATIONS OF THE NOSE.

### What is acute rhinitis?

It is an acute inflammation of the nasal mucous membrane.

### What are the other names usually applied to it?

Cold in the head, acute nasal catarrh, and coryza.

### What is the etiology of acute rhinitis?

Exposure to cold, sudden changes of temperature, inhalation of dust and irritating vapors, such as the vapors of ammonia, chlorine, iodine, hydrochloric acid, etc. It often occurs in iodism, and is sometimes the result of sexual irritation. It is a constant complication of measles, and is often seen with scarlet fever, small-pox, and typhus. In some persons there is a predisposition to repeated attacks of acute rhinitis.

### What are the symptoms of acute rhinitis?

There may be prodromal *symptoms* preceding the outbreak, lasting several hours or days, such as a sense of fulness in the head, fatigue, and an indisposition to work. These are followed by a tickling sensation in the nose, sneezing, violent frontal headache, and increased secretion. These symptoms increase rapidly, the secretion becoming so profuse that the patient is forced to use his handkerchief continuously. The secretion is at first thin, watery, and irritating, owing to the presence of sodium chloride and ammonia. The senses of taste and smell are diminished or completely lost, respiration through the nose is difficult or wholly impossible, and the voice assumes a nasal tone. The inflammation may spread to the conjunctiva through the tear-duct, or to the ear through the Eustachian tubes. The discharge after two to three days becomes thicker, gelatinous, and muco-purulent, and finally becomes normal in character again. The obstruction in the nose gradually disappears and the senses of taste and smell return.

The objective changes consist in more or less intense redness of the mucous membrane and swelling, which is chiefly diffuse, but more marked on the anterior and posterior margins of the inferior turbinated body.

Erosions are sometimes seen. Besides these changes, the skin of the nose may appear red, shining, and swollen. The skin of the upper lip and entrance of the nares is often eroded, sometimes covered with an eczema or herpetic vesicles. Where there is complete obstruction of the nose the tongue is dry and fissured. The secretion contains innumerable desquamated cylindrical and ciliated epithelial cells, white blood-corpuscles, and mucous cells. Occasionally red blood, blood-corpuscles, and bacteria are found.

#### **What is the course of the disease?**

The *course* of the disease is from three to eight days; in severe cases it may last fourteen days or even longer. The disease may become chronic or result in the development of polypi.

The *complications* that may arise are inflammations of the neighboring cavities, chiefly the frontal sinus; occasionally empyema of these cavities may occur.

#### **Give the diagnosis.**

The *diagnosis* is, as a rule, easy, except where the prodromal symptoms are so violent as to make one suspicious of a more serious affection—*e. g.* acute exanthemata.

#### **What is the prognosis?**

The *prognosis* is favorable. A fatal termination is seen only in the aged or in very young children.

#### **What is the treatment of acute rhinitis?**

The *treatment* must be both prophylactic and abortive. In those predisposed to this affection an avoidance of the causes that lead to it is necessary. Those who work among chemicals must protect the mucous membrane by means of cotton tampons. Where it occurs as a symptom of iodism the administration of the iodide should at once be discontinued. To abort the disease many remedies have been recommended. A Dover's powder at bedtime, followed by a laxative in the morning, is useful. Hot foot-baths, diaphoretics, the Turkish bath, are all beneficial. The use of menthol in the form of spray is said to abort an acute coryza. It may be used in the following form:

R. Menthol, gr. xv;  
Fl. albaline, ℥j.—M.

Sig. To be used in the Kesson-Robbins albaline atomizer.

The application of cocaine in a 3 per cent. to 10 per cent. solution is often effective, and relieves the very troublesome symptom of obstruction. Steam inhalations of tinct. benz. co., oil of tar, and eucalyptus often give relief.

**What is purulent nasal catarrh ?**

An acute inflammation in which the secretion is from the beginning purulent in character.

**What are the causes ?**

The *causes* are specific and infectious in their nature. Infection of the nose with the secretion of gonorrhœa by means of the fingers or handkerchief is a frequent cause. It occurs in new-born infants. It also occurs in the course of acute infectious diseases, chiefly measles, scarlet fever, diphtheria, variola, or as the result of the spreading of a purulent catarrh of the conjunctiva.

**What are the symptoms ?**

From the beginning of the disease the secretion is purulent in character, and is fœtid, cheesy-like, and may be tinged with blood. The skin covering the upper lip and entrances to the nostrils may be excoriated. The mucous membrane is swollen, reddened, and covered with superficial ulcers.

**What is the diagnosis ?**

The *diagnosis* rests upon determining one of the above causes. It may be confounded with diphtheria, syphilitic catarrh, and the catarrh produced by irritation from a foreign body.

**What is the prognosis ?**

The *prognosis* is favorable; only in infants is it serious. Various complications, such as purulent inflammation of the neighboring cavities, erysipelas of the face, etc., may arise.

**What is the treatment of purulent nasal catarrh ?**

The most essential point in the *treatment* is the cleansing of the nose by means of the nasal douche. The disinfectants recommended are boric acid, carbolic acid, and resorcin, and insufflations of nitrate of silver, alum, iodoform, etc. In children and infants, where the use of the nasal douche is impossible and dangerous, the cleansing of the nose by means of a small tampon has been recommended.

**What is simple chronic rhinitis ?**

It is a chronic inflammation of the nasal mucous membrane.

**What is the etiology ?**

Repeated attacks of acute catarrh and the acute catarrh following acute infectious diseases are the most common causes. Those inhaling various organic and inorganic vapors frequently suffer from chronic catarrh. Heredity is said to have influence in giving rise to it. It sometimes appears as the result of adenoid vegetations and enlarged tonsils. Sexual excitement, pregnancy, menstruation, a gouty or rheumatic diathesis, predispose to it.

**What are the pathological changes?**

The *pathological changes* are slight. The chief condition present is an engorgement of the erectile bodies. The mucous membrane is but slightly swollen. The epithelial layer appears to undergo no change. In the submucous tissues is seen a small amount of cellular infiltration.

**What are the symptoms?**

There is an increased irritability of the nasal mucous membrane, as shown by a feeling of stiffness in one or both nostrils. This is especially seen in a change of atmospheric conditions and when the patient assumes a recumbent posture. The patient has repeated attacks of sneezing, and is constantly catching cold. There is dilatation, which is recognizable on inspection by a puffy condition of the turbinated bodies. This condition is distinguished from true hypertrophy by making use of the probe, when the swelling is seen to collapse. On the application of cold or cocaine the same change takes place. The secretion varies as to quantity and quality. At first it is thin, but gradually becomes thicker. It may be profuse or scanty as to quantity. The color is dirty white, yellowish, or greenish. It is often seen dried in crusts at the nasal septum and on the anterior ends of the turbinated bodies. If examined by the microscope, the secretion is seen to contain leucocytes, some blood-cells, degenerated epithelium, and micrococci of various kinds.

**What are the rhinoscopic appearances?**

The rhinoscopic appearances show a reddening of the mucous membrane, which may be diffused or localized; swelling, which is present in varying degrees, and a secretion showing a variation in character and quantity. Slight erosions are also sometimes seen.

**What are the complications?**

Chronic catarrh of the naso-pharyngeal space, with or without hypertrophy of Luschka's tonsil, is a frequent *complication*. Hypertrophy of the tonsils, granular pharyngitis, inflammation of the neighboring cavities of the Eustachian tubes and of the middle ear, are often found in connection with chronic rhinitis. Frequent sequels are the development of myxomatous and fibrous growths.

**What is the prognosis?**

The *prognosis* of simple chronic rhinitis is, as a rule, good.

**What is the treatment of simple chronic rhinitis?**

If there be any diatheses present, such as the gouty, rheumatic, or tuberculous, these should receive *treatment*. The general health should receive attention. Hygienic treatment, such as the care of the skin and the use of proper clothing, should not be neglected. The first step in the local treatment consists in a thorough cleansing of the parts by



means of a solution, such as Dobell's, or the use of Seiler's tablets. The formula of Dobell's is as follows:

R. Acid. carbol.,	gr. iv;
Sod. bicarb.,	
Sod. bibor.,	$\bar{a}\bar{a}$ . gr. viij;
Glycerin.,	$\bar{z}\bar{j}$ ;
Aquæ,	q. s. ad $\bar{z}\bar{i}\bar{v}$ .—M.

After the cleansing of the parts the remedy selected should then be applied. This can be done by means of a spray when used in solution, by means of an insufflator when the powder is used, or by means of a cotton probe dipped in a solution and applied to the parts. The remedies recommended are insufflations of nitrate of silver, solutions of iodide or sulphate of zinc, and sulphocarbolate of zinc, gr. v to  $\bar{z}\bar{j}$ . The following prescription has been recommended:

R. Iodini cryst.,	gr. iv;
Potass. iodid.,	gr. x;
Zinci iodid.,	gr. xx;
Zinci carbolat.,	gr. xx;
Listerine,	$\bar{z}\bar{j}$ ;
Aquæ,	ad $\bar{z}\bar{i}\bar{v}$ .—M.

Sig. To be used in the form of spray.

The following can be applied by means of the cotton-applicator:

R. Iodini,	gr. viij;
Potass. iodid.,	gr. xxxviij;
Glycerinæ,	$\bar{f}\bar{z}\bar{v}\bar{j}\bar{s}\bar{s}$ .—M.

To prevent irritation after the above application a spray of cosmoline or albaline is effective.

### What is chronic hypertrophic rhinitis?

It is a chronic hypertrophic inflammation of the nasal mucous membrane.

### What is the etiology?

It is usually the sequel of a long-continued chronic rhinitis, or occurs as the result of repeated attacks of acute rhinitis.

### What is the pathology?

There is an increase in the epithelial cells, with desquamation and sometimes fatty degeneration. The mucosa becomes covered with young epithelial cells, and there is formation of connective tissue. According to Sajous, the walls of the venous sinuses become thickened, owing to

the formation of connective tissue. New blood-vessels are also formed, whilst the glands and their openings are filled with proliferating cells. There is a secretion, which may be watery or thick. It contains mucin and is muco-purulent. It dries easily, and forms crusts on the walls of the nasal cavities.

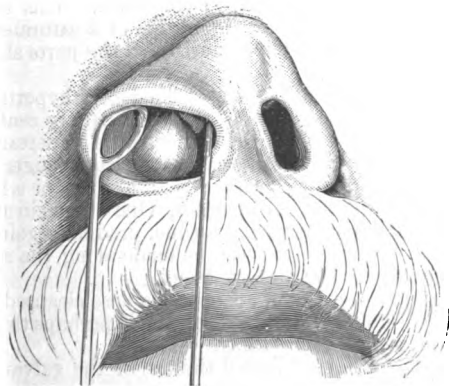
#### What are the symptoms?

The chief *symptom* is obstruction to the nasal respiration. This may be temporary or permanent. If it persist, the face assumes the peculiar expression characteristic of mouth-breathers. As a result, the tongue becomes dry and coated. The sense of smell is diminished, and there may be complete anosmia. The voice assumes a nasal twang. Sleep is often restless. Disturbances in hearing are present, and can vary from simple buzzing to severe inflammation of the middle ear. There is an increase of secretion. Mucus often accumulates in the post-nasal cavity during the night and drops into the throat. This gives rise to a choking sensation, cough, and may even induce vomiting. As a result, the pharynx becomes affected. Epistaxis is often present. Besides these, the patient often experiences a sensation of pressure in the frontal region, and feels indisposed to work, and often has a sensation of itching and burning in the nose.

#### What are the rhinoscopic appearances?

Anteriorly, the membrane appears normal in some cases, in other cases

FIG. 82.



Dilated Nostril, showing anterior hypertrophy (Seiler).

red (Fig. 82). The inferior turbinate is seen swollen, and often lying against the septum. Ulcerations are sometimes seen. Posteriorly,

there is swelling of the posterior ends of the middle and inferior turbinated. This is especially noticeable in the lower turbinated. The swelling may be very red or whitish, or may present an appearance which by some has been called mulberry-like, and by others raspberry-like.

### **What is the diagnosis?**

The *diagnosis* is as a rule easy. It is distinguished from the simple form by the use of the probe and cocaine, as has already been described.

### **What is the prognosis?**

The *prognosis* is, as a rule, good. The patient can always be relieved of his chief and most troublesome symptoms—namely, those due to obstruction.

### **What is the treatment of chronic hypertrophic rhinitis?**

The *treatment* consists in the reduction of the hypertrophied tissue. This is effected by means of acids, the galvano-cautery, or the snare.

The acids used are usually the nitric and chromic. In the use of nitric acid great care should be observed, as it is very powerful and destructive in its action. It is best applied by means of a cotton-applicator. Only a small surface should be cauterized at a time, and after its application a saturated solution of bicarbonate of soda should be used to neutralize the action and to relieve the pain.

Chromic acid is less dangerous than nitric, and is the acid most commonly used. In using it a crystal is slightly heated on the end of a probe and applied to the surface to be cauterized. This is followed, as in the case with nitric acid, by an application of a saturated solution of bicarbonate of soda. Before the cauterization the parts should be thoroughly cleansed.

The galvano-cautery is another means for reducing hypertrophied tissue in the nose. Cocaine in a solution of from 4 to 10 per cent. should first be applied. The temperature of the cautery is an important point to be looked after. The condition of cherry heat is least dangerous and least painful. A small amount of surface can be cauterized, or a large amount, according to the judgment of the operator. One can begin at the anterior end, cauterizing but a small space at a time, gradually going backward, or several parallel linear incisions can be made along the surface of the turbinated, beginning at the posterior end.

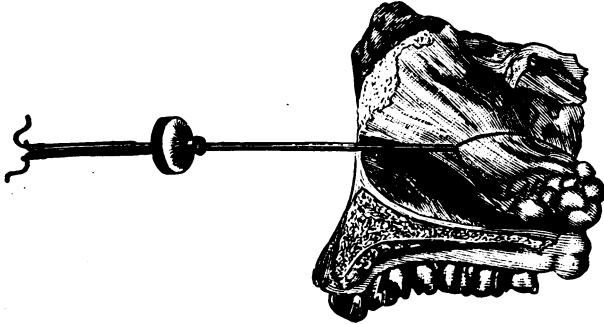
The after-treatment consists in keeping the nose cleansed by antiseptic alkaline solutions. For this purpose Dobell's is perhaps the most useful. In a few days the slough comes away.

Serious after-effects have followed the use of the galvano-cautery, so that its application should be limited to anterior hypertrophy only, and a small surface cauterized at a time.

Posterior hypertrophies are best removed by means of the snare. Jarvis's snare is the one generally in use (Fig. 83). The wire used should be steel piano-wire. The nostril being dilated by the speculum, the wire is

introduced along the floor of the nose into the naso-pharynx. The patient's tongue is then depressed, and by means of a small rhinoscopic mirror the wire is adjusted to the mass. The use of the rhinoscope, however, is

FIG. 83.



Jarvis's Snare in Position, showing loop around a posterior hypertrophy (Jarvis).

unnecessary, and in a large number of cases posterior rhinoscopy is impossible. In making use of the snare without the aid of the rhinoscope the operator gently passes the wire along the inferior turbinated space, keeping as close as possible to the septum and the floor of the nose, until the wire impinges against the posterior pharyngeal wall. It is then gently withdrawn a little, and the handle turned inward, when the loop is brought over the hypertrophy. The mass is then divided. By means of the screw on the handle the growth can be removed quickly or slowly at the will of the operator. The after-treatment consists in the application of a disinfectant spray.

The after-effects of the operation are not serious. Hemorrhage rarely occurs if the growth is slowly removed. Secondary hemorrhage may set in, but is easily controlled. Rapid relief is afforded the patient by the operation.

### What is the etiology of atrophic rhinitis?

As to the real cause of atrophic rhinitis there appears to be some doubt. The majority of observers regard it as a later stage of the hypertrophic condition. The weight of evidence seems to be against the theory that rhinitis is ever atrophic from the beginning. Predisposition to it is more strong in those with a tuberculous taint. It occurs chiefly in young persons from the tenth to the twentieth year, especially at the age of puberty, and attacks females more than males. Abnormal patency of the anterior nares has been ascribed as an exciting cause.

**What is the pathology ?**

There is formation of fibrous connective tissue, with atrophy of the various layers of the mucous membrane. The surface of the mucous membrane may be deprived of its epithelium or covered with another layer of cells. The glands disappear entirely, owing to the pressure upon them of the newly-formed fibrous connective tissue, or they may be surrounded by an infiltration consisting of round cells. The adventitia of the blood-vessels is thickened while as yet no appreciable change has been discovered in the nerve-elements. The atrophy may affect the periosteum and the bones themselves. In this case there is gradual atrophy of the lacunæ. Ulceration does not occur in atrophic rhinitis.

**What are the symptoms ?**

In making a rhinoscopic examination the nasal cavities are found to be unusually widened, so that the posterior pharyngeal wall is plainly visible. The mucous membrane is seen covered in different portions with crusts of mucus, which in color are yellow or brown, or even black. Again, one side of the nose may be found in an atrophic condition, whilst the other is seen to be in a hypertrophic state. There is a very strong odor present in a large number of cases, which is peculiarly characteristic of this condition, and which has given rise to the term "ozæna."

The subjective *symptoms* consist in disturbances of smell. The sense of smell may be considerably diminished or entirely lost. Headache, difficulty of hearing, noises in the ear, are other symptoms which may be present in a more or less marked degree. The voice has a nasal twang, and where the secretion accumulates in the nose obstruction is present.

**What is the diagnosis ?**

The *diagnosis* is, as a rule, easy. The odor must be distinguished from that occurring as the result of caries or necrosis. An exclusion of those diseases giving rise to ozæna must be made.

**What is the prognosis ?**

The *prognosis* as regards an absolute cure is bad ; as regards an amelioration of the symptoms, it is favorable.

**What is the treatment of atrophic rhinitis ?**

The most important point in the *treatment* consists in the removal of crusts and the prevention of their formation by keeping the nose constantly cleansed. For this purpose an alkaline solution should be used. Dobell's serves the purpose as well as any. If there be a very strong odor, listerine can be added. Leffert's spray-producer can be used in applying Dobell's solution, or the following formula may be used :

R. Thymol, gr. j;  
 Alcohol, flʒj;  
 Glycerin., flʒij;  
 Aq., ad flʒj.—M.  
 Sig. Use as a spray.

The following formula, recommended by Sajous, can be used in the nasal douche for the purpose of cleansing:

R. Sodii borat.,  
 Ammon. chlor., āā. gr. xx;  
 Potass. permangan., gr. x.—M.  
 Sig. To be dissolved in one pint of water at 100° F.

A solution of bichloride of mercury, in the strength of 1 : 4000, may also be used. The use of the post-nasal syringe is a useful adjunct in helping to cleanse the nostril. In using it the nozzle of the syringe is introduced behind the soft palate; the patient is directed to hold his head forward and the instrument discharged. The application of powders after cleansing the nostrils is advocated by many. Nitrate of silver in the following strength is useful:

R. Argent. nit., gr. ij;  
 Pulv. amyli, ʒss.

This can be gradually increased in strength up to ten grains.

The following powders have also been recommended: Sanguinaria, ʒij-ʒj; galanga, ʒss-ʒss; salicylic acid, gr. xx-ʒss; iodine, gr. j-ij-ʒss.

Ointments are also of service in the treatment of atrophic rhinitis. They can be applied by means of the cotton-applicator. The following are beneficial:

R. Iodol., gr. xv-xxv;  
 Ung. aq. rosæ, ʒj.—M.  
 R. Iodoformi, gr. xij;  
 Acid. carbol. cryst., gr. v;  
 Iodi, gr. ij;  
 Petrolati, ʒj.—M.

Medicated bougies and medicated cotton wools, as used by Voakes, have been found serviceable by some. Tampons of cotton, as recommended by Gottstein, are very useful. The tampon can be left in for several hours, and then replaced by a fresh one. Galvano-cautery is used by some, but is required to be used very cautiously.

Besides the local treatment, constitutional treatment should also re-

ceive attention. Tonics of cod-liver oil, iron, quinine, strychnine, should be given. Hygienic surroundings should receive attention; proper exercise, ventilation, and the care of the skin. The diet should be regulated.

**What are the synonyms of hyperæsthetic rhinitis?**

Coryza vaso-motoria periodica, Hay fever, Hay asthma, Autumnal catarrh, Rose cold, June cold, etc.

**What is the etiology?**

Three factors are necessary to excite an attack of hay fever. These are, first, the presence of an exciting agent; secondly, a predisposition on the part of the system to become influenced by such an agent; and thirdly, a sensitive area in the nose.

**What are the symptoms?**

The *symptoms* are usually those of an acute coryza somewhat intensified, such as itching in the nose, followed by sneezing; headache and a profuse watery discharge, which is irritative in character. Nasal obstruction is present. Excessive lachrymation, often followed by conjunctivitis, is a prominent symptom. The patient not infrequently complains of sore throat; asthma often complicates the attack.

**What is the treatment of hyperæsthetic rhinitis?**

Tonics, especially the nerve-tonics, such as nux vomica, phosphorus, etc., should be administered internally. Quinine is often of great service. The application of ointments, such as the benzoated oxide-of-zinc ointment and vaseline equal parts, or the belladonna ointment, often curtails an attack. Menthol inhalations have proved serviceable. The application of cocaine in a 4 per cent. solution is recommended. Where there is hypertrophy or polypi in the nose, these should be removed. Sensitive areas should be sought for in the nose by means of the probe, and carefully cauterized by means of the galvano-cautery, chromic acid, or glacial acetic acid.

## NASAL MANIFESTATIONS OF CERTAIN CONSTITUTIONAL DISEASES.

### SYPHILIS OF THE NOSE.

**What is the etiology?**

It is here, as elsewhere, the result of syphilitic infection. It may manifest itself in the primary, secondary, or tertiary form. The primary stage is rare, and is usually caused by infected fingers or instruments. The secondary and tertiary forms are more common, and hereditary syphilis is not of infrequent occurrence.

### What are the symptoms?

The *subjective symptoms* are those usually present in catarrh, such as a sense of obstruction, disturbances of smell, nasal resonance of the voice, and increased secretion. The secretion may be watery, mucous, purulent, or cheesy in character, and has a characteristic bad odor. The odor is usually recognizable by the patient himself. Pain of a neuralgic character, extending over the face through the forehead, teeth, etc., is generally present. When occurring in the new-born, the secretion is purulent in character, mixed with blood, and has a foul-smelling odor. Besides, there is a noticeable obstruction in the breathing. The skin of the upper lip and entrances to the nares may be excoriated. Syphilis in the adult, occurring in the later stages, attacks the septum most frequently. The cartilaginous as well as the osseous portion is affected. In the cartilaginous portion there is first infiltration; this is followed by ulceration and perforation, which may be so extensive as to lead to destruction of the entire cartilage. The osseous portion may be similarly affected, destruction of the bone taking place, and as a result the nose assumes a characteristic shape which has been described as the saddle-shaped nose. Next in point of attack come the turbinated bodies, and of these the lower one is that most frequently affected. Here there is ulceration of the mucous membrane, followed by its complete destruction, so that the bone itself is seen entirely denuded. The process may involve the bone.

The floor of the nose is often the seat of the later stages of syphilis. Infiltration, ulceration, and perforation follow each other, till finally there exists a communication between the oral and nasal cavities. When the *alæ* of the nose are affected, there is induration, followed by ulceration and cicatrization. Occasionally the skin of the nose is affected, when it shows itself in the form of small red nodules.

### What is the diagnosis?

The *diagnosis* of the primary form is, as a rule, easy, provided other symptoms of syphilis are present. In the stage of gummatous infiltration, where ulceration is not present, it may present some difficulty. Lupus affecting the interior of the nose may be confounded with it. In the later course of the disease, where there are ulceration and perforation of the septum, the diagnosis of syphilis can be made.

### What is the prognosis?

In beginning cases, provided a diagnosis is made, the *prognosis* is favorable. In infants and young children a fatal termination sometimes occurs. In the later stages, where there is extensive destruction of the cartilages and bones, the prognosis is not so favorable. Where the sphenoid bone and the lamina cribrosa become affected, prognosis is serious.

Where a cure results, there often remain unpleasant sequels, such as atrophic rhinitis.



**What is the treatment of nasal syphilis?**

The *treatment* must be both general and local. In the early stages mercury should be administered. It can be given in solution by inunction or by injection. In the later stages iodide of potassium should be given. It may be combined with the mercury.

The local treatment consists in the thorough cleansing of the nose two or three times a day by means of the nasal douche or spray. Dobell's solution may be used or a solution of boric acid or permanganate of potassium. Where the crusts adhere so that the spray or douche does not remove them, they must be removed by means of the forceps. Ulcerations should be cauterized by the solid nitrate-of-silver stick or chloride of zinc. Insufflations of iodoform or iodol can be made. Some recommend the scraping of the ulcerations by means of a sharp spoon. Abscesses should be opened and all necrosed pieces of bone removed. Where there is destruction of the external nose, plastic operations or the wearing of artificial noses can be resorted to.

**TUBERCULOSIS OF THE NOSE.****Give a brief description of miliary tuberculosis of the nose, with its pathology, course, and treatment.**

Tuberculosis of the nose is rare, and usually occurs as a secondary affection. It appears in the form of swellings of various sizes or ulcerations. These swellings usually present the form of miliary nodules. After a time the surface of these nodules ulcerate, and there is a breaking down. Microscopically, they are seen to consist of lymph-cells joined together by means of connective tissue. Epithelioid and giant cells are also present. The septum is the most frequent seat of this affection.

The *symptoms* are those of a chronic catarrh with a foetid bloody secretion.

The *diagnosis* is made upon the presence of the above-described swellings and ulcerations and of other phthisical symptoms. Microscopical examination of the nodules aids in a diagnosis.

The *prognosis* is unfavorable.

The *treatment* must be both general and local. The general treatment consists in nourishment of the patient and the administration of tonics. The local treatment consists in the removal of swellings with the snare or their destruction by means of the galvano-cautery; in the cauterization of ulcerations by means of nitrate of silver or chlorate of zinc; in cleansing of the nose; and in insufflation of iodoform.

**SCROFULA.****Describe briefly scrofulous affections of the nose.**

There is often seen in children who have scrofula an acute or chronic rhinitis, which, etiologically, is a part of the disease itself. Some look upon it as tuberculosis. In scrofulous catarrh of the nose there are red-

dening and swelling of the mucous membrane, with a rich purulent secretion. Obstruction may be present, and is usually due to dried-up crusts at the entrance to the anterior nares. The external nose may be reddened and swollen. An atrophic condition may be present. Ulcerations of the mucous membrane are rarely seen.

The *diagnosis* is at times difficult, and is to be distinguished from syphilitic rhinitis. Besides the condition of the nose, the other symptoms of scrofula help in making a diagnosis.

The *prognosis* is doubtful.

### What is the treatment?

The *treatment* is constitutional and local. The former consists in the administration of cod-liver oil, iron, etc. When possible a residence in the country is often beneficial. The local treatment is the same as in other forms of catarrh.

## LUPUS.

### Describe lupus of the nose.

Lupus especially attacks the external nose, and then extends to the mucous membrane. It attacks, as a rule, the alæ of the nose first, gradually involving the bridge and root of the nose. In a case of lupus the nose appears hard and thickened, and is covered with nodules, which are single or multiple and in color are dark or reddish brown. They may be partially ulcerated, and in some places covered with crusts. The alæ of the nose gradually become destroyed and shrink up into a cicatrized mass. In the interior of the nose the cartilaginous portion is usually affected. Here are seen nodules varying in size, which ulcerate and may cause perforation of the septum.

The *diagnosis* is sometimes difficult. One is apt to mistake the disease for ulcerating gummata or tuberculous swellings. The age and tuberculous condition of a given case may render the diagnosis less difficult. The microscopical examination leaves no room for doubt.

*Prognosis* is doubtful.

The *treatment* consists in destruction of the affected portions by means of the galvano-cautery, lactic acid, chloride of zinc, or the curette. The internal treatment is by cod-liver oil, iron, etc.

## BENIGN TUMORS OF THE NOSE—POLYPI.

### How many varieties of polypi are there?

Two—the mucous and the fibrous.

### What is the etiology?

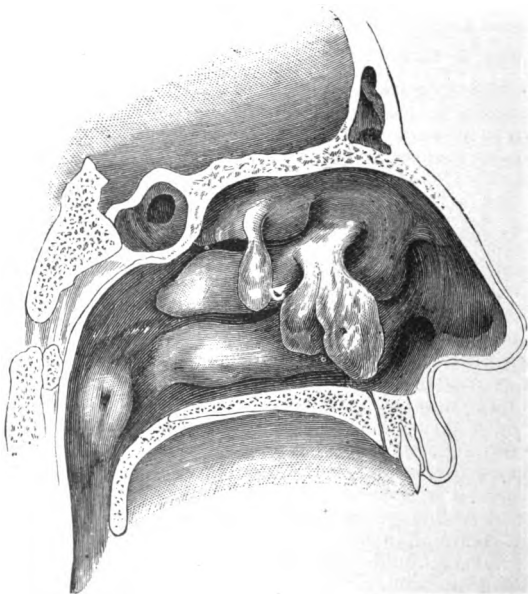
Chronic inflammation of the nasal mucous membrane is generally supposed to be the most frequent *cause* of polypi. The male sex seems to

be especially predisposed, and, as a rule, polypi are never seen until after the fifteenth year of life (Fig. 84).

**Give the pathology.**

The form of polyp most frequently observed is the mucous polyp. The angle of the middle turbinated body, the external wall of the nose,

FIG. 84.



Vertical Section through Nasal Cavity, showing nasal polypi (Seller).

the middle turbinated space, and the roof of the nose are, as a rule, the seats of their origin. In the beginning they have a bullet-like shape; as they grow larger they assume the shape of the space in which they grow. They vary in size. In consistency they are soft and elastic. In color they are whitish, grayish, and reddish. Microscopically, they are seen to consist of delicate connective tissue, with an epithelial covering. Numbers of round and oval cells are present, which later become spindle-shaped.

**What are the symptoms?**

If the polyps are small, they may present no symptoms; when large,

they give rise to headache, nasal obstruction, and an increased secretion. In damp weather they increase in size, owing to their hygroscopic nature, causing a greater amount of obstruction. Reflex symptoms may be present. Violent attacks of sneezing occur, and the voice assumes a nasal twang if obstruction be present in a marked degree. Their presence is said to be often a cause of asthma.

### **Give the diagnosis.**

By inspection and probing with the sound a *diagnosis* is easily made. Their color, transparency, and consistency differ from those of other growths.

### **What is the prognosis?**

As regards danger to life there is none, but the growths are, as a rule, apt to recur.

### **What is the treatment of nasal polypi?**

*Treatment* consists in their removal. Several methods have been recommended, but the surest and safest is the method by means of the cold snare. The snare is introduced vertically into the nose and then turned horizontally, so that the polyp falls within the loop. The snare is then elevated as far as possible to the pedicle, and then tightly drawn, and the polyp is thus removed. Bleeding may be slight or excessive, and is easily stilled. By this method a number of polyps can be removed in one sitting.

The after-treatment consists in the cauterization of the base by means of the galvano-cautery.

### **Give a brief description of fibrous polypi.**

Fibrous polypi are not of such frequent occurrence as the mucous, and are usually found in the post-nasal cavity instead of the anterior. Pathologically, their covering is the same as that of the mucous, whilst their interior is seen to consist of fibrous tissue and round cells with blood-vessels.

The *symptoms* are similar to those of the mucous polyps. In the later stages as they increase in size they absorb bone and other tissues. Expansion of the nasal bones ensues, and the nose becomes deformed. This deformity is known as frog-face. If not removed, they are apt to degenerate into sarcoma. By means of the rhinoscope and probe they can be readily diagnosed from the mucous polyp.

The *treatment* consists in their removal. This is effected by means of the cold snare, galvano-cautery, or electrolysis. Owing to their large size an external operation often becomes necessary.

### **What other growths are occasionally found in the nose?**

**I. Papillomata.**—These are wart-like in their structure, and are chiefly composed of connective tissue. They spring from the mucous membrane of the septum or inferior turbinated body.

When small the application of nitric acid is sufficient for their destruction; when large the cold snare should be used.

II. **Cystic**.—These resemble mucous polypi, and are found to contain a clear fluid on incision.

Removal by the snare is the best method of *treatment*.

III. **Enchondromata** are cartilaginous tumors usually springing from the septum. Arising from other portions of the nasal cavity, they act like fibromata, though they do not grow so rapidly.

#### **When the tumor is septal, what are the symptoms?**

Nasal obstruction is present in a more or less marked degree, according to the size of the tumor. When the tumor is so large that it touches the other side of the cavity, erosion takes place, sometimes followed by a discharge, pain, headache, sneezing, and impaired sense of smell. When the tumor is in other portions of the nasal cavity, it may be sarcomatous in nature and grow rapidly, causing displacement of the nasal walls, and as a result deformity.

The *treatment* of the septal enchondromata consists in their removal by means of snare or bistoury. When the enchondromata originate from bone and are situated in other portions of the cavity, where they grow rapidly, surgical measures are to be adopted.

### **MALIGNANT TUMORS OF THE NOSE.**

#### **Describe carcinoma and sarcoma of the nose.**

The *causation* of these tumors in the nose is, as in other portions of the body, still unknown. They arise chiefly from the septum, but may arise from the roof or from any other point in the nose. They vary in size here as elsewhere.

The *symptoms* they give rise to vary according to the position and size of the growths. Nasal obstruction and hemorrhage are frequent symptoms. The secretion is profuse and fœtid in character. Pain may be present in a marked degree in the infraorbital region. Disfigurement of the face may take place on account of the growth of the tumor.

The *diagnosis* is easy: the microscope leaves no doubt as to the nature of the growth.

The *prognosis* is unfavorable.

The *treatment* consists in complete removal of the diseased portions. Where this is impossible the treatment should be palliative.

### **FOREIGN BODIES IN THE NOSE.**

**What foreign bodies are sometimes found in the nose? What are the symptoms they give rise to, and what is their treatment?**

Foreign bodies, as a rule, are found only in the nose of children, and are usually beans, pebbles, cherry-stones, etc. Their presence at first

may cause but little trouble, but soon a mucous discharge makes its appearance, which soon becomes purulent, and may be tinged with blood.

*Symptoms* of obstruction and headache are present.

The *treatment*, of course, consists in the removal of the foreign body. If the case is seen early, douching by the post-nasal douche may suffice to remove it. Where this fails, the forceps or curette may be cautiously used. Where the foreign body is situated far back, Sajous' method is useful. This consists in the introduction of a piece of slender wire along the floor of the nose as far as the pharynx. The end is drawn out of the mouth by means of forceps, and a cotton tampon attached. This is drawn up behind the palate into the posterior nares, and pulled through the nasal cavity with the foreign body.

### What are rhinoliths ?

Rhinoliths are calcareous concretions resulting from the deposit of phosphate of lime from the nasal secretions around a foreign body.

They give rise to *symptoms* similar to those caused by a foreign body.

The *treatment* consists in their removal by means of forceps, curette, or the method of Sajous as above described.

## EPISTAXIS.

### Give the etiology.

Epistaxis may be caused by a blow or fall on the nose, picking the nose with the finger-nail, the presence of foreign bodies, and the use of probes or other instruments by a physician. It is a frequent symptom of tumors of the nose, whether benign or malignant, and of various forms of rhinitis, especially if ulceration be present. Certain blood-conditions predispose to it, such as anæmia, chlorosis, hæmophilia, scurvy, eruptive and relapsing fevers, etc. A common cause is active hyperæmia or stasis occurring in a large number of diseases of the heart, lungs, and blood-vessels. Diseases of the kidneys, liver, and spleen often give rise to it. It is sometimes a form of vicarious menstruation.

### What are the symptoms ?

*Prodromal symptoms* are seldom present, and are slight in their nature. There may be headache, redness of the face, and a sensation of itchiness in the nose. As a rule, the bleeding comes on without premonition, and generally from one side of the nose. Sometimes the bleeding occurs from both sides of the nose in the course of fevers. If the bleeding occurs in the posterior portion of the nose, the blood is frequently swallowed and then vomited. Quantity and quality of the blood may vary.

### Give the diagnosis.

The *diagnosis* is easy. If the blood flows from the mouth or is vomited, it must not be mistaken for hemorrhage of the lungs or stomach.

The symptoms accompanying such hemorrhages and the use of the rhinoscope should prevent such a mistake.

### **What is the prognosis ?**

The *prognosis* is, as a rule, good ; only in debilitated persons is a fatal issue to be feared.

### **What is the treatment of epistaxis ?**

In cases of moderate bleeding pressure should be applied. The application of ice and the sniffing of ice-water will often suffice. Insufflations of tannic acid and alum and the preparations of iron are useful. Where these do not suffice, plugging the nostril with cotton should be resorted to. The cotton may be dipped in a 5 per cent. solution of cocaine. The plugs should be removed in twenty-four hours, and, if necessary, fresh ones applied. Anterior packing is often insufficient where the hemorrhage is far back. Bellocq's canula should then be used. This consists of a metallic tube with a curved steel spring passing through it. This is introduced into the nose and the curved spring forced through the mouth. At the end of the spring is a knob, to which a string with a cotton tampon is attached. The instrument is drawn out and the tampon is pulled up behind the soft palate. In a large number of cases the introduction of the canula is difficult on account of its size or the presence of deviations or hypertrophies. An elastic catheter should then be used or a bougie. The tampon should not be left in longer than twenty-four hours, as it may cause pyæmia or tetanus. Where the bleeding surface can be seen the application of chromic acid or the galvano-cautery has been found useful.

## **DEVIATIONS OF THE SEPTUM.**

### **Give the etiology.**

Many suppositions have been advanced as to the *cause* of deviations of the septum. Besides traumatism, sleeping on a certain side and cleansing the nose with the same hand have been assigned as probable causes. The hypothesis most generally accepted is that a deviated septum is the result of overgrowth ; *i. e.* if the septum grows faster than the remaining portions of the skull, it is wedged in between the crista nasalis, the vomer, and lamina perpendicularis, and therefore is deviated to the side. That deviations are congenital in their nature is not believed, as the septum is usually straight until after the seventh year of life.

### **What are the symptoms ?**

If the deviation be of moderate extent, there may be no signs, except perhaps a slight deviation of the tip of the nose from the middle line. Where the deviation is considerable the whole nose may be deflected to one side. By examination with the rhinoscope the slightest deviation

can of course be detected. Where the deviation is marked, all the signs of obstruction to nasal breathing are present, such as changed voice, impaired taste, smell, and hearing, with headache.

### What is the diagnosis?

The *diagnosis* is easy. By aid of the rhinoscope the deviation can be easily seen, presenting on one side a convexity, on the other a concavity.

### Give the treatment of deviations of the septum.


When the deviation is slight Michels has recommended pressure on the convex portion of the deviation with the finger 50 to 100 times daily. Adams recommends fracturing the septum, and supporting it in position by means of intranasal splints or bougies. Partial resection of the septum has been recommended by Hartman and Petersen. In this operation the patient is placed under narcosis, an incision made in the mucous membrane, and the same pushed aside. The portion projecting is then resected by bone scissors, and the mucous membrane pushed back over the opening. A rubber tube is then introduced for the purpose of retaining the septum in place. Many operations have been devised and recommended.

## NASAL EXOSTOSES.

### What are exostoses?

Exostoses are bony growths which project usually from the septum. If large, they can give rise to troublesome symptoms, such as pain, due

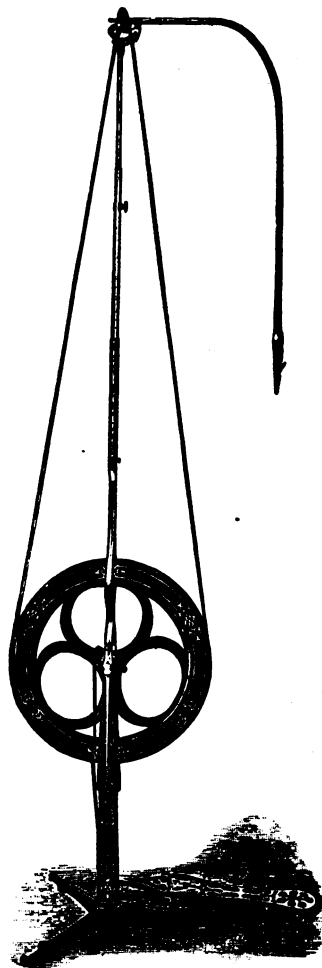
FIG. 85.



Electro-motor.



FIG. 86.




Dental Engine.

FIG. 87.



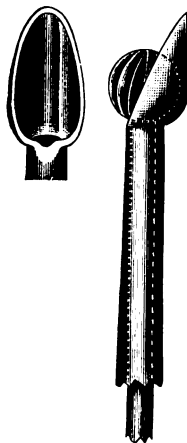
Drills for Dental Engine.

FIG. 88.



Burrs for Dental Engine.

FIG. 89.



Burr with Shield.

to pressure, and which shows itself in the course of the fifth pair of nerves. If the exostoses are small, they seldom cause any inconvenience. On rhinoscopic examination their presence is easily made out, and by means of the probe their hardness detected. When they cause inconvenience, they are best removed. This can be effected by means of the saw or the electro-motor dental engine. (See Figs. 85, 86, 87, 88, and 89.)

## HÆMATOMA OF THE SEPTUM.

**Describe hæmatoma of the septum.**

Hæmatoma of the septum is usually the result of injury, and consists in an extravasation of blood between the mucous membrane and the framework of the septum. When small it generally disappears of itself; when large it should be aspirated.

**Describe abscess of the septum.**

Abscess of the septum may be the result of hæmatoma or traumatism. It may occur as a result of syphilis preceding perforation. An early incision should be made and the pus evacuated.

## ANOSMIA AND PAROSMIA.

**What is anosmia.**

Anosmia is the loss of the sense of smell, and may be present as a symptom of various affections of the nose. Lesions of the olfactory bulb, tract, and of other portions of the brain may cause anosmia. The use of tobacco, snuff, and inhalations of tobacco-smoke may give rise to it.

The *treatment* consists in the administration of tonics, such as strychnine, arsenic, etc. Electricity should be used, the negative pole being placed at the root of the nose and the positive at the occiput.

Sajous recommends the insufflation of  $\frac{1}{40}$  gr. strychnine thoroughly triturated with 2 grains of sugar.

**What is parosmia ?**

Parosmia is a perverted sensation of smell, and is associated with lead-poisoning, locomotor ataxia, and epilepsy.

# INDEX.

---

## A.

- Abscess of brain, 156
- Accommodation, 103, 104
- Acuteness of vision, 102
- Adenoid vegetations, 171, 172
- Amaurosis, 83
- Amblyopia, 83
- Ametropia, 104
- Ankyloblepharon, 26
- Anosmia, 224
- Astigmatism, 108
  - diagnosis, 109
  - treatment, 109
  - varieties, 108
- Auricle, diseases and affections, 137, 138
  - eczema, 137
  - hæmatoma, 137
  - new growths, 137

## B.

- Blepharitis, 18
- Blepharospasm, 23

## C.

- Cataract, flap extraction, 91
  - Graefe's linear extraction, 92
  - needle operation, 91
  - operative treatment, 90-92
  - secondary, 95
  - simple extraction, 92
  - varieties, 88-90
- Catheterization, Eustachian tube, 134
- Cerumen, impacted, 138
- Chalazion, 20
- Choroid, 61
  - appearance, 66
  - coloboma, 70
  - inflammation, 67

- Choroid, rupture, 69
  - tubercle, 69
  - tumors, 70, 71
- Choroiditis, varieties, 67, 68
- Ciliary body, 60
- Color-blindness, 81
- Conjunctiva, 33
  - amyloid degeneration, 42
  - gonorrhœa, 35
  - hemorrhage, 43
  - tuberculosis, 43
- Conjunctivitis, 33
  - varieties, 33-40
- Cornea, 44
  - burns, 54
  - conical, 53
  - deposits, 52
  - diseases, 44-54
  - examination, 44, 45
  - foreign bodies, 54
  - leucoma, 51
  - staphyloma, 51
  - tattooing, 52
  - tumors, 53
  - ulcer, 49
  - wounds, 53
- Cyclitis, 65

## D.

- Dacryo-adenitis, 28
- Deafness, 149
- Diplocusis, 157
- Distichiasis, 24
- Distinct vision, 102
- Double images, 114

## E.

- Ear, anatomy, 127-131
- Ectropion, 25
- Emmetropia, 105

Entropion, 24  
 Epicanthus, 26  
 Epiphora, 30  
 Episcleritis, 56  
 Epistaxis, 219  
 Examination, hearing, 132  
   external auditory canal, 133  
   middle ear, introduction of air, 134  
   tuning-fork, 132  
   voice, 132  
   watch, 132  
 Exophthalmic goitre, 122  
 External auditory canal, 138  
   examination, 133  
   foreign bodies, 138  
   inflammations, 139, 140  
   ostoses, 141  
   other affections, 141  
 Eye as an optical instrument, 102-110

**F.**

Fixation, field of, 83

**G.**

Glaucoma, 85  
   varieties, 85, 86  
   treatment, 87  
   operative, 87

**H.**

Hemianopsia, 82, 83  
 Hemorrhage of the ear, 156  
 Heterophoria, 116  
   varieties, 119  
 Hordeolum, 19  
 Hypermetropia, 107  
 Hypopyon keratitis, 50

**I.**

Internal ear, 156  
   diseases of, 156, 157  
 Iridectomy, 51, 87  
 Iris, anatomy, 59  
   inflammations, 62-64  
 Iritis, varieties, 62-64

**K.**

Keratitis, varieties, 45-50

**L.**

Lachrymal apparatus, 26, 27  
   canals, diseases, 30  
     slitting, 31  
   gland, diseases, 28, 29  
   sac, anatomy, 28  
     diseases, 30-32  
 Laryngitis, varieties, 178-186  
 Laryngoscopy, 177, 178  
 Larynx, acute oedema, 181  
   anatomy, 173-177  
   diseases, differential diagnosis, 192,  
   193  
   foreign bodies, 191  
   inflammations, 178-186  
   neuroses, 187  
   paralysis, 187  
     varieties, 187, 188  
   syphilis, 186  
   tuberculosis, 184  
   tumors, 189  
     benign, 189  
     malignant, 190  
 Lens, 87, 88  
   dislocation, 95  
 Lenses, 98  
   classification, 101  
   curvature, 99  
   dioptric surface, 102  
   foci, 99, 100  
   images, 100  
   trial-glasses, 101  
   varieties, 99  
 Lids, anatomy, 17, 18  
   diseases, 18-26

**M.**

Mastoid inflammation, 152, 153  
   diagnosis, 153  
   operation for, 154  
 Megalopsia, 83  
 Ménière's disease, 157  
 Metamorphopsia, 83  
 Micropsia, 83  
 Middle ear, 141  
   caries, 150  
   inflammations, 142  
   varieties, 142, 143, 146-149  
   necrosis, 151  
   polypi, 151  
   treatment, 151, 152  
 Muscular apparatus, eye, 113-120

Myopia, 105  
varieties, 105, 106

### N.

Nasal catarrh, purulent, 204  
fossæ, 196-198  
Near-point, 103  
Nose, anatomy, 195  
foreign bodies, 218  
inflammations, 202-212  
lupus, 215  
polypi, 215-217  
scrofula, 214  
syphilis, 212  
tuberculosis, 214  
tumors, 215  
benign, 215-218  
malignant, 218

### O.

Ocular muscles, 113  
action, 114  
Edema of the larynx, 181  
Onyx, 50  
Ophthalmia, purulent, 35  
sympathetic, 83  
symptoms, 84  
treatment, 84  
Ophthalmometer, 112  
Ophthalmoplegia, 121  
Ophthalmoscope, 110  
employment of, 110, 111  
Optic nerve, 76  
diseases, 76  
atrophy, 78  
hemorrhage, 78  
neuritis, 76-78  
principles, 96-102  
Optical axis, 102  
Orbit, contents, 121  
cellulitis, 121  
diseases, 121, 122  
tumors, 122  
Otitic meningitis, 155  
Otitis media, varieties, 142-149

### P.

Palate, anatomy, 159, 160  
Parosmia, 224  
Perforation, membrana tympani, 147,  
149

Pharyngeal tonsil, hypertrophy, 171,  
172  
Pharyngitis, varieties, 160-163  
Pharynx, anatomy, 159  
foreign bodies, 168  
function, 159  
inflammations, 160-163  
neuroses, 167  
varieties, 167  
syphilis, 164  
tuberculosis, 165, 166  
tumors, 168  
Pinguicula, 42  
Prism, 98  
Pterygium, 41  
Ptosis, 23  
Punctum, displacement, 30  
Pupil, movements, 60

### R.

Refraction, 96, 97  
Remedies and Formulæ, eye, 123-126  
anæsthetics, 125  
antiseptics, 123  
astringents, 123  
mydriatics, 124  
myotics, 125  
ointments, 125  
powders, 125  
solids, 126  
Retina, 71  
appearance, 72  
central artery, 78  
thrombosis, 79  
embolism, 79  
congestion, 73  
opaque nerve-fibres, 73  
tumors, 75  
Retropharyngeal abscess, 163  
Rhinitis, 202  
varieties, 73-75, 202-212  
Rhinoscopy, 111, 199-202  
anterior, 199  
posterior, 200

### S.

Sclerotic, anatomy, 55, 56  
inflammations, 56  
wounds, 57  
Scotomata, 81  
Septum, deviations, 220  
hæmatoma, 224

Septum, exostoses, 221  
 tumors, 218  
 Sinuses, phlebitis, 155  
 thrombosis, 155  
 Skioscopy, 111  
 Spring catarrh, 41  
 Squint, 115  
 Strabismus, 115  
 operations for, 117-119  
 tenotomy, 117  
 open operation, 117  
 paralytic, varieties, 115, 120  
 Stye, 19  
 Symblepharon, 26  
 Synchisis scintillans, 96

**T.**

Tonsillitis, 168  
 varieties, 169  
 Tonsils, anatomy, 160  
 diseases, 168-170

Tonsils, hypertrophy, 170  
 Trichiasis, 24

**U.**

Uvula, diseases, 170

**V.**

Visual field, 79  
 determination of, 80  
 for colors, 81  
 line, 102  
 Vitreous humor, 96  
 foreign bodies, 96  
 parasites, 96

**X.**

Xanthalmasia, 21  
 Xerosis, 42

