

# Mercury Poisoning From Dental Amalgam

Jaro Pleva, Ph.D.<sup>1</sup>

This report is a critical evaluation of the use of dental amalgam with special consideration of the possibility of chronic mercury poisoning. The description of psychic and somatic symptoms associated with corrosion of amalgam might help people with similar symptoms to recognize the possible source of their problems. Medical practitioners need to recognize the characteristic manifestations of mercury poisoning and it is also my hope that this report might help dentists to a better understanding of the hazards of amalgam and combinations of metals.

The onset, development and disappearance of symptoms in relation to the dental treatments, an examination of my corroded amalgam fillings (details will be published elsewhere) and a knowledge of corrosion mechanisms, leads to the conclusion that corroding amalgam was the cause of a syndrome, typical of chronic mercury poisoning. All my observations, both as a patient and as a corrosion scientist, have reasonable explanations and can be supported by data from the scientific literature.

Analyses of saved silver amalgam fillings showed that they were badly corroded. Corrosion attacks on almost every aged amalgam filling show that assurances that

amalgam is a stable alloy can be dismissed. Statements that amalgam is not harmful are unfounded and based on short-term considerations. Galvanic coupling of gold and amalgam gives a guarantee for mercury poisoning within a relatively short time. The label "oral galvanism" is insufficient and misleading since the problem is crevice corrosion of amalgam.

For various reasons the hazards of amalgam have been disregarded for at least 50 years, resulting in insufficient information about its dangers and an unsatisfactory development of alternative filling materials. The dangers of insidious mercury intoxication from amalgam are known at least since the 1920s, but after more than half a century the problem seems more to the fore than ever. Voices have often been raised, warning that silver amalgam (and before that copper amalgam) is not harmless and describing symptoms of poisoning. In spite of this, the amalgam situation in the mouth is seldom considered in medical practice. A study of the subject and today's situation, leads one to conclude that the dental and medical care

1. Manager, Corrosion Section, Steel Research, Uddeholm AB, Pb 703, S-68301 Hagfors 1, Sweden

## MERCURY POISONING FROM DENTAL AMALGAM

systems have serious deficiencies in knowledge of important border sciences like corrosion chemistry and toxicology.

### Dental and Medical history

From about 20 years of age (beginning of 1960s) most of my teeth, with exception of the front ones, were repaired with amalgam. In 1963 a gold bridge was placed in the left side of the lower jaw to replace two missing teeth. In 1976 one of the supporting teeth had to be treated for caries. The hole in the tooth was temporarily filled with amalgam through a hole drilled through the gold. The final treatment was delayed for a year and then the tooth was root-filled through the hole in the gold. The cavity was again filled up with amalgam. Up to this time my general problems were

migraine and feelings of stress, both increasing with time. The headache started in the late 1960s and became more severe a few years later, well before the period of worst symptoms. The migraine was most often precipitated by weather changes, especially low pressures. The feelings of stress I related to hard work and a lack of balance between office work and physical activity.

A few months after the final dental treatment I was surprised by strong, unexplainable symptoms. I woke up in the nights with intense anxiety and irregular heartbeat and each time, for a few minutes, I thought that these were the last minutes of my life. At the same time, other acute symptoms increased very much.

**Table I. Symptoms of the Amalgam Syndrome**

Irregular heartbeat, often together with anxiety  
Strong pains in the left part of the chest  
Retinal bleeding  
Dim vision, especially after exercise; slow and poor accommodation  
Inability to fix the gaze, uncontrollable eye movements. Eyes drawing to one side  
Geometric figures in the visual field, migrating in a few minutes from the periphery towards the center and  
    slowly disappearing A "film" over the eyes, dry eyes  
Arcus senilis: a grey ring around the cornea (permanent)  
Red, irritated throat; inflammation in upper airways and pleurisy a year after the dental treatment  
Difficulties in swallowing Severe amnesia; constant strain; anxiety; irritability; difficulty and even impossibility to control behavior;  
    indecision Loss of interest in life; tiredness; a feeling of being old Resistance to intellectual work; reduced capacity for work, both intellectual and physical; reduced  
    powers of comprehension, information does not come through. Increased need for sleep Vertigo  
Headache (about once a week), often migraine-like, especially induced by weather changes and by prolonged sleep in the mornings Facial paralysis, right side and partly permanent. Damage to balance and hearing A painful pull at the lower jaw towards the collar bone Increased salivation, sour-metallic taste Bleeding gums at toothbrushing Joint pains, especially increasing 1981-2 Pains in the lower back Weakness of muscles, slow muscle action Pressure, pains, "needles" in the liver region Asthmatic breathing troubles, a feeling of not being able to breathe, "cracking" in the lower part of the  
    pleural sac, forcing to cough Gastrointestinal irritation  
"Needles" at lymph nodes under arms and in groin Eczema

A state of indescribable tiredness, stress and anxiety was constantly present. To perform simple tasks, to join discussions, to think, talk and to be social required considerable effort. During visits to doctors I mainly complained about my irregular heart. Since all tests were in general normal (a slightly elevated cholesterol level), the result was an entry in the records that the patient imagines his troubles. To several doctors I pointed out that there was an amalgam filling in the gold bridge, a filling which after a few months had become black and rough which indicated corrosion and dissolution of the amalgam. No doctor was interested in this fact.

Because of eye troubles I visited an eye specialist. He found bleedings in the retina and high blood pressure and sent me back to a general practitioner with the same results as before. Pains in the chest forced me to doctors again. ECG during rest and exercise showed normal heart condition. The gastrointestinal system was x-rayed and examined for a whole day without results. Mercury analysis of the urine and blood, performed on my urgent request, showed Hg-values below industrial limits.

The diagnosis that all this was because of stress or strained relations in the family I could not take seriously. From my previous life I was used to more stress, both psychic and physical than during this period. Since no doctor could help me I tried to find the cause by myself. I noticed that the surface of the amalgam filling (about 4x4 mm) in the gold bridge (surface 670 mm<sup>2</sup>) rather quickly became black and rugged. As a corrosion specialist I was fully aware of the fact that this was a galvanic cell where the more noble gold was the cathode and the amalgam the anode. This meant that the anode/amalgam was dissolving and that the metals ionized as cations. Too long I ascribed this effect little significance, believing that the process certainly could not result in dangerous amounts of dissolved mercury since the university-trained dentists twice had put amalgam in direct metallic contact with gold without the slightest hesitation.

When I had been tormented for about a year and a half and help was nowhere in sight, I did what now seems self-evident: I read about mercury poisoning in a toxicology book. My symptoms agreed well with those of chronic mercury intoxication. Then I went to a dentist

and had the amalgam in contact with the gold exchanged for plastic. After about three weeks it became evident that this was a step in the right direction and that I really was mercury poisoned. The stinging sensations in the armpits and groins and the eczema disappeared first. Then many of the subjectively strongest symptoms began to diminish, but not all of them and not completely.

About three months after the exchange of the filling in the gold bridge I suffered a paralysis in the right half of my face, balance and hearing also affected. The tentative diagnosis by the first doctor was a rare, tropical disease, imported from abroad. Another doctor later diagnosed the manifestations as Herpes zoster otis. For all I know this latter diagnosis was based on the discovery of a small area of skin eruptions on the right ear. There was never pain or itching in the affected area. The facial paralysis / ear, balance troubles were considered unusually severe which is also confirmed by the fact that the damage was largely permanent.

Three years after elimination of the gold-amalgam galvanic cell (autumn 1981) many symptoms remained and some, e.g. tiredness, muscle pains and breathing troubles were increasing. A study of the literature on dental amalgams and a knowledge of metal stability and corrosion mechanisms led to the decision to have all amalgam removed. This was done in the summer of 1982. Already after the first treatments considerable improvements were noted. When the fillings opposite the gold bridge were removed, every tendency to headache or migraine disappeared. The change was so abrupt that I can see no other explanation than the removal of the fillings in these still living teeth. In writing this, headache has not reappeared except once, after a dental treatment when several fillings were drilled out and presumably some amalgam was swallowed and inhaled. Another interesting observation was the disappearance of the painful strain from the lower jaw towards the collar-bone when two amalgam fillings in the lower jaw were removed.

When all fillings had been removed, all symptoms except the facial paralysis and arcus senilis rather quickly diminished in about three months. Subjectively the mental

abilities and memory seemed to recover more slowly than the somatic functions. However, mental functions are more difficult to quantify than symptoms of a more physical character, for example irregular heart and difficulties in breathing.

Some symptoms I had thought to have other causes than amalgam also disappeared, especially back ache, which I related to office work and my height (190 cm). Also the pains below the ribs which were thought to be remnants of a hepatitis 20 years earlier, disappeared. In December 1982 I also found that small vesicles and exfoliation of the epidermis on the sole of one foot and on the insides of my hands completely disappeared.

About five months after the last amalgam filling had been removed some relatively strong symptoms returned for a period of one to two weeks. These were mainly heart irregularities together with anxiety attacks and strong metallic taste in the mouth. After this period I had a feeling of even better well-being than before.

The improvements in my health could not be related to any factor in my surroundings: work, home, personal relations or diet since these remained unchanged. The disappearance of the symptoms clearly falls into the period of amalgam removal and afterwards. Finally I want to stress the amazing improvement in well-being, only three months after the final dental treatment. In spite of still improving, I have regained a feeling of peace and calmness, of being able to appreciate smells, details and gradations in my surroundings, something I must go back 10-15 years to find. I no longer accept that a 40 year old person must have some age-related symptoms: tiredness, headache or pains in some places. According to my opinion, a prerequisite for health is that corroding alloys, releasing highly toxic heavy metals, are removed from the oral cavity.

### **Corrosion of Silver Amalgam**

Some pieces of amalgam fillings, removed in 1982, have been saved and analyzed for corrosion attacks and composition with a JEOL scanning electron microscope with EDAX (Energy Dispersive Analysis with X-rays) equipment. The first apparent features, visible with the naked eye, both on these and other fillings, were that their surfaces towards the tooth cavities, were largely black. Fig. 1 shows

an example of corrosion at the margin of a filling (five years old). The surfaces were clearly corroded, most severely near the margins towards the outer electrolyte (saliva), a feature which is characteristic for crevice cell corrosion.

A selective dissolution of the least corrosion resistant phase in the metallographically complex amalgam system has been observed many times and has been accepted as one of the most common causes for corrosion of silver amalgam (Jorgensen, 1965; Guthrow et al., 1967; Sarkar et al., 1975). Corrosion of this phase releases metallic mercury which can either ionize, evaporate or partly react with the other phases to form new corrodible phase and the attack can continue (Espevik, 1977). The filling becomes porous which enhances corrosion and causes the margins to crack (Fig. 1, Jorgensen, 1975). Severe corrosion could be seen, not only between filling and tooth, but also on the free surface towards the cheek.

Surfaces and the inner of fillings were analyzed with the EDAX equipment. The inner of the fillings showed no considerable difference between the two silver amalgam fillings aged 5 and 20 years. The mercury content of 40 percent was lower than in freshly prepared amalgam which contained 45 percent mercury. The new amalgam contained significantly higher amounts of copper relative to the silver content, which suggests a new type of amalgam. From the chemical and electrochemical point of view, the increased copper content (14 percent) must be considered completely unsuitable since copper is easily dissolved to easily soluble compounds (Wranglen & Berendson, 1982).

Analyses of the black corrosion products in the crevices yielded interesting information. The smooth black surface of a five year old filling contained 27 percent mercury, 3 percent silver and 66 percent tin. The black, porous surfaces of a 20 year old filling were devoid of mercury and silver and contained 40-60 percent tin, 37-51 percent zinc and 4-7 percent copper. The surprisingly high zinc content might originate from an underlying zinc phosphate cement layer, if originally present. Grey areas of the same crevice still contained 5 percent mercury and 4 percent silver and tin was enriched to 80 percent. The

outer surface of the five year old filling showed about 10 percent lower mercury content near the margin compared to non-corroded surfaces. Point analyses of corroded areas showed none of the phases reported to be present in fresh amalgam (Espevik, 1977).

Corrosion is an electrochemical process which can be separated into two part reactions (Wranglen, 1967) : an anodic process which is the dissolution of the metal and a cathodic one, often reduction of oxygen and in an acidic environment the reduction of hydrogen ions to hydrogen gas. Both anodic and cathodic reactions must proceed simultaneously but can occur on separate places. The processes can be demonstrated by connecting a zinc and a platinum electrode in dilute sulphuric acid. Zinc will dissolve and hydrogen gas evolve on the platinum electrode. This is called galvanic corrosion of one of the two metals in direct metallic contact. Basically, the same process can occur on a microscopic scale between different phases of an alloy.

Another type of corrosion cell can occur, even in a pure and homogeneous metal if the conditions for anodic and cathodic reactions differ at various places of the surface. Oxygen-rich regions will be cathodic whereas regions depleted in oxygen will be anodic and corrode. In crevices, the oxygen partial pressure is low. Crevice corrosion is known to occur on metals like aluminium, stainless steel and dental amalgam (Wranglen, 1967; Espevik, 1977).

The electrolyte in a crevice corrosion cell differs from that of the surrounding solution. It is oxygen-depleted, enriched in corrosion products, i.e. metal ions and some other ions, often chlorides. pH values as low as 2 have been reported in amalgam crevices (Espevik, 1977).

An evaluation of the corrosion resistance of a metal must consider both the metal, the corrosive environment and other factors. The geometry of the model/apparatus/filling is important; crevices occur almost always and are in practice impossible to completely avoid. Amalgam things in the teeth are no exceptions (Schoonover and Souder, 1941; Jorgensen, 1965). It is a well known fact that amalgam of every known composition corrodes (Schoonover and Souder, 1941; al.,

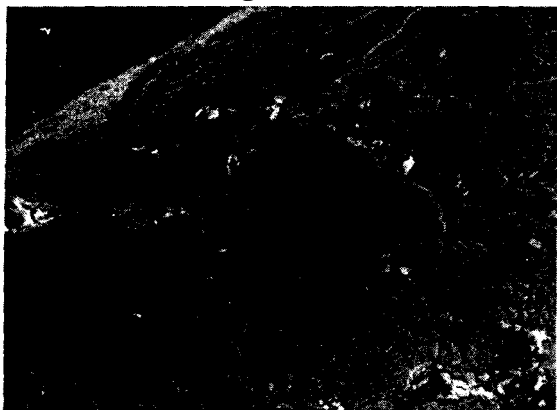
1965; Mateer and Reitz, 1970). Many people will have noticed that fillings which have to be exchanged are black along the margins. Corrosion in crevices between tooth and filling makes the latter brittle and causes the margins to crack (Jorgensen, 1965). It is important to observe that during corrosion the metal is dissolved as a positive ion, a cation, and not as a neutral atom. The latter is, however, the case when mercury evaporates.

Biological films which are sometimes ascribed high stability and properties which can prevent electron transport (Glantz and Bergman, 1982), can be removed during chewing. Since crevice corrosion of amalgam is a fact, such films can not have any real significance for this process. It is hard to imagine that their isolating properties could be better than the oxide film on an aluminium surface. Still, aluminium corrodes in crevices. In the presence of even minute amounts of nobler elements, galvanic microelements are formed and the passivisation becomes incomplete (Kaesche, 1971). The cathodic reaction is not blocked if the surface film is electrically conductive.

If there is contact between amalgam and gold or other noble metals, the anode/ amalgam will be polarized towards more positive potentials and the rate of corrosion will considerably increase (Schoonover and Souder, 1941; Fraunhofer and Staheli, 1972; Till and Wagner, 1973; Wagner and Till, 1973). My own experiences have shown that the entire surface of the filling then corrodes rapidly and that the gold then takes over the function as a cathode. The magnitude of the corrosion current in such a galvanic cell depends i.e. on the conductivity of the electrolyte/saliva, the oxygen partial pressure etc. Relevant to the role of conductivity is an interesting observation I made when the gold-amalgam galvanic element was still present. Some days I had increased pains in the chest and more troubles with my eyes. After some months of observations I could connect the symptoms with my lunch salad. There was nothing wrong with the salad itself. Months later, when I had discovered the cause of my symptoms, I could also solve the riddle of the strong effects of the salad. I like salad with dressing, much salt, vinegar and spices. Vinegar and salt will produce an electrolyte with considerably

increased conductivity and of low pH. Both factors will produce higher corrosion currents and a concomitant increased release of mercury. Rost (1976) has described a case of chronic inflammation of the mouth, nose and throat. The symptoms were rapidly increasing after acid food was ingested. The patient had both gold and amalgam in the mouth. After elimination of the amalgam the symptoms disappeared.

**Figure 1.**



Corrosion attacks on a 5 year old filling opposite the gold bridge. Pieces of the margin have broken off.

### Discussion

All symptoms described are well known from chronic mercurialism (Stock, 1926; Friberg and Vostal, 1972). They also agree well with cases similar to my own (Steffensen, 1934). The severe corrosion of my silver amalgam fillings and the disappearance of symptoms during and immediately after the removal of the fillings, proves that it really was a chronic mercury poisoning from amalgam. The typical pathological picture has been excellently described by Stock (1926), whose report on 20 years of observations clearly shows the sufferings of a chronically mercury poisoned person. I had the dubious pleasure to study the same phenomenon on myself during at least five years, both as a mercury poisoned patient and as a corrosion specialist.

Both my own experiences and the miserable situation of other persons I know of, demonstrate that it is almost impossible to discover that the cause of one's symptoms is poisoning from dental amalgam without being informed about this source of poison. It is, in this case, within us and not coming from the external environment. Most of us have more

or less amalgam in the mouth both day and night and are not aware of the fact that half of it is mercury. There are gram amounts at elevated temperature in the relatively aggressive fluids of the mouth. Compared to the prohibition of cadmium-containing glazing on chinaware, warnings for cadmium in mushrooms and lead in gasoline, the situation seems almost grotesque.

I have observed my surroundings and questioned about 150 people with symptoms similar to those I experienced myself. A causal relation between their troubles and their dental status seems to emerge. The relation is most clearly seen when there are gold restorations which can come into contact with amalgam, but also when there are many large amalgam fillings and no gold. It is remarkable that no broad investigation on these relations has been carried out already a long time ago, for instance within the scope of investigations on the etiology of civilization diseases.

Mercury is probably the most toxic metal in our environment (Stock, 1936; Fellenberg, 1977; Till et al., 1980) and all forms are toxic (Friberg and Vostal, 1972). Since the half-time for excretion from the brain for the most slowly eliminated phase is years, also small amounts of mercury during a long time can produce the same effects as high concentrations during a short time (Hanschler, 1977). This was known already in the 1930s (Stock, 1938). An insidious long-term exposure can produce damage and symptoms after decades and the cause will be very difficult to establish (Fellenberg, 1977). Additional sources of poison will also be important. It is possible that insidious heavy-metal poisoning (mercury, cadmium, lead) can be a factor in the increasing frequency of civilization diseases (Fellenberg, 1977). It has recently been shown that mercury, in the same amounts as those released from amalgam (estimated), can produce parodontitis in germ-free animals (Till, 1978).

Materials, as hazardous as mercury, should not be put into the human body unless the last suspicion that it corrodes and gives symptoms of poisoning, has been eliminated. It is remarkable that the situation is the opposite; amalgam poisoned persons have to

discover themselves and prove that they really are amalgam poisoned. It is a long way even to the suspicion that amalgam can be the source of one's symptoms. Even if one finds out, there is too often a complete lack of understanding from doctors and the patient will be viewed as a psychiatric case or at best as stressed. I was lucky thanks to my knowledge of corrosion. Paradoxically the gold-amalgam galvanic cell solved my problems since it precipitated serious symptoms which I was very anxious to get rid of. It is certainly much more difficult to classify less intense or more diffuse effects like psychic disturbances, feelings of stress, loss of memory, joint pains, anxiety or headache as manifestations of chronic mercury intoxication (Ross, 1977). A diagnosis based on analyses of urinary mercury is unreliable because of limited excretion (Berlin, 1976). Mercury concentrations in urine, blood or saliva do not tell us about the concentrations in the tissues (Friberg and Vostal, 1972).

Investigations have shown that mercury from amalgam can be taken up by the organism in three different ways: 1. Inhalation of mercury vapor and absorption in the lungs. 2. Oxidation of mercury and gastrointestinal absorption. 3. Absorption of mercuric ions diffusing through the teeth.

Both old and recent studies have shown considerable amounts of mercury in respired air during the filling process (Frykholm, 1957) and from people with amalgam fillings (Stock, 1936; Svare et al., 1981). Fifteen times higher mercury levels in respired air was recorded for amalgam carriers after chewing, compared to a group without amalgam. The mercury level in exhaled air was proportional to the number of fillings and reached levels of 87 micrograms/m<sup>3</sup> air after chewing (Svare et al., 1981). The industrial maximum permissible level for 8 h, 5 days a week exposure is 50 micrograms/m<sup>3</sup> in USA and Sweden (and will be lowered to 25). Mercury vapor is effectively absorbed in the lungs (Hirsch et al., 1976). Vapor exposure can be expected to increase if the mechanism of corrosion is a selective dissolution of tin and silver from amalgam (Wranglen and Berendson, 1982). Corrosion will lead to an enrichment of mercury in the surface layer, an increase in partial pressure and a subsequent higher level

in the vapor phase.

Mercuric chloride can be enriched in crevices and form soluble chloride complexes (Wranglen and Berendson, 1982). All easily soluble mercury compounds dissociate easily into mercuric ions in the intestine. The reaction will lead to absorption through mucous tissues. Released and ionized mercury can be taken up by tissues and nerves beneath fillings and in root canals (Frykholm, 1955; Till and Maly, 1978). The severe symptoms elicited by amalgam fillings without underlying isolation, reported by Rost (1976) indicate that this route can be of great importance. Current animal experiments (M. Hanson, personal communication) show that mercury is taken up by nerve endings and is transported towards the central nervous system in the same way as lead (Baruah, 1981). My own experiences give support to the importance of this route and are difficult to explain otherwise. Every tendency to headache disappeared from the day the fillings in still living teeth in the upper jaw were removed. Similarly, when the amalgam fillings in the right part of the lower jaw were removed, the painful strain after the facial paralysis, present four years, disappeared. It seems close at hand to suspect a combination of the general poisoning and the mercury source in the two teeth in the lower jaw as primary causes of the nerve inflammation, resulting in the face paralysis on the same side.

Measurements on extracted teeth have shown that mercury migrates from amalgam fillings to root and jaw bone and can be enriched there. When there has been contact with gold, the level can reach more than 1200 ppm (parts/million, micrograms/gram tissue) (Till and Maly, 1978). Such concentrations must be considered extremely toxic. The level of enrichment is dependent on the age of the filling, the presence of galvanic elements and bacterial conditions (Till and Maly, 1978). It is known that there are bacteria which can exist in the presence of mercury and also reduce it to gas (Schottel et al., 1974). Mercury is released from amalgam in the mouth in considerable amounts through various mechanisms. These can be enhanced by mechanical, thermal, electrolytic and bacterial factors (Wagner and Till, 1973; Wagner and Till, 1974; Till, 1977; Wranglen and Berendson, 1982).

## MERCURY POISONING FROM DENTAL AMALGAM

Even if amalgam released mercury in amounts not measurable with today's instruments, but the body reacted to these amounts, the real effects must be considered and not presumptions and figures based on inadequate methods of measurement. However, literature on the hazards of silver amalgam and the special dangers of galvanic elements amalgam-gold can be found already from the 1920s. Among others, Prof. Stock (Stock, 1926; 1936; 1938) has in detail and very competently discussed the problem, both as a chemist and as a poisoned patient. Gasser (1976) has described a number of cases with symptoms similar to mine. These all disappeared when the fillings were removed. Gasser (1976) also examined the surfaces of old fillings (age unknown), attacked by crevice corrosion. The depth of corrosion was 50-90 micrometers which was estimated to have released 240-560 milligrams during several years in a mouth with many fillings. The corroded marginal areas were depleted in mercury. This agrees with the present EDAX analysis of the black surfaces. An increased silver content, observed by Gasser (1976) could not be seen in the present investigation. On the contrary, the silver content was in all instances considerably lower than in non-corroded areas.

It must also be pointed out that people with other metal combinations than with amalgam as one component, can be troubled by the currents passing between the metals. More local irritation can then occur than when mercury is released from amalgam (Wranglen and Berendson, 1982). However, currents are normally coupled to corrosion of metals and release of metal ions. For some symptoms it might be difficult to decide if they are caused by the currents or by released metal ions. The term "oral galvanism" is misleading since the main problem is corrosion and release of toxic metals.

Reports on corrosion of amalgam, published by dental institutions, often indicate a misunderstanding of possible corrosion mechanisms (Nilner, 1981; Glantz and Bergman, 1982); such questions should be handled by competent technical institutions. Sweeping, unfounded statements like "passivation of the surface of metallic dental materials is a commonly occurring phenomenon which

means that the intraoral corrosion can be so insignificant that it can practically be considered to have ceased" (Glantz and Bergman, 1982) can not be considered sufficient justification for loading the mouth with grams of mercury, often in combination with gold.

The statement that there have never been reports on systematic dissolution of silver amalgam fillings (Glantz and Bergman, 1982) has no foundation in reality. Almost any old amalgam filling, viewed through the microscope, shows attack by crevice corrosion. Disregarding the question of the stability of single restorations, it is primarily the very common and thoughtless use of combinations of metals like gold and amalgam which indicates that dentists today have little qualification to prevent poisoning of their patients. More education and interest are needed to take advantage of present knowledge.

For the same reasons, statements that there are no reasons to advise dentists against the use of amalgam and that people should not be imparted the belief that we face considerable health problems (Friberg, 1982), do not reflect the real situation and are worthless when it comes to solving existing problems.

The correct approach is not first to use amalgam and then to demand that the patient himself shall prove that amalgam caused the ensuing problems. First it must be proved that amalgam is not harmful and that it does not corrode. It is certainly not sufficient to diffusely refer to many people without troubles (the first years). Furthermore, as long as patients with symptoms of mercury poisoning are not investigated regarding the amalgam situation and their complaints a priori are dismissed, there will be no reports on the suspected role of amalgam. Despite this, the number of persons who have solved their problems themselves is increasing. Scientific methods like chemical analysis are sometimes not sufficient and have no value on their own; the practitioner can seldom form the right diagnosis without taking the patient's statements seriously.

### Conclusions

My own symptoms, the similarity with those of chronic mercury poisoning, their disappearance when the amalgam was



removed, studies of corroded amalgam fillings, case reports and data in the literature show that all statements that silver amalgam is a stable alloy which can not give symptoms of mercury poisoning, can be dismissed. Since the mercury content of old amalgam fillings in all cases were lower than in fresh ones and could approach zero in some places, corrosion must have caused dissolution and evaporation of mercury and not enrichment in the fillings as sometimes has been claimed (Fraunhofer and Staheli, 1972). Based on a knowledge of the complicated structure and corrosion properties of amalgam, the search for a stable amalgam must be considered unrealistic. Also a very limited corrosion might be unacceptable when the released metal is highly toxic.

For doctors, anxious not to harm their patients, there is today no reason to hesitate in their attitude towards amalgam. Very much indicates that too many people are exposed to great sufferings because some scientific areas have been neglected by the medical world. There are also reasons for a broad epidemiological study on the relation between civilization diseases and amalgam. As a first step the use of gold or other metals together with amalgam should be immediately stopped and existing contacts, including temporary ones, should be eliminated.

## References

- BARUAH, J.K., RASOOL, C.G., BRADLEY, W.G. and MUNSAT, T.L.: Retrograde Transport of Lead in Rat Sciatic Nerve. *Neurol.* 31, 612, 1981.
- BERLIN, M.: Mercury. In: *Handbook on the Toxicology of Metals*. Eds. L. Friberg, G.F. Nordberg and V.B. Vouk, Elsevier/North Holl. p. 503, 1979.
- ESPEVIK, S.: Dental Amalgam. *Ann. Rev. Mater. Sci.* 7, 55, 1977.
- FELLENBERG, G.: *Umweltforschung*. Springer Verl. 1977.
- FRAUNHOFER, J.A. and STAHELI, P.J.: Gold-Amalgam Galvanic Cells. *Brit. Dent. J.* 132, 357, 1972.
- FRIBERG, L. and VOSTAL, A. Eds.: *Mercury in the Environment*. CRC Press, 1972.
- FRIBERG, L.: Dept. Hyg., Karolinska Inst. Report to the Swedish Social Board Concerning Oral Galvanism, 11-04, 1982.
- FRYKHOLM, K.O. and ODEBLAD, E.: Studies on the Penetration of Mercury Through the Dental Hard Tissues Using Hg<sup>203</sup> in Silver Amalgam Fillings. *Acta Odont. Scand.* 13, 157, 1955.
- FRYKHOLM, K.O.: Mercury from Dental Amalgam; Its Toxic and Allergic Effects and some Comments on Occupational Hygiene. *Acta Odont. Scand.* 15, Suppl. 22, 1957.
- GASSER, F.: Quecksilberbelastung im Menschlichen KSrper Durch Amalgam. *Med.-Biol. Arbeits- und Forschungsgemeinsch. Dtsch. Zahn3rzt., Baden-Baden*, 1976.
- GLANTZ, P.O. and BERGMAN, M.: Depts. of Dentistry, Lund & Malm6. Report to the Swedish Social Board Concerning Oral Galvanism, 11-11, 1982.
- GUTHROW, C.E., JOHNSON, L.B. and LAWLESS, K.R.: Corrosion of Dental Amalgam and its Component Phases. *J. Dent. Res.* 46, 1372, 1967.
- HANSCHLER, D.: *Wichtige Gifte und Vergiftungen, Pharmakologie und Toxikologie*, Vol. 1. Wissenschaft. Verl. p. 572, 1977.
- HURSCH, J.B., CLARKSON, T. W., CHERIAN, M.B., VOSTAL, J. and VAN DER MALLIE, R.: Clearance of Mercury (Hg-197, Hg-203) Vapor Inhaled by Human Subjects. *Arch. Environm. Hlth.* 31, 302, 1976.
- JORGENSEN, K.D.: The Mechanism of Marginal Fracture of Amalgam Fillings. *Acta Odont. Scand.* 23, 347, 1965.
- KAESCHE, H.: *Die Korrosion der Metalle*. Springer Verl., pp. 44 and 242, 1966.
- MATEER, R.S. and REITZ, CD.: Corrosion of Amalgam Restorations. *J. Dent. Res.* 49, 399, 1970.
- NILNER, K.: Studies of Electrochemical Action in the Oral Cavity. *Swed. Dent. J. Suppl.* 9, 1981.
- ROSS, W.D., GECHMAN, A.S., SHOLITON, M.C. and PAUL, H.S.: Need for Alertness to Neuropsychiatric Manifestations of Inorganic Mercury Poisoning. *Compr. Psychiat.* 18, 595, 1977.
- ROST, A.: Amalgamschaden. *Zahnärztl. Prax.* 27, 475, 1976.
- SARKAR, N.K., MARSHALL, G.W., MOSER, J.B. and GREENER, E.H.: In Vivo and in Vitro Corrosion Products of Dental Amalgam. *J. Dent. Res.* 54, 1031, 1975.
- SCHOONOVER, I.C. and SOUDER, W.: Corrosion of Dental Alloys. *J. Am. Dent. Ass.* 28, 1278, 1941.
- SCHOTTEL, J., MANDAL, A., CLARK, D., SILVER, S. and HEDGES, R.W.: Volatilisation of Mercury and Organomercurials Determined by Inducible R-Factor Systems in Enteric Bacteria. *Nature* 251, 335, 1974.
- STEFFENSEN, K.: Om Kronisk Kvikksolvforgiftning Foraarsaget af Tandplomber (On Chronic Mercury Poisoning Caused by Dental Fillings) *Ugeskrift for Laeger* 96, 855, 1934.
- STOCK, A.: Die Defahrlichkeit des Quecksilberdampfes. *Z. Angew. Chem.* 39, 461, 1926.
- STOCK, A.: Die Chronische Quecksilber- und Amalgamvergiftung. *Arch. Gewerbepath.* 7, 388, 1936.
- STOCK, A.: Die Mikroanalytische Bestimmung des Quecksilbers und Ihre Anwendung auf Hygienische und Medizinische Fragen. *Svensk Kem. Tidskr.* 50, 242, 1938.
- SVARE, C.W., PETERSON, L.C., REINHARD, J.W., BOYERS, D.B., FRANK, C.W., GAY, D.D. and COX, R.D.: The Effect of Dental Amalgams on Mercury Levels in Expired Air. *J. Dent. Res.* 60, 1668, 1981.
- TILL, T.: Aetiologie der Infektiosen Parodontopathien? *Zahnärztl. Welt* 86, 176, 1977.

## MERCURY POISONING FROM DENTAL AMALGAM

- TILL, T.: Quecksilberabgabe aus Amalgamfüllungen und Munddysbakterie als Ursache Parodontaler Abbauerscheinungen. Zahnarztl. Welt 87, 1076, 1978.
- TILL, T. and WAGNER, G.: Untersuchungen zur Löslichkeit der Bestandteile von Amalgamfüllungen Während des Kau- und Trinkaktes. I Teil Zahnarztl. Welt 82, 945, 1973.
- TILL, T. and MALY, K.: Zum Nachweis der Lyse von Hg Aus Silber-Amalgam von Zahnfüllungen. Der Praktische Arzt 32, 1042, 1978.
- TILL, T., KLEIN, W. and KOSICS, F.: Ueber den Einfluss Akuter Quecksilber-Belastung auf den DNA-Metabolismus in Vitro. Zeitschr. Biol. Med. No. 4, 143, 1980.
- WAGNER, E.: Beitrag Zur Klärung des Korrosionsverhaltens der Silber-Zinn Amalgame. Dtsch. Zahnarztl. Z. 17, 99, 1962.
- WAGNER, G. and TILL, T.: Untersuchungen zur Löslichkeit der Bestandteile von Amalgamfüllungen Während des Kau- und Trinkaktes II Teil Zahnarztl. Welt 82, 1004, 1973.
- WAGNER, G. and TILL, T.: Untersuchungen Über den Temperatureinfluss auf Elektrochemische Vorgänge an Metallischen Zahnreparaturmaterialien. Zahnarztl. Welt 83, 980, 1974.
- WRANGLÉN, G.: Metaller Korrosion och Ytskydd. Almqvist and Wiksell Publ. Stockholm, 1967.
- WRANGLÉN, G. and BERENDSON, J.: Electrochemical Aspects of Corrosion Processes in the Oral Cavity with Special Reference to Amalgam Fillings. Publ. in the Royal Inst. of Technol. Ser. on Corrosion of Metals and Surface Protection, Stockholm, April, 1983.