

## CHAPTER 4

# MEDIUM-RANGE COMBATIVES

*In medium-range combatives, two opponents are already within touching distance. The arsenal of possible body weapons includes short punches and strikes with elbows, knees, and hands. Head butts are also effective; do not forget them during medium-range combat. A soldier uses his peripheral vision to evaluate the targets presented by the opponent and choose his target. He should be aggressive and concentrate his attack on the opponent's vital points to end the fight as soon as possible.*

### 4-1. VITAL TARGETS

The body is divided into three sections: high, middle, and low. Each section contains vital targets (Figure 4-1, pages 4-5 and 4-6). The effects of striking these targets follow:

a. **High Section.** The high section includes the head and neck; it is the most dangerous target area.

(1) **Top of the head.** The skull is weak where the frontal cranial bones join. A forceful strike causes trauma to the cranial cavity, resulting in unconsciousness and hemorrhage. A severe strike can result in death.

(2) **Forehead.** A forceful blow can cause whiplash; a severe blow can cause cerebral hemorrhage and death.

(3) **Temple.** The bones of the skull are weak at the temple, and an artery and large nerve lie close to the skin. A powerful strike can cause unconsciousness and brain concussion. If the artery is severed, the resulting massive hemorrhage compresses the brain, causing coma and or death.

(4) **Eyes.** A slight jab in the eyes causes uncontrollable watering and blurred vision. A forceful jab or poke can cause temporary blindness, or the eyes can be gouged out. Death can result if the fingers penetrate through the thin bone behind the eyes and into the brain.

(5) **Ears.** A strike to the ear with cupped hands can rupture the eardrum and may cause a brain concussion.

(6) **Nose.** Any blow can easily break the thin bones of the nose, causing extreme pain and eye watering.

(7) **Under the nose.** A blow to the nerve center, which is close to the surface under the nose, can cause great pain and watery eyes.

(8) **Jaw.** A blow to the jaw can break or dislocate it. If the facial nerve is pinched against the lower jaw, one side of the face will be paralyzed.

(9) **Chin.** A blow to the chin can cause paralysis, mild concussion, and unconsciousness. The jawbone acts as a lever that can transmit the force of a blow to the back of the brain where the cardiac and respiratory mechanisms are controlled.

(10) **Back of ears and base of skull.** A moderate blow to the back of the ears or the base of the skull can cause unconsciousness by the jarring effect on the back of the brain. However, a powerful blow can cause a concussion or brain hemorrhage and death.

(11) **Throat.** A powerful blow to the front of the throat can cause death by crushing the windpipe. A forceful blow causes extreme pain and gagging or vomiting.

(12) **Side of neck.** A sharp blow to the side of the neck causes unconsciousness by shock to the carotid artery, jugular vein, and vagus nerve. For maximum effect, the blow should be focused below and slightly in front of the ear. A less powerful blow causes involuntary muscle spasms and intense pain. The side of the neck is one of the best targets to use to drop an opponent immediately or to disable him temporarily to finish him later.

(13) **Back of neck.** A powerful blow to the back of one's neck can cause whiplash, concussion, or even a broken neck and death.

**b. Middle Section.** The middle section extends from the shoulders to the area just above the hips. Most blows to vital points in this region are not fatal but can have serious, long-term complications that range from trauma to internal organs to spinal cord injuries.

(1) **Front of shoulder muscle.** A large bundle of nerves passes in front of the shoulder joint. A forceful blow causes extreme pain and can make the whole arm ineffective if the nerves are struck just right.

(2) **Collarbone.** A blow to the collarbone can fracture it, causing intense pain and rendering the arm on the side of the fracture ineffective. The fracture can also sever the brachial nerve or subclavian artery.

(3) **Armpit.** A large nerve lies close to the skin in each armpit. A blow to this nerve causes severe pain and partial paralysis. A knife inserted into the armpit is fatal as it severs a major artery leading from the heart.

(4) **Spine.** A blow to the spinal column can sever the spinal cord, resulting in paralysis or in death.

(5) **Nipples.** A large network of nerves passes near the skin at the nipples. A blow here can cause extreme pain and hemorrhage to the many blood vessels beneath.

(6) **Heart.** A jolting blow to the heart can stun the opponent and allow time for follow-up or finishing techniques.

(7) **Solar plexus.** The solar plexus is a center for nerves that control the cardiorespiratory system. A blow to this location is painful and can take the breath from the opponent. A powerful blow causes unconsciousness by shock to the nerve center. A penetrating blow can also damage internal organs.

(8) **Diaphragm.** A blow to the lower front of the ribs can cause the diaphragm and the other muscles that control breathing to relax. This causes loss of breath and can result in unconsciousness due to respiratory failure.

(9) **Floating ribs.** A blow to the floating ribs can easily fracture them because they are not attached to the rib cage. Fractured ribs on the right side can cause internal injury to the liver; fractured ribs on either side can possibly puncture or collapse a lung.

(10) **Kidneys.** A powerful blow to the kidneys can induce shock and can possibly cause internal injury to these organs. A stab to the kidneys induces instant shock and can cause death from severe internal bleeding.

(11) **Abdomen below navel.** A powerful blow to the area below the navel and above the groin can cause shock, unconsciousness, and internal bleeding.

(12) **Biceps.** A strike to the biceps is most painful and renders the arm ineffective. The biceps is an especially good target when an opponent holds a weapon.

(13) **Forearm muscle.** The radial nerve, which controls much of the movement in the hand, passes over the forearm bone just below the elbow. A strike to the radial nerve renders the hand and arm ineffective. An opponent can be disarmed by a strike to the forearm; if the strike is powerful enough, he can be knocked unconscious.

(14) **Back of hand.** The backs of the hands are sensitive. Since the nerves pass over the bones in the hand, a strike to this area is intensely painful. The small bones on the back of the hand are easily broken and such a strike can also render the hand ineffective.

c. **Low Section.** The low section of the body includes everything from the groin area to the feet. Strikes to these areas are seldom fatal, but they can be incapacitating.

(1) **Groin.** A moderate blow to the groin can incapacitate an opponent and cause intense pain. A powerful blow can result in unconsciousness and shock.

(2) **Outside of thigh.** A large nerve passes near the surface on the outside of the thigh about four finger-widths above the knee. A powerful strike to this region can render the entire leg ineffective, causing an opponent to drop. This target is especially suitable for knee strikes and shin kicks.

(3) **Inside of thigh.** A large nerve passes over the bone about in the middle of the inner thigh. A blow to this area also incapacitates the leg and can cause the opponent to drop. Knee strikes and heel kicks are the weapons of choice for this target.

(4) **Hamstring.** A severe strike to the hamstring can cause muscle spasms and inhibit mobility. If the hamstring is cut, the leg is useless.

(5) **Knee.** Because the knee is a major supporting structure of the body, damage to this joint is especially detrimental to an opponent. The knee is easily dislocated when struck at an opposing angle to the joint's normal range of motion, especially when it is bearing the opponent's weight. The knee can be dislocated or hyperextended by kicks and strikes with the entire body.

(6) **Calf.** A powerful blow to the top of the calf causes painful muscle spasms and also inhibits mobility.

(7) **Shin.** A moderate blow to the shin produces great pain, especially a blow with a hard object. A powerful blow can possibly fracture the bone that supports most of the body weight.

(8) **Achilles tendon.** A powerful strike to the Achilles tendon on the back of the heel can cause ankle sprain and dislocation of the foot. If the tendon is torn, the opponent is incapacitated. The Achilles tendon is a good target to cut with a knife.

(9) **Ankle.** A blow to the ankle causes pain; if a forceful blow is delivered, the ankle can be sprained or broken.

(10) **Instep.** The small bones on the top of the foot are easily broken. A strike here will hinder the opponent's mobility.

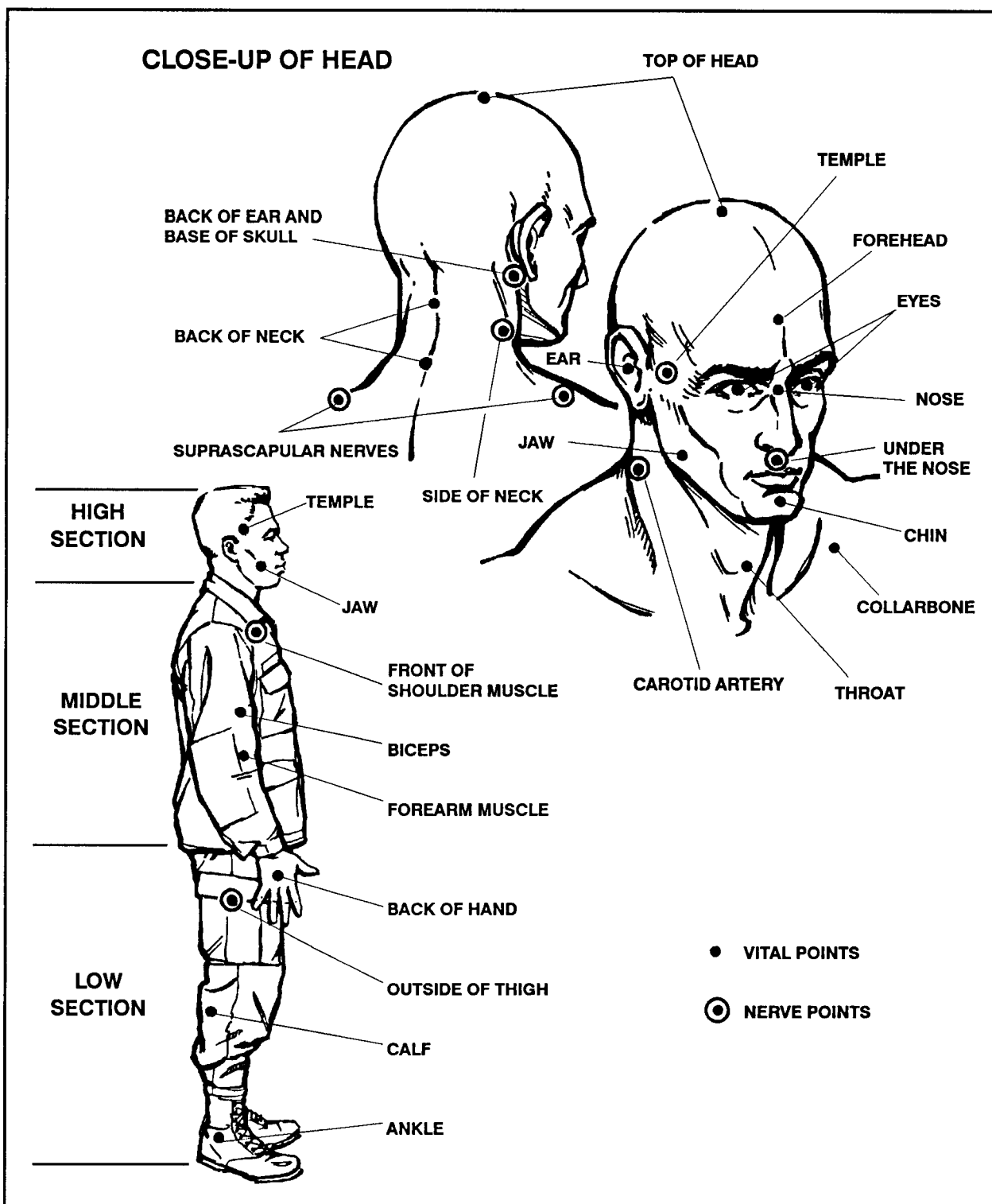


Figure 4-1. Vital targets.

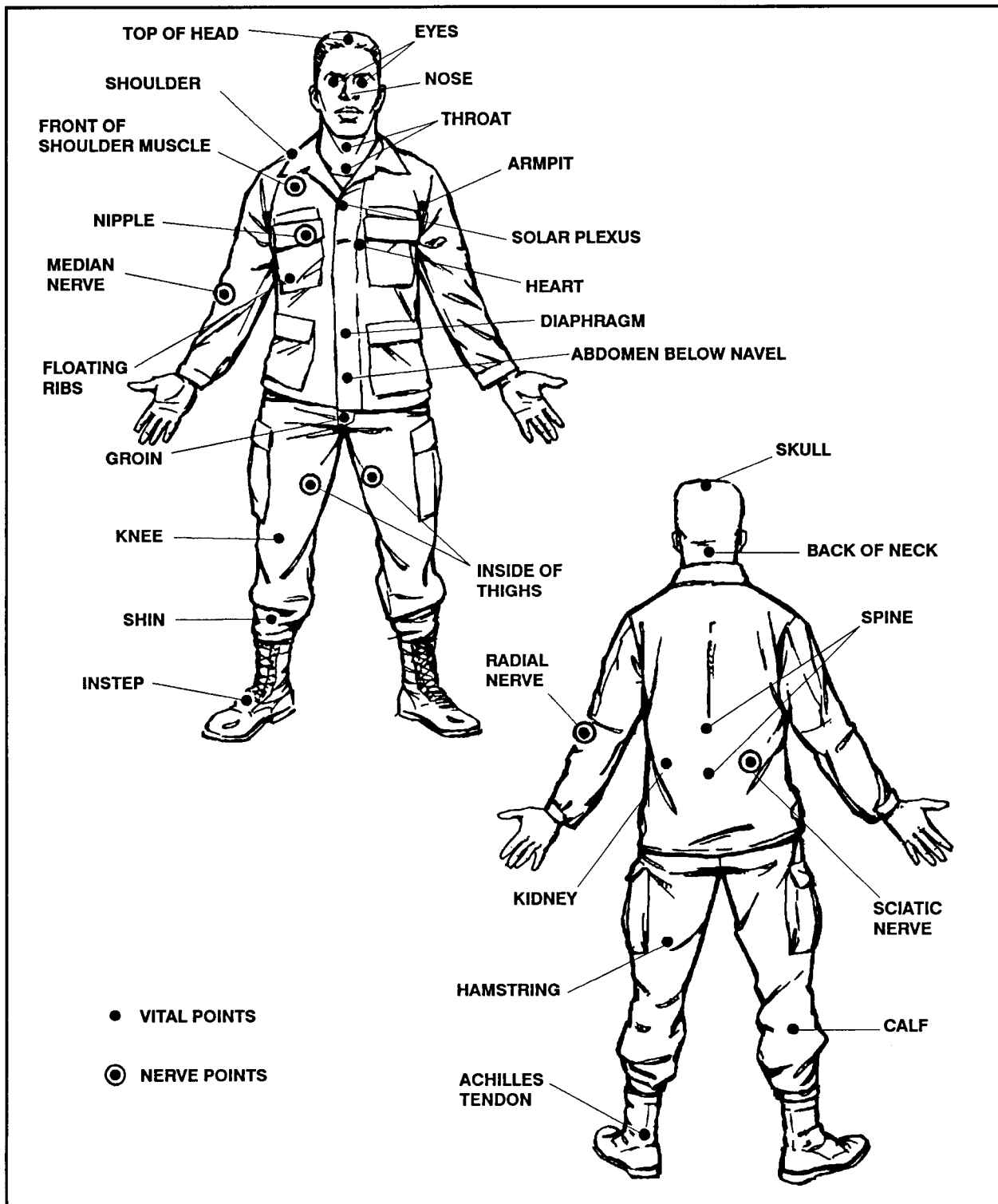


Figure 4-1. Vital targets (continued).

## 4-2. STRIKING PRINCIPLES

Effective striking with the weapons of the body to the opponent's vital points is essential for a victorious outcome in a hand-to-hand struggle. A soldier must be able to employ the principles of effective striking if he is to emerge as the survivor in a fight to the death.

a. **Attitude.** Proper mental attitude is of primary importance in the soldier's ability to strike an opponent. In hand-to-hand combat, the soldier must have the attitude that he will defeat the enemy and complete the mission, no matter what. In a fight to the death, the soldier must have the frame of mind to survive above all else; the prospect of losing cannot enter his mind. He must commit himself to hit the opponent continuously with whatever it takes to drive him to the ground or end his resistance. A memory aid is, "Thump him and dump him!"

b. **Fluid Shock Wave.** A strike should be delivered so that the target is hit and the weapon remains on the impact site for at least a tenth of a second. This imparts all of the kinetic energy of the strike into the target area, producing a fluid shock wave that travels into the affected tissue and causes maximum damage. It is imperative that all strikes to vital points and nerve motor points are delivered with this principle in mind. The memory aid is, "Hit and stick!"

c. **Target Selection.** Strikes should be targeted at the opponent's vital points and nerve motor points. The results of effective strikes to vital points are discussed in paragraph 4-1. Strikes to nerve motor points cause temporary mental stunning and muscle motor dysfunction to the affected areas of the body. Mental stunning results when the brain is momentarily disoriented by overstimulation from too much input—for example, a strike to a major nerve. The stunning completely disables an opponent for three to seven seconds and allows the soldier to finish off the opponent, gain total control of the situation, or make his escape. Sometimes, such a strike causes unconsciousness. A successful strike to a nerve motor center also renders the affected body part immovable by causing muscle spasms and dysfunction due to nerve overload. (Readily available nerve motor points are shown in Figure 4-1, pages 4-5 and 4-6.)

(1) **Jugular notch pressure point.** Located at the base of the neck just above the breastbone; pressure to this notch can distract and take away his balance. Pressure from fingers jabbed into the notch incurs intense pain that causes an the opponent to withdraw from the pressure involuntarily.

(2) **Suprascapular nerve motor point.** This nerve is located where the trapezius muscle joins the side of the neck. A strike to this point causes intense pain, temporary dysfunction of the affected arm and hand, and mental stunning for three to seven seconds. The strike should be a downward knife-hand or hammer-fist strike from behind.

(3) **Brachial plexus origin.** This nerve motor center is on the side of the neck. It is probably the most reliable place to strike someone to stun them. Any part of the hand or arm may be applied—the palm heel, back of the hand, knife hand, ridge hand, hammer fist, thumb tip, or the forearm. A proper strike to the brachial plexus origin causes—

- Intense pain.
- Complete cessation of motor activity.
- Temporary dysfunction of the affected arm.
- Mental stunning for three to seven seconds.
- Possible unconsciousness.

(4) **Brachial plexus clavicle notch pressure point.** This center is behind the collarbone in a hollow about halfway between the breastbone and the shoulder joint. The strike should be delivered with a small-impact weapon or the tip of the thumb to create high-level mental stunning and dysfunction of the affected arm.

(5) **Brachial plexus tie-in motor point.** Located on the front of the shoulder joint, a strike to this point can cause the arm to be ineffective. Multiple strikes may be necessary to ensure total dysfunction of the arm and hand.

(6) **Stellate ganglion.** The ganglion is at the top of the pectoral muscle centered above the nipple. A severe strike to this center can cause high-level stunning, respiratory dysfunction, and possible unconsciousness. A straight punch or hammer fist should be used to cause spasms in the nerves affecting the heart and respiratory systems.

(7) **Cervical vertebrae.** Located at the base of the skull, a strike to this particular vertebrae can cause unconsciousness or possibly death. The harder the strike, the more likely death will occur.

(8) **Radial nerve motor point.** This nerve motor point is on top of the forearm just below the elbow. Strikes to this point can create dysfunction of the affected arm and hand. The radial nerve should be struck with the hammer fist or the forearm bones or with an impact weapon, if available. Striking the radial nerve can be especially useful when disarming an opponent armed with a knife or other weapon.

(9) **Median nerve motor point.** This nerve motor point is on the inside of the forearm at the base of the wrist, just above the heel of the hand. Striking this center produces similar effects to striking the radial nerve, although it is not as accessible as the radial nerve.

(10) **Sciatic nerve.** A sciatic nerve is just above each buttock, but below the belt line. A substantial strike to this nerve can disable both legs and possibly cause respiratory failure. The sciatic nerve is the largest nerve in the



body besides the spinal cord. Striking it can affect the entire body, especially if an impact weapon is used.

(11) **Femoral nerve.** This nerve is in the center of the inside of the thigh; striking the femoral nerve can cause temporary motor dysfunction of the affected leg, high-intensity pain, and mental stunning for three to seven seconds. The knee is best to use to strike the femoral nerve.

(12) **Common peroneal nerve motor point.** The peroneal nerve is on the outside of the thigh about four fingers above the knee. A severe strike to this center can cause collapse of the affected leg and high-intensity pain, as well as mental stunning for three to seven seconds. This highly accessible point is an effective way to drop an opponent quickly. This point should be struck with a knee, shin kick, or impact weapon.

### 4-3. SHORT PUNCHES AND STRIKES

During medium-range combat, punches and strikes are usually short because of the close distance between fighters. Power is generated by using the entire body mass in motion behind all punches and strikes.

a. **Hands as Weapons.** A knowledge of hand-to-hand combat fighting provides the fighter another means to accomplish his mission. Hands can become deadly weapons when used by a skilled fighter.

(1) **Punch to solar plexus.** The defender uses this punch for close-in fighting when the opponent rushes or tries to grab him. The defender puts his full weight and force behind the punch and strikes his opponent in the solar plexus (Figure 4-2), knocking the breath out of his lungs. The defender can then follow-up with a knee to the groin, or he can use other disabling blows to vital areas.

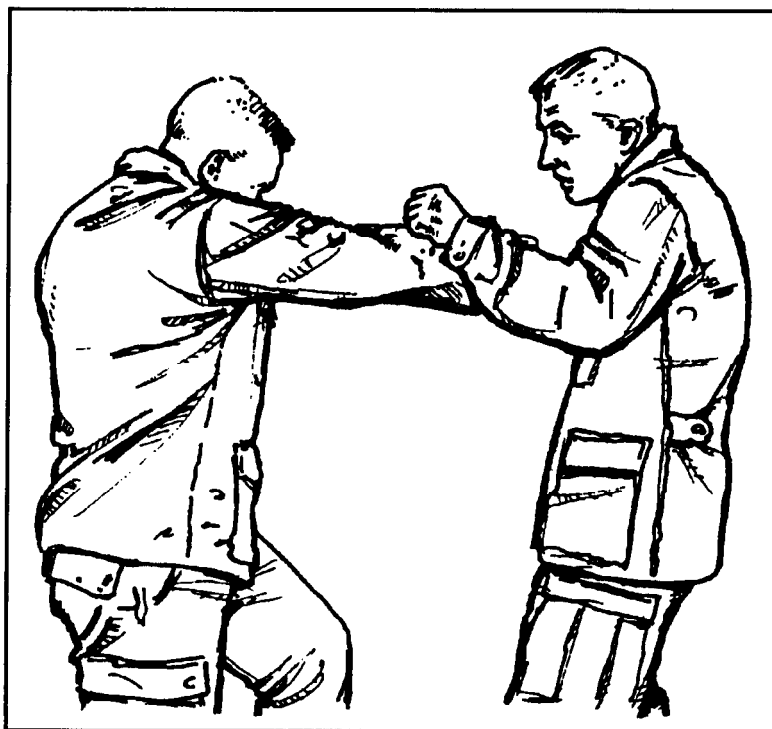


Figure 4-2. Punch to solar plexus.

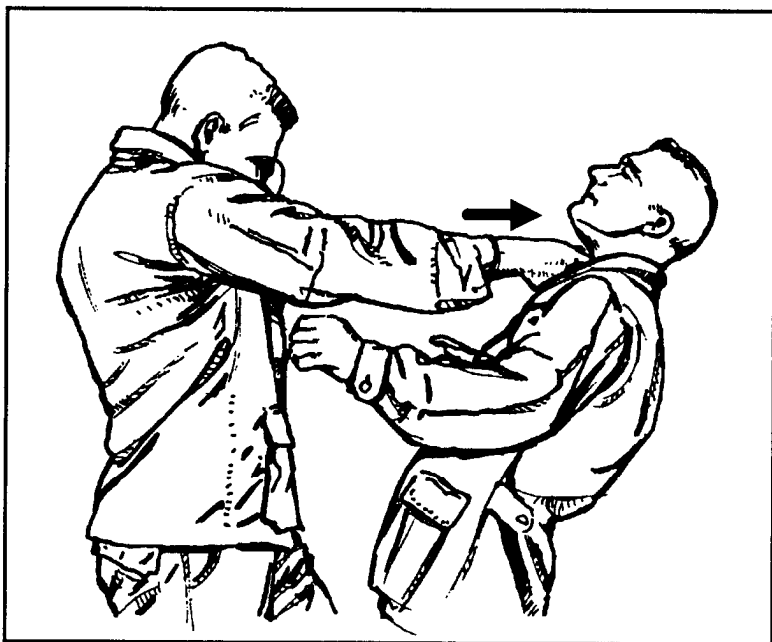


Figure 4-3. Thumb strike to throat.

**(2) Thumb strike to throat.** The defender uses the thumb strike to the throat (Figure 4-3) as an effective technique when an opponent is rushing him or trying to grab him. The defender thrusts his right arm and thumb out and strikes his opponent in the throat-larynx area while holding his left hand high for protection. He can follow up with a disabling blow to his opponent's vital areas.




Figure 4-4. Thumb strike to shoulder joint.

**(3) Thumb strike to shoulder joint.** The opponent rushes the defender and tries to grab him. The defender strikes the opponent's shoulder joint or upper pectoral muscle with his fist or thumb (Figure 4-4). This technique is painful and renders the opponent's arm numb. The defender then follows up with a disabling movement.

(4) ***Hammer-fist strike to face.*** The opponent rushes the defender. The defender counters by rotating his body in the direction of his opponent and by striking him in the temple, ear, or face (Figure 4-5). The defender follows up with kicks to the groin or hand strikes to his opponent's other vital areas.




Figure 4-5. Hammer-fist strike to face.

(5) ***Hammer-fist strike to side of neck.*** The defender catches his opponent off guard, rotates at the waist to generate power, and strikes his opponent on the side of the neck (carotid artery) (Figure 4-6) with his hand clenched into a fist. This strike can cause muscle spasms at the least and may knock his opponent unconscious.



Figure 4-6. Hammer-fist strike to side of neck.

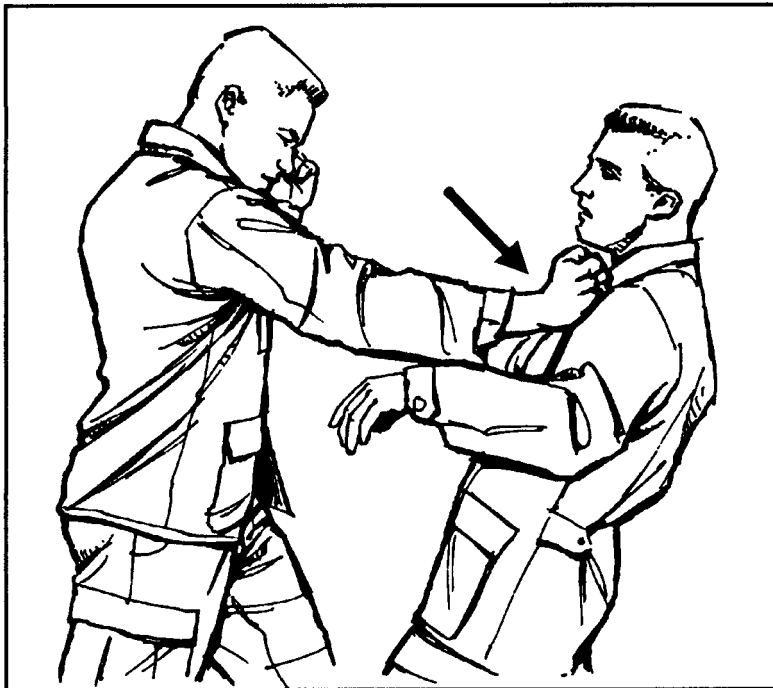

Figure 4-7. Hammer-fist to pectoral muscle.

(6) **Hammer fist to pectoral muscle.** When the opponent tries to grapple with the defender, the defender counters by forcefully striking his opponent in the pectoral muscle (Figure 4-7). This blow stuns the opponent, and the defender immediately follows up with a disabling blow to a vital area of his opponent's body.



Figure 4-8. Hook punch to solar plexus or floating ribs.

(7) **Hook punch to solar plexus or floating ribs.** The opponent tries to wrestle the defender to the ground. The defender counters with a short hook punch to his opponent's solar plexus or floating ribs (Figure 4-8). A sharply delivered blow can puncture or collapse a lung. The defender then follows up with a combination of blows to his opponent's vital areas.

(8) **Uppercut to chin.** The defender steps between his opponent's arms and strikes with an uppercut punch (Figure 4-9) to the chin or jaw. The defender then follows up with blows to his opponent's vital areas.



Figure 4-9. Uppercut to chin.

(9) **Knife-hand strike to side of neck.** The defender executes a knife-hand strike to the side of his opponent's neck (Figure 4-10) the same way as the hammer-fist strike (Figure 4-6, page 4-11) except he uses the edge of his striking hand.

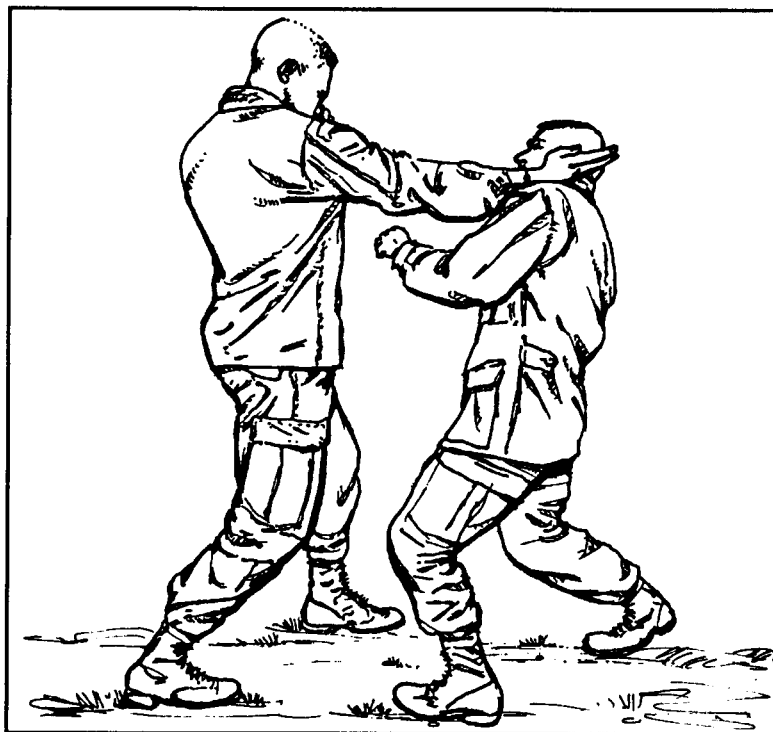

Figure 4-10. Knife-hand strike to side of neck.

(10) ***Knife-hand strike to radial nerve.*** The opponent tries to strike the defender with a punch. The defender counters by striking his opponent on the top of the forearm just below the elbow (radial nerve) (Figure 4-11) and uses a follow-up technique to disable his opponent.




Figure 4-11. Knife-hand strike to radial nerve.

(11) ***Palm-heel strike to chin.*** The opponent tries to surprise the defender by lunging at him. The defender quickly counters by striking his opponent with a palm-heel strike to the chin (Figure 4-12), using maximum force.

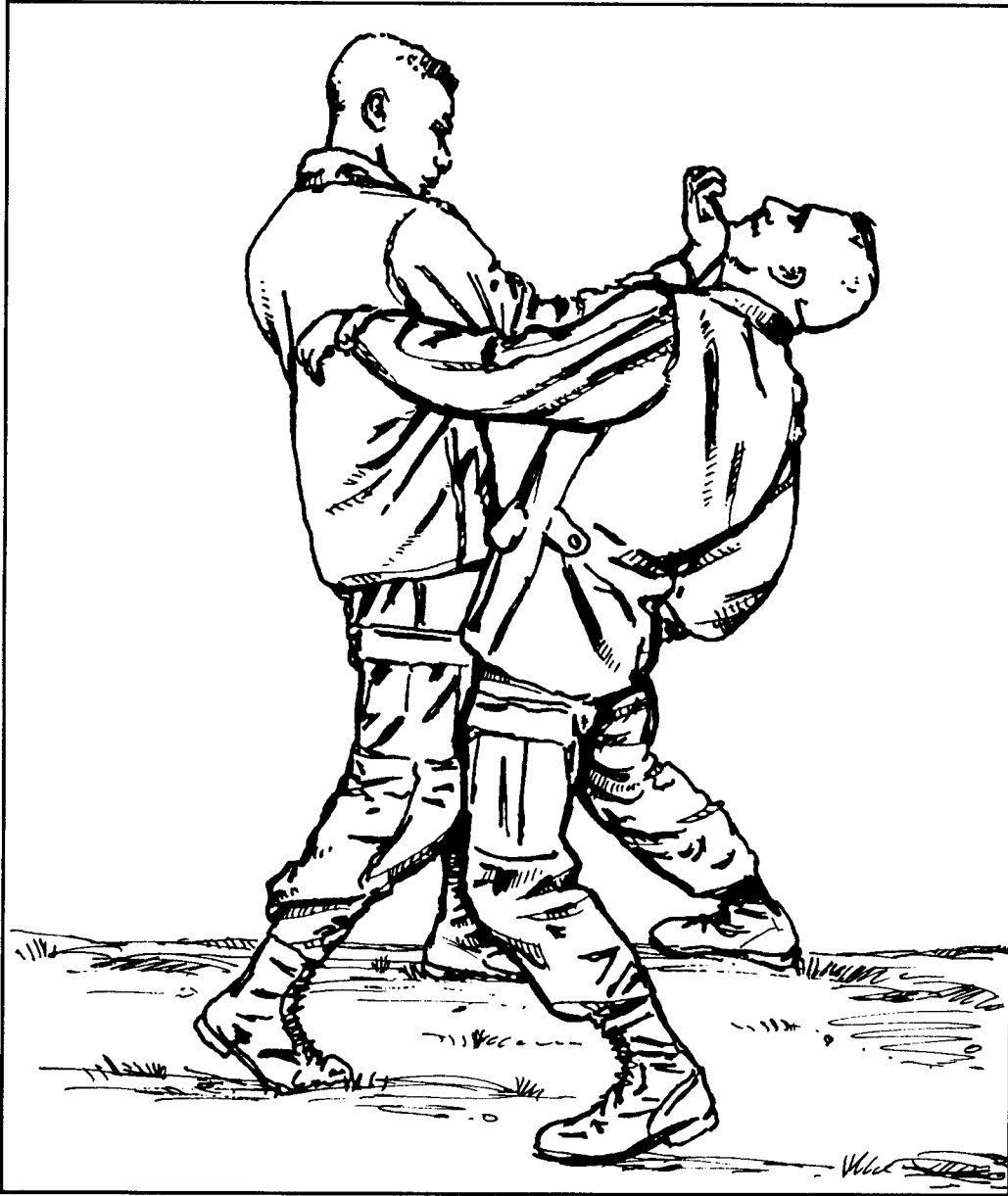


Figure 4-12. Palm-heel strike to chin.

(12) ***Palm-heel strike to solar plexus.*** The defender meets his opponent's rush by striking him with a palm-heel strike to the solar plexus (Figure 4-13). The defender then executes a follow-up technique to his opponent's vital organs.



Figure 4-13. Palm-heel strike to solar plexus.



(13) ***Palm-heel strike to kidneys.*** The defender grasps his opponent from behind by the collar and pulls him off balance. He quickly follows up with a hard palm-heel strike to the opponent's kidney (Figure 4-14). The defender can then take down his opponent with a follow-up technique to the back of his knee.



Figure 4-14. Palm-heel strike to kidneys.

b. **Elbows as Weapons.** The elbows are also formidable weapons; tremendous striking power can be generated from them. The point of the elbow should be the point of impact. The elbows are strongest when kept in front of the body and in alignment with the shoulder joint; that is, never strike with the elbow out to the side of the body.

(1) **Elbow strikes.** When properly executed, elbow strikes (Figures 4-15 through 4-21, pages 4-18 through 4-22) render an opponent ineffective. When using elbow strikes, execute them quickly, powerfully, and repetitively until the opponent is disabled.




Figure 4-15. Elbow strike to face.

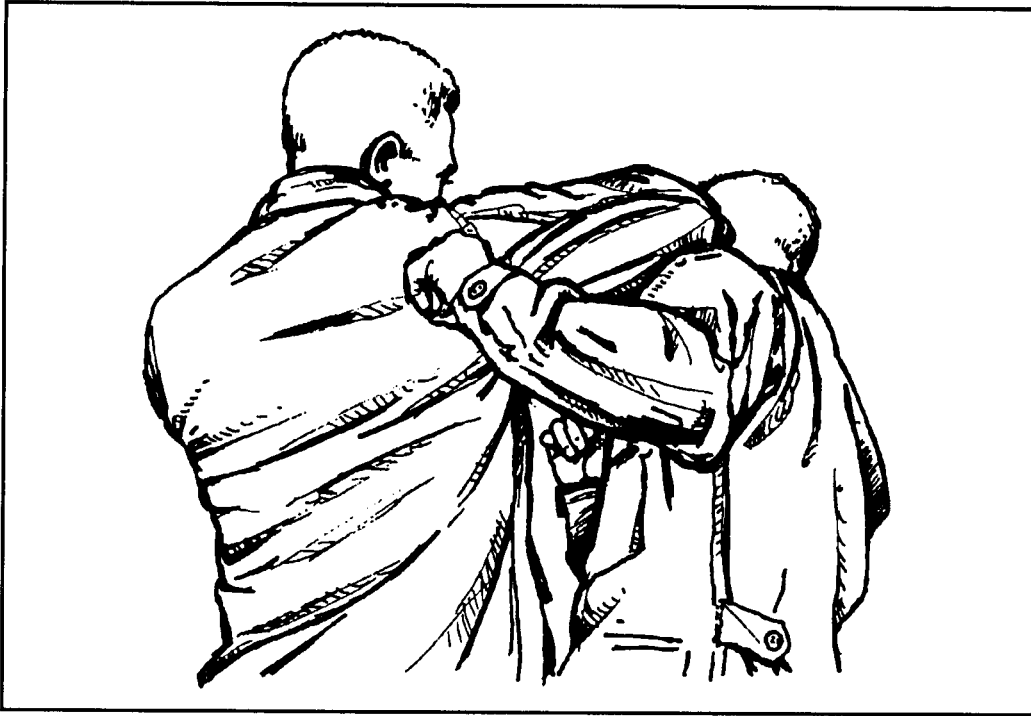

Figure 4-16. Elbow strike to temple.

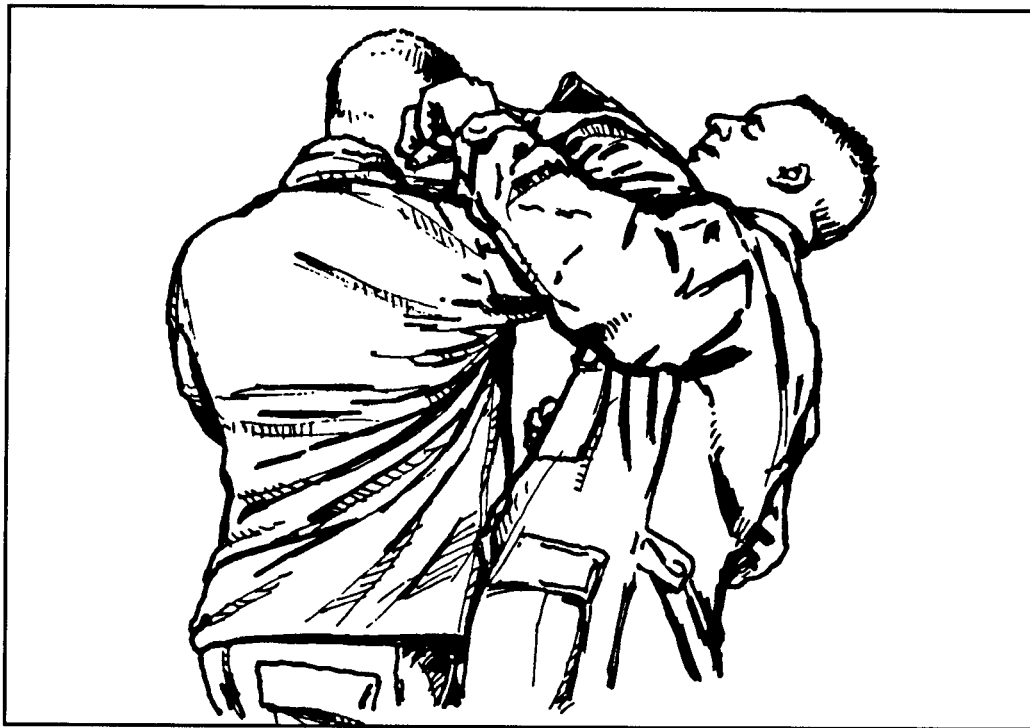


Figure 4-17. Rising elbow strike.




Figure 4-18. Elbow strike to head.




Figure 4-19. Elbow strike to solar plexus.



Figure 4-20. Elbow strike to biceps.




Figure 4-21. Elbow strike to inside of shoulder.

(2) **Repetitive elbow strikes.** The attacker on the right throws a punch (Figure 4-22, Step 1).

The defender counters with an elbow strike to the biceps (Figure 4-22, Step 2). The attacker follows with a punch from his other arm.

The defender again counters with an elbow strike to the shoulder joint (Figure 4-22, Step 3). He next strikes with an elbow from the opposite side to the throat.

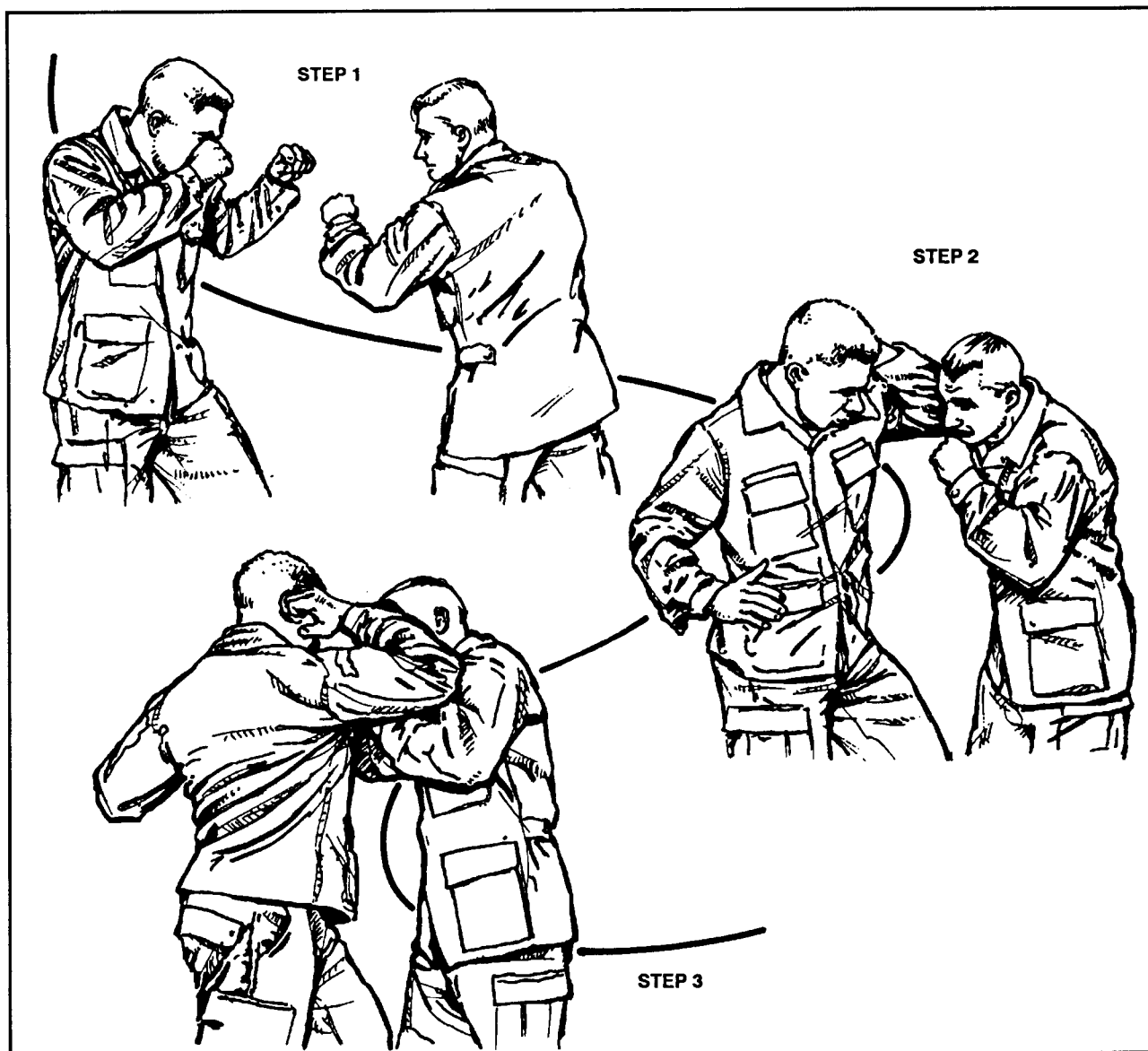


Figure 4-22. Repetitive elbow strikes.

c. **Knees as Weapons.** When the knees are used to strike opponents, they are especially potent weapons and are hard to defend or protect against. Great power is generated by thrusting the hips in with a knee strike; however, use the point of the knee as the impact surface. All knee strikes should be executed repetitively until the opponent is disabled. The following techniques are the most effective way to overpower or disable the opponent.

(1) **Front knee strike.** When an opponent tries to grapple with the defender, the defender strikes his opponent in the stomach or solar plexus with his knee (Figure 4-23). This stuns the opponent and the defender can follow up with another technique.

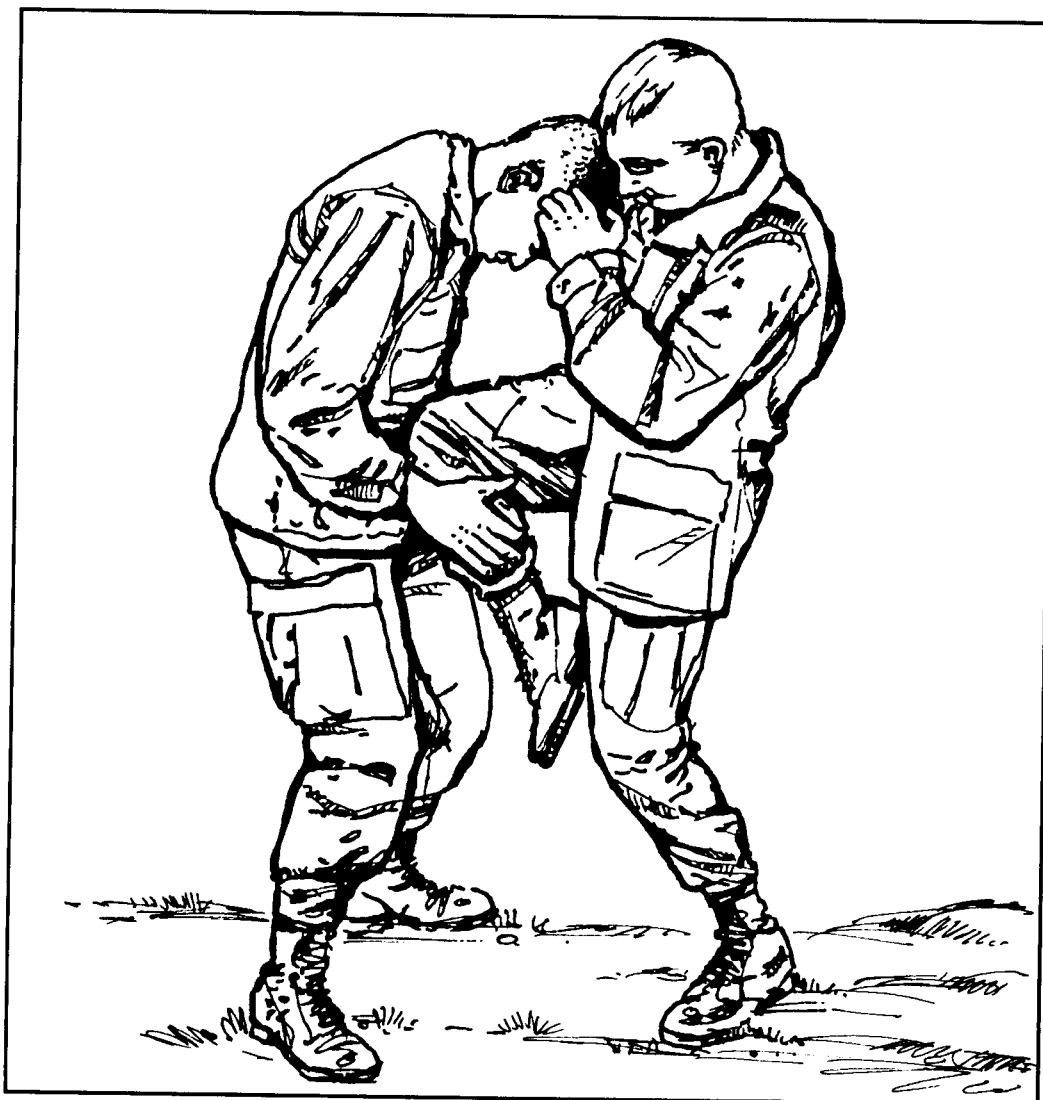

Figure 4-23. Front knee strike.

(2) ***Knee strike to outside of thigh.*** The defender delivers a knee strike to the outside of his opponent's thigh (common peroneal nerve) (Figure 4-24). This strike causes intense pain and renders the opponent's leg ineffective.




Figure 4-24. Knee to outside of thigh.



(3) *knee strike to inside of thigh.* An effective technique for close-in grappling is when the defender delivers a knee strike to the inside of his opponent's thigh (peroneal nerve) (Figure 4-25). The defender then executes a follow-up technique to a vital point.



Figure 4-25. Knee to inside of thigh.

(4) ***Knee strike to groin.*** The knee strike to the groin is effective during close-in grappling. The defender gains control by grabbing his opponent's head, hair, ears, or shoulders and strikes him in the groin with his knee (Figure 4-26).



Figure 4-26. Knee strike to groin.

(5) *Knee strike to face.* The defender controls his opponent by grabbing behind his head with both hands and forcefully pushing his head down. At the same time, the defender brings his knee up and smashes the opponent in the face (Figure 4-27). When properly executed, the knee strike to the face is a devastating technique that can cause serious injury to the opponent.

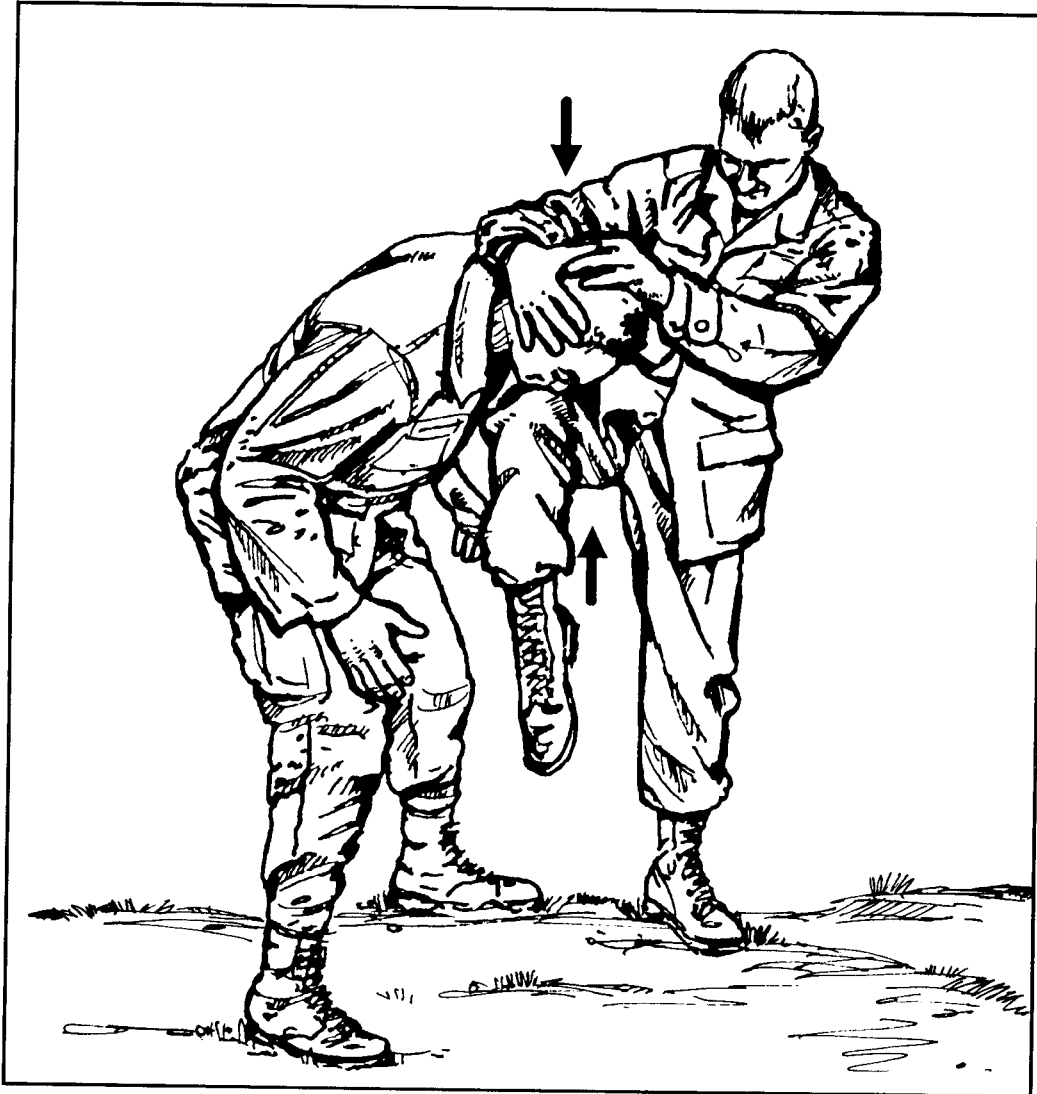


Figure 4-27. Knee strike to face.